



School of Clinical Sciences

**Infectious Keratitis;
A Molecular and Clinical Study**

by

Ahmad Muneer Otri,
MD, MS (Ophth), ICO, FRCS (Ophth)

Thesis submitted to the University of Nottingham for
the degree of Doctor of Philosophy in Ophthalmology

December 2013

بِسْمِ اللَّهِ الرَّحْمَنِ الرَّحِيمِ

"In the name of Allah, the most gracious and the most merciful".

"You are not given aught of knowledge but a little".

The Holy Quran

ABSTRACT

Infectious keratitis is a sight threatening disease which can cause permanent visual loss if not diagnosed and treated at an early stage. It can be caused by different types of microbes which are either commensals or transferred from the environment. To fight against these threats, the ocular surface (OS) has developed innate and adaptive immune mechanisms. Antimicrobial peptides (AMPs) are natural effectors on the OS with actions that range from microbicidal effects to cell signalling. Human beta defensin (hBD) 1-3 and 9, Liver expressed antimicrobial peptide (LEAP) 1 and 2, human cathelicidin (LL37), ribonuclease7 (RNase7) are the main AMPs on the OS.

In this work, the pattern of ocular AMPs gene expression in human OS cells treated with *Acanthamoeba castellanii*, *Pseudomonas aeruginosa* (*P. aeruginosa*) and *Staphylococcus aureus* (*S. aureus*) was studied and established. This was examined by quantitative real-time PCR (RT-PCR) using the Taqman assay. Among the studied AMPs, hBD3 gene showed the most significant increase in human OS cells infected with *Acanthamoeba*. LL37 demonstrated the highest level of gene expression in the samples infected with bacteria.

In a different study, the gene expression of two AMPs (hBD3 and 9) was studied in OS samples taken from patients with different types of

infectious keratitis both during and after the infection. This was compared with the expression in healthy subjects. Impression cytology (IC) was used to obtain samples of OS epithelium from recruited subjects. An optimized method for RNA extraction of IC samples was developed. Corresponding to the results of the *in vitro* study, hBD3 showed an overall up-regulation in all categories whereas hBD9 was down-regulated. These changes were most significant in patients with acute *Acanthamoeba* keratitis. The gene expression of both hBD3 and 9 showed a tendency towards returning to the levels found in healthy subjects when healing of the corneal infection was complete.

In another study carried out to examine the antimicrobial activity of hBD3 we were surprised to find that we could not replicate this. We were unable to reproduce the previously reported antimicrobial activity of hBD3 but were able to demonstrate that the antimicrobial effect could be attributed to the acidic solvent used in preparing the hBD3 protein.

The clinical significance of application of corneal densitometry as measured by the Pentacam system was assessed for the first time in patients with infectious keratitis. We demonstrated that corneal densitometry varied with levels of inflammation and was not confined to the site of infection only. It affected the whole cornea and reverted towards normal values as the inflammation settled when the infection was brought under control. We were able to demonstrate that

densitometry can be used as a measure of the corneal response to infection and inflammation and could be used to monitor response to therapy.

Finally, separate comprehensive prospective and retrospective studies of the clinical profile of severe infectious keratitis in Nottinghamshire were conducted. These two studies covered a total period of 7 years. The results of both studies were similar. Indeed, OS disease, CL wear and previous ocular surgery were found to be the most common risk factors. Positive results of corneal scraping were obtained only in about 40% of cases. *Acanthamoeba*, *S. aureus*, and *P. aeruginosa* were the most frequent causative organisms. Fortified topical antibiotics were effective in treating most cases. Therapeutic corneal grafting was found to be an effective and safe procedure in refractive infectious keratitis.

LIST OF PUBLICATIONS

ARISING FROM WORK

PRESENTED IN THIS THESIS

Mohammed I, Suleman H, **Otri AM**, Kulkarni BB, Chen P, Hopkinson A, Dua HS. (2010) Localization and gene expression of human beta-defensin 9 at the human ocular surface epithelium. *Investigative Ophthalmology & Visual Science*,51, 4677-82.

Otri AM, Mohammed I, Abedin A, Cao Z, Hopkinson A, Panjwani N, Dua HS. (2010) Antimicrobial peptides expression by ocular surface cells in response to *Acanthamoeba castellanii*: an *in vitro* study. *British Journal of Ophthalmology*, 94,1523-7 (**awarded best scientific poster prize in Nottingham Eye Symposium, 2009**).

Said DG, **Otri M**, Miri A, Kailasanathan A, Khatib T, Dua HS. (2011) The challenge of fungal keratitis. *British Journal of Ophthalmology*, 95,1623-4.

Otri AM, Fares U, Al-Aqaba MA, Dua HS. (2012) Corneal densitometry as an indicator of corneal health. *Ophthalmology*,119,501-8.

Otri AM, Mohammed I, Al-Aqaba MA, Fares U, Peng C, Hopkinson A, Dua HS. (2012) Variable expression of human beta defensins 3 and 9 at the human ocular surface in Infectious Keratitis. *Investigative Ophthalmology & Visual Science*,53,757-61.

Otri AM, Fares U, A. Al-Aqaba M, Miri A, Faraj LA, Said DG, Maharajan S, Dua HS. Profile of Sight Threatening infectious keratitis: A prospective study. (Accepted for publication in *ACTA Ophthalmologica* in April 2012 subject to minor revision)

DEDICATION

I dedicate my work:

To the Almighty “Allah” who provided me with the motivation, patience and strength to preserve through to the end of the road and to embark upon and complete this thesis.

To my beloved country “Syria” and my gracious people “The Syrians”

To my parents, for their never ending support and sense of security they have given me when I needed it most, they have waited so long for this moment to come true; I am pleased that their waiting has finally been rewarded.

To my mother in law and the soul of my father in law who gave me the incentive and reassurance

To my soul mate and adorable wife “Nour” who provided me with love, support and encouragement during this long trip.

To my lovely sons; “Naji and Tarek” who enlightened my whole life and gave me the hope with better future.

To my lovely brother and my close friend “Talal”

To my beloved sisters, their husbands and kids, who always kept me thinking that “wonderful people are still there”.

ACKNOWLEDGMENTS

I would like to thank my gracious supervisor Professor Harminster S. Dua, for his unlimited support, guidance, advice and encouragement. His never ending wisdom and knowledge always inspired me and gave me the strength to face all the difficulties. Also I would like to thank my second supervisor and (friend) Dr. Andrew Hopkinson for his un-limited kindness and co-operation.

Special thanks go to my sponsor, the University of Aleppo, Aleppo, Syria for its kindness in providing the necessary financial support for the completion of my study.

I owe my deepest gratitude to my colleagues at the Division of Ophthalmology and Visual Sciences in Nottingham. I specifically thank my close friends; Usama Fares, Saker Saker, Yamen Badr and Mouhamed Al-Aqaba who shared this long trip with me including its difficult and cheerful periods. Also, special thanks to my dear friends: Imran Mohammed, Khurram Hashmani, Ammar Miri, Dalai Said and Lana Faraj who helped me a lot and were always kind and supportive.

CONTENTS

CONTENTS

Abstract	iii
List OF PUBLICATIONS ARISING FROM WORK PRESENTED IN THIS THESIS	vi
DEDICATION	viii
ACKNOWLEDGMENTS	x
CONTENTS	xi
List of Figures	xvii
LIST OF TABLES	xix
LIST OF COMMON ABBREVIATIONS	xxi
Rationale and Aims	xxii
Chapter One	1
1 Introduction	1
<i>1.1 The Ocular Surface</i>	<i>1</i>
1.1.1 Anatomy of the ocular surface	1
1.1.2 General mechanisms of the ocular surface defense	4
1.1.3 Antimicrobial peptides	7
<i>1.2 Microbial keratitis</i>	<i>15</i>
1.2.1 Corneal morbidity in microbial keratitis.....	16
1.2.2 Types of Microbial Keratitis	17

Chapter Two	40
2 Antimicrobial peptides gene expression by ocular surface cells in response to <i>Acanthamoeba castellanii</i>: An in vitro study	40
2.1 <i>Introduction</i>	40
2.2 <i>Methods</i>	42
2.2.1 Human cell culture	42
2.2.2 Isolation and culture of <i>Acanthamoeba castellanii</i> trophozoites	43
2.2.3 <i>Acanthamoeba</i> exposure of HCLE.....	43
2.2.4 Isolation of total RNA	44
2.2.5 Complementary DNA (cDNA) synthesis	45
2.2.6 Quantitative real-time PCR.....	45
2.3 <i>Results</i>	50
2.4 <i>Discussion</i>	53
Chapter Three	59
3 Antimicrobial peptide gene expression by ocular surface cells in response to <i>Pseudomonas aeruginosa</i> and <i>Staphylococcus aureus</i>	59
3.1 <i>Introduction</i>	59
3.2 <i>Methods</i>	60
3.2.1 Cell culture	60
3.2.2 Bacterial exposure/ stimulation of HCECs.....	62
3.2.3 Isolation of total RNA and cDNA synthesis.....	63
3.2.4 Quantitative RT-PCR.....	63
3.3 <i>Results</i>	64
3.3.1 Modulation of AMPs gene expression in HCEC cells in response to challenge with <i>P. aeruginosa</i> :.....	64

3.3.2	Modulation of AMPs gene expression in HCEC cells in response to challenge with <i>S. aureus</i> :	66
3.4	<i>Discussion</i>	68
Chapter Four		76
4	Variable Gene Expression of Human Beta Defensins 3 and 9 at the Human Ocular Surface in Infectious Keratitis	76
4.1	<i>Introduction</i> :	76
4.2	<i>Methods</i>	79
4.2.1	Overview	79
4.2.2	Ethical approval.....	79
4.2.3	Impression cytology samples collection.....	79
4.2.4	Extraction of total RNA	80
4.2.5	RNA quality and quantity control.....	82
4.2.6	Complementary DNA synthesis	82
4.2.7	Quantitative real-time polymerase chain reaction (Taqman assay)	83
4.2.8	Data analysis	84
4.3	<i>Results</i>	85
4.3.1	The RNA yield using the original and the optimized methods	85
4.3.2	Disease diagnosis	88
4.3.3	Gene analysis.....	89
4.4	<i>Discussion</i>	94
Chapter Five		100
5	Does Human Beta Defensin-3 have Anti-bacterial Effect?	100
5.1	<i>Introduction</i>	100
5.2	<i>Methods</i>	101

5.3	<i>Results</i>	103
5.3.1	Testing the antibacterial effect of the HBD3 against <i>S. aureus</i>	104
5.3.2	Testing the antibacterial effect of the HBD3 against <i>E. coli</i>	107
5.4	<i>Discussion:</i>	109
Chapter Six		117
6	Corneal Densitometry as an Indicator of Corneal Health	117
6.1	<i>Introduction</i>	117
6.2	<i>Methods</i>	122
6.2.1	Normal Eyes.....	122
6.2.2	Patients with Bacterial keratitis.....	125
6.2.3	Statistical analysis	130
6.3	<i>Results</i>	131
6.3.1	Control group	131
6.3.2	Study group with infectious keratitis.....	132
6.4	<i>Discussion</i>	136
Chapter Seven		143
7	Profile of Sight Threatening Infectious Keratitis: A Prospective Study ...	143
7.1	<i>Introduction</i>	143
7.2	<i>Methods</i>	144
7.3	<i>Results</i>	146
7.3.1	Demographics	146
7.3.2	Seasonal variations	146
7.3.3	Microbiology.....	148
7.3.4	Predisposing factors:	150
7.3.5	<i>Acanthamoeba</i> Keratitis	152

7.3.6 Clinical Signs.....	152
7.3.7 Complications.....	154
7.3.8 Visual acuity change.....	155
7.3.9 Period of healing:.....	156
7.3.10 Treatment.....	157
7.4 Discussion:.....	161
Chapter Eight.....	172
8 Profile of Sight Threatening Infectious Keratitis in Nottinghamshire: A Retrospective Study.....	172
8.1 Introduction	172
8.2 Methods.....	172
8.3 Results	174
8.3.1 Demographics	174
8.3.2 Seasonal variations	174
8.3.3 Period of treatment	175
8.3.4 Microbiology.....	176
8.3.5 Predisposing factors	178
8.3.6 Signs.....	180
8.3.7 VA during and after.....	180
8.3.8 Complications.....	181
8.3.9 Correlation between Healing period and age and correlation between healing period and initial VA in bacterial and <i>Acanthamoeba</i> keratitis patients	182
8.3.10 Period of healing	183
8.3.11 Treatment.....	183
8.4 Discussion.....	187

Chapter Nine.....	194
9 Summary, general discussion and Conclusion	194
9.1 Overview:	194
9.2 Brief description.....	195
9.3 General Discussion and conclusion	200
Bibliography.....	208

LIST OF FIGURES

<i>Figure 1. Another three step view of the TaqMan probe.....</i>	<i>47</i>
<i>Figure 2 The AMPs gene expression in HCLE stimulated with Acanthamoeba castellani..</i>	<i>52</i>
<i>Figure 3. Healthy HCECs with 70% confluence under the microscope.....</i>	<i>61</i>
<i>Figure 4. AMP gene profile in HCEC challenged with Pseudomonas aerugino ..</i>	<i>65</i>
<i>Figure 5. AMP gene expression in HCECs challenged with Staphylococcus aureus</i>	<i>67</i>
<i>Figure 6. Poor samples of extracted RNA using the original method of RNA extraction.....</i>	<i>87</i>
<i>Figure 7. Good samples of extracted RNA using the optimized RNA extraction method.....</i>	<i>88</i>
<i>Figure 8. Relative gene expression of hBD3 in impression cytology samples taken from patients with Acanthamoeba keratitis, Gram negative and positive bacterial keratitis compared to healthy controls.</i>	<i>91</i>
<i>Figure 9. Relative gene expression of hBD9 in impression cytology samples taken from patients with Acanthamoeba keratitis, Gram negative and positive bacterial keratitis compared to healthy control.....</i>	<i>93</i>
<i>Figure 10. The angles of the ordinary camera, using the example of a photographic lens.....</i>	<i>119</i>
<i>Figure 11. The angles of the Scheimpflug principle, using the example of a photographic lens.....</i>	<i>120</i>
<i>Figure 12 With a normal camera, when the subject is not parallel to the image plane, only a small region of the text is in focus. Conversely, with Scheimpflug</i>	

dependent devices, the whole text will be clear even with non-parallel planes.
..... 120

Figure 13 The figure illustrates the 4 axes (45, 90, 135 and 180 degrees) and the 5 points on each axis where densitometry was performed. The inner points were 1.5 mm and the outer were 3.5 mm from the centre. 123

Figure 14. This figure shows the two different methods in measuring the density of the cornea: the densitometry at different points (A) and the densitometry of the total cross sectional areas (B). 124

Figure 15. Densitometry in patient with active infectious keratitis. s. 126

Figure 16. Densitometry in patient with healed infectious keratitis..... 128

Figure 17 Another example of Densitometry in patient with active infectious keratitis. s..... 129

Figure 18 Another example of Densitometry in patient with healed infectious keratitis.. 130

LIST OF TABLES

<i>Table 1. Thermal cycler profile used in this study. The standard profile consists of three stages (activation, hold and cycle. Data collection was performed at cycle stage).</i>	48
<i>Table 2. showing detailed information about the genes and primer codes used in our study</i>	49
<i>Table 3. Details of genes and accession numbers used in the study</i>	84
<i>Table 4. Causative organisms and number of impression cytology samples taken in each group.</i>	89
<i>Table 5. Showing the Colony forming units in serial dilutions of S. aureus bacteria tested against 40, 20, 10 and 5 µg /ml of HBD3 reconstituted in distilled water. The colony forming units were also calculated in bacterial samples treated with distilled water alone</i>	105
<i>Table 6. Showing the Colony forming units in serial dilutions of S. aureus bacteria tested against 40 µg /ml of HBD3reconstituted in 10mM of acetic acid & 4 mM of hydrochloric acid</i>	106
<i>Table 7. Showing the Colony forming units in serial dilutions of E. coli bacteria tested against 40, 20, 10 and 5 µg /ml of HBD3 reconstituted in distilled water</i>	108
<i>Table 8. Showing the Colony forming units in serial dilutions of E. coli bacteria tested against 40 µg /ml of HBD3reconstituted in 10mM of acetic acid & 4 mM of hydrochloric acid</i>	109
<i>Table 9 Densitometry values of healthy controls</i>	132
<i>Table 10 Densitometry measurements at points of infection in both the acute stage and 4-6 weeks after complete resolution.</i>	133

<i>Table 11 Densitometry measurements of total cross sectional area of infection in both the acute stage and 4-6 weeks after complete resolution.....</i>	<i>135</i>
<i>Table 12 Shows the corneal densitometry values 1. Of healthy controls and 2. At sites of infectious infiltrates and 3. At points of clear cornea furthest away from the infiltrates.</i>	<i>136</i>
<i>Table 13. Seasonal distribution of the severe infectious keratitis in Nottinghamshire.</i>	<i>147</i>
<i>Table 14. Isolated organisms by culture).....</i>	<i>149</i>
<i>Table 15. Predisposing factors of the severe corneal infections.....</i>	<i>151</i>
<i>Table 16. Clinical signs of microbial keratitis.</i>	<i>153</i>
<i>Table 17. Complication of severe microbial keratitis)</i>	<i>155</i>
<i>Table 18. Medical treatment of severe infectious keratitis).....</i>	<i>158</i>
<i>Table 19. Therapeutic interventions in refractory microbial keratitis. Therapeutic interventions in refractory microbial keratitis.....</i>	<i>160</i>
<i>Table 20. Seasonal distribution of the severe infectious keratitis in Nottinghamshire.</i>	<i>175</i>
<i>Table 21. The isolated organisms and the correlated predisposing factors ..</i>	<i>177</i>
<i>Table 22. The factors which predispose to infectious keratitis.....</i>	<i>179</i>
<i>Table 23. Complication of microbial keratitis.....</i>	<i>182</i>
<i>Table 24. Therapeutic interventions in refractory microbial keratitis)</i>	<i>186</i>

LIST OF COMMON ABBREVIATIONS

OS: Ocular surface

AMPs: Antimicrobial peptides

HBD: Human beta defensin

LEAP: Liver expressed antimicrobial peptide

LL37: Human cathelicidin

RNase: Ribonuclease

IC: Impression cytology

CL: Contact lens

BHIB: Brain-Heart Infusion Broth

TLR: Toll like receptor

RATIONALE AND AIMS

Microbial keratitis remains the most significant (important and common) cause of corneal blindness. The antimicrobial peptides (AMPs) are now recognised as an important first line of host defence against invading microorganisms which cause the corneal infection. The Division of Ophthalmology, University of Nottingham has pioneered research in this field of ocular AMPs and profiles the spectrum of expression at the ocular surface. In this study we plan to establish whether the *in vitro* profile of expression is determined by the infecting organism and whether specific profiles can be identified that represent bacterial or *Acanthamoeba* infections. The second part of the research will involve studying the AMP expression in eyes with specific microbial keratitis and data will be analysed to establish trends or profiles that may be specific for different organisms or groups of organisms. The main goal of these studies is to determine the *in vitro* and *in vivo* profile of the studied AMPs during the infection and decide whether these correlate together or not. The other aim is to use any useful information about the gene expression of the AMPs in future studies about the diagnosis and the management of the infectious keratitis.

AMPs proteins are known to have promising avenue in killing the invading bacteria in ocular surface cells. In this study, the AMPs

antibacterial activity will be confirmed and then used as a control to study the anti-amoebic killing efficacy of the AMPs in infected ocular surface cells. This will be a novel study which has never studied before.

To further study the course of the active infectious keratitis in addition the healing process, the cornea will also be studied using a novel technique. The corneal density in patients with microbial keratitis at the active stage of the disease and during the healing process will be measured using the imaging capabilities of the Scheimpflug image principle (Pentacam). This will be compared with 'normal' values of the clear corneas which will be measured in healthy subjects with no previous ocular pathology.

The profile of microbes, their virulence, infection rates and response to medication (drug sensitivity) presents an ever changing scenario which differs according to geography and time partly influenced by prescription habits prevailing amongst physicians dealing with such infections. Therefore what may be true for one part of the world may not apply to another part or even within a given country it may differ from region to region. It is well recognised that major centres dealing with a large number of infective keratitis need to establish diagnostic and therapeutic parameters that are applicable to their respective regions. Thus far these parameters have not been established for the Trent region generally and for Nottinghamshire specifically. This study

will address this issue as it will yield data on the species of infective organisms, their relative frequency, the response to the commonly used drugs and the outcomes of management.

CHAPTER ONE

1 Introduction

1.1 THE OCULAR SURFACE

The ocular surface of the human eyes has the ability to refract the light and process it through its transparent tissues. Subsequently, the formed image is transported from the retina to the brain where it is interpreted into meaningful vision (Snell and Lemp, 1998).

1.1.1 Anatomy of the ocular surface

Human ocular surface (OS) is comprised of the cornea, conjunctiva, limbus and tear film (Snell and Lemp, 1998).

1.1.1.1 The Cornea:

The cornea is a transparent avascular tissue which refracts the light, contains the intraocular pressure and provides a protective interface. It provides about 70% (40-45 diopters) of the total ocular refractive power. Apart from the pre-corneal tear film, there are five layers of the corneal tissue; these are: the epithelium, Bowman's layer, the stroma, Descemet's membrane and the endothelium (Snell and Lemp, 1998, Bron et al, 1997, Knop and Knop, 2007).

1.1.1.1.1 Epithelium

The corneal epithelium is composed of stratified and non-keratinized squamous cells. It is about 50-90 μm thick and consists of five to six layers of nucleated cells (Bron et al, 1997, Snell and Lemp, 1998). At the deepest layer the basal cells form the germinative layer of the epithelium. These basal cells arise from the the corneal epithelial stem cells reside at the limbus (Bron et al, 1997). It is believed that the epithelium is replaced approximately weekly by the division of basal epithelial cells (Hanna et al., 1961). The horizontal migration from the limbus towards the centre of the cornea may take as long as a year (Kaye, 1980).

1.1.1.1.2 Basal lamina

The basal lamina is secreted by the deep basal cells and it is made up of an filamentary materials besides collagen and glycoprotein constituents (Bron et al, 1997, Snell and Lemp, 1998).

1.1.1.1.3 Bowman's layer

Bowman's layer is acellular region of the anterior stroma of about 8-12 μm thick. It is very resistant because of the compact arrangement of the collagen fibrils and perforated by un-myelinated epithelial nerves in many places. Damaging of this layer can lead to fibrous tissue formation as it is incapable of regeneration (Snell and Lemp, 1998, Knop and Knop, 2007, Bron et al, 1997).

1.1.1.1.4 Stroma (substantia propria)

The stroma, which is about 500 µm thick, consists of uniformly arranged laminated sheets of collagen bundles (mainly type I collagen). These collagenous lamellae are produced by keratocytes and lie in proteoglycan ground substance. The lamellae are arranged in layers parallel with each other and with the corneal surface. This unique arrangement is responsible for the corneal transparency (Bron et al, 1997). Keratocytes are generally inert cells but with the aid of cytokines and other growth factors they can respond to injury turning into modified repair cells. Other cells like: Lymphocytes, macrophages, and polymorphnuclear leucocytes are also found in the corneal stroma (West-Mays and Dwivedi, 2006, Knop and Knop, 2007).

1.1.1.1.5 Descemet's membrane

Descemet's membrane is located in direct attachment with the corneal endothelium with collagen type IV forming its main component (Bron et al, 1997).

1.1.1.1.6 Endothelium

The endothelium is composed of single layer of hexagonal, cuboidal cells. Corneal transparency is preserved mainly by the endothelium which maintain relative deturgescence, and actively regulates the movements of glucose, amino acids, and oxygen to other corneal layers (Bron et al, 1997, Snell and Lemp, 1998).

1.1.1.2 The Limbus

It is a transitional zone between the cornea and sclera where the stem cell niches of the corneal epithelium are thought to be located. The epithelium of this area is bridging the conjunctival and corneal epithelium (Snell and Lemp, 1998).

1.1.1.3 The Conjunctiva

It is a translucent mucous membrane divided into palpebral, fornical and bulbar conjunctiva. It has an epithelium and sub-mucosal lamina propria besides rich vascular component. It plays a major role in OS protection and lubrication by containing abundant goblet cells, melanocytes and immune cells (Snell and Lemp, 1998, Knop and Knop, 2007).

1.1.2 General mechanisms of the ocular surface defense

The bony formation of the orbit and the eyelids are considered like an external shield which protect the OS from any injury (Snell and Lemp, 1998). Also tears, corneal nerves, the epithelium, keratocytes, polymorphnuclear cells, antimicrobial peptides and cytokines represent the actual cellular protection against any invading micro-organisms on the corneal surface (Knop and Knop, 2007).

1.1.2.1 Tears:

There are several functions of the tears; ie: to prevent drying of the cornea, flushing foreign particles from the OS and transporting antimicrobial proteins (Immunoglobulin [Ig] A and G, lactoferrin, lysozyme, lipocalin, and beta-lysin) on the OS to combat against any infection (Louis, 1997, Knop and Knop, 2007).

1.1.2.2 Epithelial cells:

Corneal epithelial cells participate in the immune defence by secreting cytokines (Interleukin 1a [IL-1a] which is essential in protecting against microbes). Antimicrobial peptides (AMPs) are also significant constituents of the innate immune defence system which are produced mainly by epithelial cells and neutrophils (see below) (Mondino and Brady, 1981, McDermott, 2004).

1.1.2.3 Keratocytes:

Under the influence of the cytokines, keratocytes can produce IL-6 and defensins (major part of the AMPs group) (Gottsch et al., 1998, Ganz et al., 1985).

1.1.2.4 Corneal nerves:

Corneal nerves play a major role in protecting the cornea by conveying the sensory stimulations leading to reflex movements and producing neuropeptides. These peptides induce cytokine activity resulting in

neutrophil influx as a response to OS irritation (Muller et al., 1996, Tran et al., 2000).

1.1.2.5 Complement:

Complements are enzymatic proteins that play a role in inflammation and can regulate the production of the opsonins, enzymes and chemotaxins (Law SKA, 1995).

1.1.2.6 Interferons:

Interferons (IFN) are cellular proteins produced in response to viral infection. On the OS, they are secreted from different types of cells; IFN- α is secreted by leucocytes, IFN- β by fibroblasts and IFN- γ by adaptive immune cells (Thacore et al., 1982).

1.1.2.7 Cells of innate immunity:

Neutrophils are major components of the innate immunity. They play a vital role in protecting the OS from microbes' invasion. They also regulate the phagocytosis and microbial killing (Burg and Pillinger, 2001). Moreover, eosinophils, which have IgE surface receptors, play a role in parasitic toxicity by their protein granules (Trocme and Aldave, 1994). Also, macrophages have the ability to combat against microbial infections by secreting the inflammatory cytokines and their phagocytosis and antigen presenting capabilities (Underhill and Ozinsky, 2002).

1.1.3 Antimicrobial peptides

1.1.3.1 General overview of AMPs

AMPs are innate immunity effectors exist in plants, animals and vertebrates (Brown and Hancock, 2006). They are small amphipathic cationic peptides with 12 to 50 amino acids and 2–9 positively charged lysine or arginine. They have antimicrobial activity against Gram-positive and Gram-negative bacteria, viruses and fungi (Huang et al., 2007a, Huang et al., 2006, Huang et al., 2007b, Ganz et al., 1985, McDermott, 2004, Gropp et al., 1999, Buck et al., 2006). They can play an important role in innate immunity by reducing the titer of microbes without producing damaging persistent inflammatory response (Chodosh and Kennedy, 2002). They also have other additional cellular effects in mammals such as participating in adaptive immunity, wound healing and angiogenesis. Defensins and cathelicidins are the major subtypes of AMPs in humans; they are primarily secreted from the immune and epithelial cells (McDermott, 2004).

1.1.3.2 Main subtypes of AMPs

1.1.3.2.1 Defensins

Mammalian defensins are 29 to 45 amino acids in length with 6 cysteine residues forming 3 disulphide bonds. This linkage between the cysteine residues is responsible for the β -sheet structure. According to the location and connectivity of these links, defensins can be divided into two main groups, α and β defensins (Ganz, 2003). Of note, θ

defensin, a third class of defensins with circular structure, has been identified in rhesus macaque leucocytes (but not in humans) (Leonova et al., 2001). Six α and 4 β -defensins has been isolated in humans. The α -defensins are constitutively expressed and formed by 90–100 amino acids (Valore and Ganz, 1992). These are human neutrophil peptide (HNP) 1 to 4 and human defensin (HD) 5 and 6. HNP1–4 are mainly concentrated in the azurophil granules of the human neutrophils where they fuse with the vacuoles containing the invading micro-organism during phagocytosis (Ganz, 1987, Ganz, 2003). HNP are expressed in human monocytes, lymphocytes and macrophages (Agerberth et al., 2000). Paneth cells of human intestine are the main repertoire of other α -defensins: HD5 and HD6 (Jones and Bevins, 1992). HD5 has also been identified in female reproductive epithelium nasal and branchial epithelia (Quayle et al., 1998).

The four human β -defensin (hBD) 1–4 are mainly produced by the epithelial cells. However, immune cells (macrophages and dendritic cells) are known to produce hBD1 and 2 only (Duits et al., 2002). HBD1 is constitutively expressed by epithelial cells in multiple human tissues including airway epithelia (McCray and Bentley, 1997), urogenital tissues (Valore et al., 1998), nasolacrimal duct (Paulsen et al., 2001), and mammary gland (Jia et al., 2001). HBD2 and 3 are inducible in many epithelia by bacterial products (via toll like receptors) and cytokines (Harder et al., 1997, Garcia et al., 2001a). The inducible expression of hBD4 in testes and epididymis has also been reported (Garcia et al., 2001b, Yamaguchi et al., 2002). More recently, hBD9

(gene analogue of DEFB109) has been shown to be constitutively expressed in gingival keratinocytes and to be reduced expression after *in vitro* stimulation with *Candida albicans* (Premratanachai et al., 2004).

1.1.3.2.2 Cathelicidins

While other mammals express different types of cathelicidins, humans only produce LL37. It is so called because it begins with 2 leucine residues and 37 amino acids long (Agerberth et al., 1995, Cowland et al., 1995) Initially, LL37 was isolated from neutrophils, immune cells, mast cells and variety of epithelia (lung, skin, squamous epithelia of mouth, reproductive female epithelia and sweat glands) (Di Nardo et al., 2003, Murakami et al., 2002). LL37 expression is constitutive in many tissues but shows inducible nature by microbes and cytokines (Ooi et al., 2007, Wang et al., 2004).

1.1.3.2.3 Other AMPs

While defensins and cathelicidins comprise the main AMPs groups in humans, other AMPs have also been identified. Liver expressed antimicrobial peptide (LEAP1, also known as hepcidin) is 25 amino acid peptide highly expressed in liver. It plays a major role in iron homeostasis of the body which could enable it from excreting an antimicrobial effect by restricting the iron availability to invading pathogens (Ganz, 2006). LEAP2 has also been isolated from peripheral blood film and is mainly expressed in Liver (Krause et al., 2003). Furthermore, ribonuclease 7 (RNase7) has been found to exhibit *in*

vitro broad spectrum antimicrobial activity against different bacteria (including vancomycin-resistant *Enterococcus faecium*) and the yeast (*Candida albicans*) (Harder and Schroder, 2002, Torrent et al., 2010). Also, it has showed increased immune activity in normal human scalp skin treated with lipopolysaccharide (LPS) and flagellin (Reithmayer et al., 2009, Mohammed et al., 2010b). Moreover, histatin is an AMP mainly produced by salivary glands and shows anti-fungal activity (Kavanagh and Dowd, 2004). Also, thymosin β -4 has also been isolated from platelete and exhibited antimicrobial activity (Tang et al., 2002).

1.1.3.3 AMPs' Mechanism of action

AMPs are mainly secreted in response to cell signalling from cellular toll like receptors (TLRs) which engage microbes to activate production of these peptides. Activation of these receptors induces a cascade of down-stream signals leading to activation of transcription factor NF-kB followed by release of cytokines, chemokines, and AMPs. These participate in inflammatory responses, which in turn switch on the adaptive immune system. The expression of these antimicrobial molecules renders epithelial cells and infiltrated poly-morphnuclear cells (PMN) the ability to kill the invading bacteria. This enhanced innate defense is believed to play a role in limiting infection when host-pathogen interaction occurs (Redfern et al., 2011). The most acceptable hypothesis contributes the AMPs' anti-microbial effect to their increased positive surface charge. They can interact with negatively charged components of the pathogen cell membranes,

especially phospholipids, of microbial cell membranes, leading to electrostatic disruption and increased permeability of these cell membranes and death. This preference of AMPs for microbes' cell membranes is because of the highly negative charge of these membranes compared with the human cell membranes which have neutral charge. In addition, the cholesterol layer in the human cells inhibits the lysis effect of these AMPs (Matsuzaki et al., 1995, Tytler et al., 1995). However, it should be noted that high concentrations of AMPs could be cytotoxic to body cells regardless of the mechanism involved (Ganz, 2003, Kagan et al., 1994). This antimicrobial effect shows its maximum peak during low micro-molar and high carbonate range (Dorschner et al., 2006). This leads to less *in vivo* antimicrobial activity of AMPs compared with their *in vitro* activity as the effect of tears is inhibiting. However, some defensins (like hBD3) are less salt sensitive than others (Schibli et al., 2002).

1.1.3.4 AMPs at the ocular surface

As on the human OS, defensins and cathelicidin are the major AMPs groups at the OS. Regarding the defensins, both α and β human defensins are expressed at the OS with infiltrating neutrophils being the major source of α defensins and the OS epithelial cells showing the main repertoire of the β defensins (Gottsch et al., 1998). However, expression by immune cells like monocytes, macrophages and dendritic cells has been described (Duits et al., 2002). The expression of HNP1-3 has been detected in human corneal stroma in post immune rejection

and infection (but not in healthy corneal tissue) (Gottsch et al., 1998). Moreover, positive immune-reactivity for HNP1–3 in inflamed conjunctiva and samples of normal tear film has been reported. However, the gene expression of α -defensins HD5 and HD6 has never been detected on OS (Haynes et al., 1999, Haynes et al., 1998). Human β defensins are produced from the epithelia of the conjunctiva and cornea. Indeed, hBD1 is constitutively expressed whereas the expression of hBD2 and hBD3 is mainly inducible by pathogens or cytokines and mainly mediated by TLRs (McDermott, 2004, Kumar et al., 2007a, Mcnamara et al., 1999, Kumar et al., 2007b, Kumar et al., 2004). While HNP1–3 are consistently found in tears in any inflammation, there is no evidence that β defensins are available in tear film (Zhou et al., 2004). HBD4 was not detected in OS cells (Huang et al., 2007a) although it was variably expressed in cultured OS cells (McIntosh et al., 2005). As reported by Abedin et al, The *ex vivo* gene expression of hBD9 in impression cytology samples has shown down-regulation in samples taken from patients with infectious keratitis and dry eye syndrome (Abedin et al., 2008). Moreover, a significant late down-regulation of hBD9 mRNA in response to cytokines stimulation in addition to a hBD9 constitutive protein expression on the OS epithelia has been reported by our group (Mohammed et al., 2010a).

LL37 is expressed from epithelial cells and invading neutrophils showing constitutive and inducible pattern of expression. It has already been shown to have important effect in protecting the OS against *Pseudomonas* infections (Redfern et al., 2011). Indeed, LL37 has *in*

vitro bactericidal activity against both Gram-negative and Gram-positive bacteria in addition to its anti-viral effect (Huang et al., 2007a, Gordon et al., 2005a). It is derived from human cationic antimicrobial protein and has chemotactic effects for leukocytes stimulating cellular inflammation (Befus et al., 1999, Niyonsaba et al., 2001, Mendez-Samperio, 2010). Recently, Redfern et al have reported that the production of LL37 is stimulated by the TLR agonists which may play a role in providing the OS with direct defence against various pathogens and stimulating the innate and adaptive immunities through the immune and inflammatory activities (Redfern et al., 2011, Mendez-Samperio, 2010). Furthermore, it has also been reported that LL-37 can induce cellular migration and production of inflammatory mediators following injury or insult to the OS (Huang et al., 2007a, Mendez-Samperio, 2010).

The expression of LEAP1 and 2 mRNA was firstly detected by McIntosh et al (McIntosh et al., 2005). The role of LEAP1 as an antibacterial agent is limited on the OS but it may have a greater role against virus infections (Mohammed et al., 2011). The actual LEAP2 antimicrobial effect is not clear (Hocquellet et al., 2009).

Recently, the constitutive presence of RNase-7, both protein and mRNA, on human OS has been reported by our group. This expression was increased in response to IL-1b suggesting an active role during inflammation related to OS infection (Mohammed et al., 2010b).

In addition to the previous AMPs, thymosin β 4 and histatin were variably detected on the OS (Huang et al., 2007a).

1.1.3.5 How do AMPs behave on the OS?

AMPs express the bactericidal activity either by producing higher concentrations (Huang et al., 2006) or by synergy between each other (Nagaoka et al., 2000, Chen et al., 2005). Indeed, besides their essential role as bacteriocidal agents, these cationic host-defence peptides have a wide range of immune properties, including direct chemo attraction of immune cells, induction of chemokines, differentiation responses, promotion of wound healing and angiogenesis (Oppenheim and Yang, 2005, Bowdish et al., 2005, Finlay and Hancock, 2004, Huang et al., 2006). The negative impact of the tears on the mechanism of killing pathogens has no influence on the non-antimicrobial effects of the AMPs (Huang et al., 2007a, Huang et al., 2007b). It has been shown that not all the effects of the antimicrobial peptides are beneficial to the eye. Occasionally, excessive recruitment of the immune cells can cause unpredicted inflammatory response which may damage the eye surface. For example, the angiogenic effect of the LL37 at the OS is not a desirable outcome (McDermott, 2004) and the up-regulation of hBD2 in non-Sjogren's dry eye can produce severe ocular irritation (Narayanan et al., 2003).

1.1.3.6 Potential of antimicrobial peptides as ocular therapeutics

There are a lot of difficulties in developing AMP peptides as therapeutic agents because of their sensitivity to ionic balance, cytotoxicity, susceptibility to proteolysis, and cost of pharmaceutical production (Marr et al., 2006, Hancock and Sahl, 2006). Nevertheless, as has been reported before, the application of AMPs can increase the antimicrobial property of contact lens cleaning solutions (Sousa et al., 1996) as well as that of corneal storage media (Schwab et al., 1992). Also, some peptides has been under development in the pharmaceutical industry such as (I-PREX) as a possible treatment for infected corneal ulcers (Ganz and Weiss, 1997). However, the direct application of synthetic AMPs on the OS in animal models has not shown encouraging results (Mannis, 2002, Brandt et al., 2007). As a result, some studies have reported an alternative approach by stimulating the production of AMPs on the OS to protect against the microbes infections. In accordance with this concept, Kumar et al have recently shown that prior application of flagillin (TLR5 agonist) can reduce the inflammatory response and corneal destruction in murine corneas infected with *Pseudomonas aeruginosa* (*P. aeruginosa*) (Kumar et al., 2008).

1.2 MICROBIAL KERATITIS

Microbial Keratitis is characterized by a defect of the corneal epithelium (the ulcer) with inflammation of the underlying corneal stroma (the

infiltrate or abscess) caused by pathogens like: bacteria, viruses, fungi and protozoa (Keay et al., 2006).

1.2.1 Corneal morbidity in microbial keratitis

The tissue destruction in infectious ulcers is a compound effect of inflammatory mediators released by the microorganism, host inflammatory cells and the metalloproteases that act on the collagen. Apoptotic cell loss may be an attempt by the host stroma to escape the necrosis and minimize the tissue damage. Breakdown of the physiological barrier of epithelium and the tear film leads to the entry of microorganisms, which proliferate in the stroma. This is followed by a sequence of events including oedema, inflammatory cell influx from tears, limbus, abscess formation and necrosis of the stroma. During the healing phase, there is cellular migration of the epithelial cells into the crater of the ulcer, growth of blood vessels into the stroma, proliferation and migration of stromal fibroblasts and influx of macrophages which results in the scar formation (Vemuganti et al., 2004). This process involves several matrix metalloproteinase (MMPs) in the cornea which are up-regulated by transcription or activation. It has been demonstrated that MMP1-3 & 9 participate in epithelial repair and stromal remodelling. (Mulholland et al., 2005) Of note, the degree of opacification and visual dysfunction appears to be related to the number and density of inflammatory cells and their location, vascularisation and the enzymatic stromal damage. The visual recovery would therefore depend on the elimination of the inflammatory cell

infiltrates, regression of edema, location and density of scarring and the newly developed vessels (Vemuganti et al., 2004).

1.2.2 Types of Microbial Keratitis

The main types of the microbial keratitis are bacterial, amoebic (*Acanthamoeba*), fungal and viral keratitis (viral infections will not be discussed further in this chapter, as cases with active viral keratitis were excluded from our study).

1.2.2.1 Bacterial keratitis

Bacterial keratitis is considered the main cause of unilateral blindness in the developing world (Whitcher, 1990). After the huge increase in the number of contact lens users, the relative incidence of *Pseudomonas* and *Staphylococcal* infection has gone up (Ormerod and Smith, 1986).

1.2.2.1.1 Risk factors for bacterial keratitis

Diseased or damaged corneal epithelium is the main predisposing factor for corneal infection. However, organisms such as *Corynebacterium diphtheriae*, *Haemophilus aegyptius*, *Neisseria gonorrhoeae*, *Neisseria meningitidis*, *Shigella*, and *Listeria* species can penetrate an intact epithelium causing corneal infection (Kanski, 2011). Risk factors for infectious corneal ulceration due to non-viral pathogens are many. These include trauma to the eye, extended wear of contact lenses, chronic OS disease, prior ocular surgery, corneal exposure (lagophthalmos), systemic diseases such as diabetes mellitus and rheumatoid arthritis, use of topical corticosteroids or corneal

hypoesthesia. However, around 10% of individuals with infectious keratitis may not exhibit any risk factor of infection (Keay et al., 2006).

1.2.2.1.2 Clinical features

Early symptoms of bacterial ulceration include: redness, tearing, pain, photophobia, discharges and secretions, decreased vision (Thomas and Geraldine, 2007). The specific signs of the corneal infection are the following: Eyelids oedema, an epithelial defect with infiltrates in the stroma, stromal oedema, hypopyon, endothelial precipitates, melting, perforation and endophthalmitis (in severe cases). Scleritis may also develop in certain cases where infections are located at the periphery (Moshirfar et al., 2006).

1.2.2.1.3 Causative organisms

Bacterial culture may show positive results in 55% to 67% (Parmar et al., 2006b); the remaining sterile ulcers may be due to non-microbial causes or may be of infectious origin with no obvious isolated pathogen (Thomas and Geraldine, 2007). The main causes of failure in isolating the causative bacteria are: lack of sample material, delay in taking samples, inappropriate culture media or certain corneal stains such as rose bengal and lissamine green which have antimicrobial effect (Seitzman et al., 2006). Notably, topical antibiotics may only delay results of the culture because of the long time taken to reactivate pathogens in culture without affecting positive rates of culture of these organisms (Marangon et al., 2004a).

Causative pathogens and predisposing factors

Demographic distribution plays the main role in isolating the agent which causes trauma-associated corneal infection. In an Australian study, corneal scrapings from patients with traumatic infectious keratitis aged 15–64 years showed no growth of organisms in 60% and growth of Gram-positive bacteria (mainly: Coagulase-negative *Staphylococci*) in 31% (Keay et al., 2006). However, in India, the same age group of patients with corneal ulcers due to trauma yielded no growth in 35%, growth of filamentous fungi in 32.7% and *Streptococcus pneumoniae* and *P. aeruginosa* in 25%. (Parmar et al., 2006b) In another Malaysian study, the commonest isolated bacteria in traumatic infectious keratitis were and *Staphylococcus aureus* (*S. aureus*) (Hooi and Hooi, 2005).

Due to widespread use of contact lens (CL), microbial keratitis becomes a serious complication which occurs in 1 out of 10,000 rigid CL, 4 out of 10,000 daily soft CL and 20 out of 10,000 extended soft CL wearers. Although there is no risk of visual loss due to sterile keratitis associated with contact lens wear, the risk of losing the vision from contact lens-related microbial keratitis is approximately 0.3 to 3.6 per 10,000 (Keay et al., 2007). Worldwide, the common aetiological pathogens of lens-associated corneal ulcers appear to be *P. aeruginosa* and *Acanthamoeba* (Watt and Swarbrick, 2005, Sun et al., 2006b, Sun et al., 2006a, Parmar et al., 2006a). Non-tuberculous *mycobacteria* (NTM) is considered the main cause of infections in patients post laser-

assisted in situ keratomileusis (LASIK) (Umapathy et al., 2005). Worldwide, *Staphylococci* (Moshirfar et al., 2006), fungi, *Streptococci*, *Nocardia* (Patel et al., 2005) and *P. aeruginosa* (Sharma et al., 2006) are frequently isolated bacteria from corneal infections related to previous ocular surgery and ocular surface diseases.

Clinical characteristics of the most common causative bacteria

Staphylococci

S. aureus are Gram-positive cocci which form clusters in stained smears. They are generally commensal bacteria which may infect the cornea when the epithelium is compromised. The distinctive clinical signs of this infection are: round or oval epithelial defect with well-defined creamy or gray stromal infiltrate and minimal stromal haze. *S. epidermoids* also gives the same clinical picture but with less aggressive course of action (Thomas and Geraldine, 2007, Kanski, 2011)

Streptococci

Streptococci are Gram-positive cocci which mostly gather in chains. An epithelial defect is vital for Pneumococcal corneal infection. Generally, early infiltration can readily spread leading to deeper stromal abscess, plaque formation, fibrin deposition and anterior chamber reaction with hypopyon. Stromal melting of the cornea can induce an undermined leading edge with overhanging tissue. *Streptococci viridans* (*S. viridans*) tends to cause less aggressive infection than *Streptococci pyogens* (*S. pyogens*), as seen in infectious crystalline keratopathy (Kanski, 2011).

Bacillus

Bacillus cereus (*B. cereus*) is an extremely virulent, Gram-positive rods. Corneal infection can aggressively be seen after penetrating injury, especially when there is soil contamination. There is often microcystic oedema in the peripheral or whole cornea followed by a circumferential corneal abscess. Because of the huge virulence of this pathogen, perforation of the cornea can develop within hours (Yanoff and Duker, 2004).

Corynebacteria

Corynebacteria diphtheriae (*C. diphtheria*) are Gram-positive, club-shaped or pleomorphic rods. The infection frequently begins with diffuse epithelial haze, followed by stromal necrosis and melting (Yanoff and Duker, 2004).

Listeria

Listeria is an anaerobic, Gram-positive rod. Keratitis caused by this organism usually occurs in eyes of people who deal with animals. It can cause keratitis with necrosis. Typically, there is a ring ulcer and a severe anterior chamber reaction with fibrinous exudate and a hypopyon (Yanoff and Duker, 2004).

Clostridium

Clostridia are Gram-positive bacilli which form spores. Rarely, *clostridial* conjunctivitis may develop to marginal keratitis. Interestingly, it tends to produce gas in the epithelial, sub-epithelial and stromal layers of the

cornea leading to mild bullous keratitis and/or gas bubbles seen in the anterior chamber (Ostler HB, 1993).

Propionibacterium Acnes

Propionibacterium acne is Gram-positive, anaerobic rod which can produce spores. It is a commensal organism which can cause infection in the event of ocular trauma, eye surgery, CL wear or prolonged use of topical corticosteroids. The clinical picture looks like the classical infectious keratitis, although it can follow an indolent course in some cases. Growth in culture should be monitored for at least 10 days to exclude the diagnosis of this organism (Zaidman, 1992).

P. aeruginosa

It is an aerobic Gram-negative organism which tends to live in the moist places. At the OS, *P. aeruginosa* is the most frequent cause of the corneal ulcers caused by CL wear (Bharathi et al., 2007). The host response is very crucial in pathogenesis of *P. aeruginosa* keratitis (Thomas and Geraldine, 2007). The clinical signs comprise rapid invasion of the damaged epithelium and stroma with production of destructive enzymes such as protease, lipase, and elastase which in turn cause necrosis of the stroma. In some cases corneal haze in the surrounding tissue 'Immune ring' can also be found (Thomas and Geraldine, 2007).

Serratia

Serratia are Gram-negative rods which can produce exotoxins and proteases. Hydrophilic CL wear is a predisposing factor for ocular infection. The classical clinical signs are superficial, central or paracentral ulcers, which can develop to a deep, ring shaped ulcer. They can also cause intraepithelial corneal nodules and granular stromal appearance (Yanoff and Duker, 2004).

Escherichia, Klebsiella, and Proteus

Like the other Gram-negative bacteria, infection with these rods is usually accompanied by CL wear. The infection can resemble virulent *pseudomonal* keratitis with ring ulcers, necrosis and perforation. Suppurative keratitis caused by *Escherichia coli* (*E. coli*) is typically more indolent with hypopyon formation and severe iridocyclitis (Yanoff and Duker, 2004).

Haemophilus

Haemophilus Influenza (*H. influenza*) is a fastidious Gram-negative rod. It can frequently causes conjunctivitis which may lead to keratitis. The corneal infection is usually superficial but severe with suppuration and hypopyon formation (Yanoff and Duker, 2004).

Moraxella

Moraxella bacilli are large, Gram-negative or Gram-variable bacteria. The ocular infection is seen in alcoholic and debilitated patients. Clinically, the keratitis begins with blepharoconjunctivitis which may associate with marginal ulcers. It can cause disastrous visual outcomes

despite treatment because of both the predisposing factors and the nature of the disease (Das et al., 2006).

Kingella kingae

These are Gram-negative, aerobic, rod-shaped bacteria. It can rarely cause corneal ulcers and upper eyelid abscesses (Hiti et al., 2006, Mollee et al., 1992).

Neisseria

Neisseria gonorrhoeae (*N. gonorrhoeae*) and *Neisseria meningitidis* (*N. meningitidis*) are intracellular Gram-negative diplococci. They can affect the intact corneal epithelium to produce diffuse edema or ring ulcer with hypopyon and necrosis (Kanski, 2011).

Non-tuberculous mycobacteria

Among the non-tuberculous *Mycobacteria*, *Mycobacteria fortuitum* (*M fortuitum*) and *Mycobacteria chelonae* (*M chelonae*) are most commonly associated with ocular infection. These acid fast, long rods can grow in disinfecting materials and are found in soil. Commonly, corneal infection with these bacteria follows eye trauma or ocular surgery (penetrating keratoplasty, lamellar refractive surgery) and tends to behave like indolent mycotic keratitis. The infiltrated center of the ulcer shows a cracked wind-shield type of appearance with multiple radiating lines and a non-suppurative infiltration (Thomas and Geraldine, 2007).

1.2.2.1.4 Diagnosis

In recent years, there have been notable advances in non-invasive techniques for diagnosis of infectious keratitis and in molecular techniques for diagnosis of infectious keratitis (Thomas and Geraldine, 2007). The following are the most common techniques used in isolating the causative organisms of the infectious keratitis:

Non-invasive techniques

Non-invasive methods of diagnosis include impression cytology, *in vivo* confocal microscopy and anterior segment optical coherence tomography. In our study, we have also used the Oculus Pentacam as a novel method in following up patients with microbial keratitis.

Impression cytology (IC): This relatively non-invasive technique can be used as a diagnostic tool of ocular surface diseases (which include infectious keratitis). A cellulose acetate filter is applied to the corneal surface to remove the superficial layers of the epithelium. Then further histological, immunehistological or molecular analysis may be performed to the cells obtained (Singh et al., 2005) (further information are illustrated in **chapter four**).

In vivo confocal microscopy (IVCM): Advanced tandem scanning confocal microscopes and the Heidelberg retina tomograph II (HRT-II) with cornea module allow *in vivo* examination of the corneal cells. *In vivo* confocal microscopy is primarily of value in the diagnosis of fungal and *Acanthamoeba* keratitis wherein the organisms can be demonstrated rapidly without waiting for outcomes of *in vitro*

laboratory cultures (Vaddavalli et al., 2006, Pfister et al., 1996). Although it can be very useful in excluding fungal and *Acanthamoeba* keratitis, Its role is still limited in the diagnosis of the bacterial keratitis (Labbe et al., 2006).

Anterior segment optical coherence tomography (AS-OCT): Recently, corneal imaging has been used as a means of recording extent of infiltrate and determining the initial response to treatment. This new technology is very useful in observing the progress of corneal infections. It can provide numerical values of the dimensions and depth of the infiltration and the overall inflammatory state of the cornea with high quality cross sections of the entire cornea (Konstantopoulos et al., 2008, Konstantopoulos et al., 2007).

The OCULUS Pentacam: The OCULUS Pentacam (Oculus Inc., Germany) is a non-invasive optical system, which has specifically been designed to assess the anterior segment of the eye. It can measure the corneal thickness, corneal topography, and densitometry (Oculus, 2003). These could be very useful in following up patients with corneal infections. (Further details are mentioned in **chapter six**)

Conventional & invasive methods of specimen collection

Corneal scrapings: Samples from cornea, usually scrapings, may be obtained to identify the aetiological bacteria in infectious keratitis. The samples are examined microscopically by using various stains or inoculated on to appropriate culture media (Umapathy et al., 2005, Joseph et al., 2006). Corneal sampling is usually deferred for specific

cases of suspected bacterial ulcers such as advanced or central ulcers or if signs are suggestive of non-typical bacteria. Treatment modification is usually not needed as 95% of cases respond to the initial antibiotic regimen (O'Brien et al., 1995, McLeod et al., 1996). There is also a significant role of scrapings performed with a calcium alginate swab moistened with soy broth in the recovery of organisms (Benson and Lanier, 1992). Gram and Giemsa stains are considered the most common stains used in diagnosing infectious ulcers. Gram stain is very useful in differentiating between bacteria and yeasts whereas Giemsa stain is helpful for cytology and to characterize bacteria, fungi, and chlamydia. Ziehl-Neelsen stain is the best choice if filamentous bacterial or non-tuberculous mycobacterial infection is suspected (Yanoff and Duker, 2004).

Corneal biopsy: Corneal biopsy is considered in suspected protozoan, mycobacterial, or mycotic infections; isolating microorganism when classical antimicrobial treatment fails to resolve the infection which had no established diagnosis with prior scrapings. Also it should be considered in patients with infectious keratitis related to previous LASIK where material from the stromal bed should be examined. Like corneal scrapings, the corneal biopsy should involve the active edge and base of the ulcer. A lamellar technique is required if the infiltrate invades the stroma (Alexandrakis et al., 2000).

1.2.2.1.5 Treatment

Medical treatment

Infectious corneal ulcers are potential emergencies where treatment should be urgent to avoid sight threatening sequelae. The goals of the treatment are to stop the replication of bacteria, reduce overactive inflammation, minimize pain and other symptoms and encourage corneal healing. Treatment is usually in the form of topical antimicrobials but occasionally systemic medication may be required. Indications for systemic antibiotics include keratitis complicated with scleritis, risk of perforation or when endophthalmitis is suspected.

Fortified topical antibiotics and fluoroquinolones are the ideal treatment of bacterial keratitis (Thomas and Geraldine, 2007). Arguably, monotherapy with fluoroquinolones is the first line in therapy of most ulcers although in vitro studies have shown resistance for some strains (Stefan and Nenciu, 2006). The initial broad-spectrum therapy can be achieved either by a combination of topical fortified aminoglycoside and cephalosporin/ vancomycin eye drops or fluoroquinolone eye drops monotherapy. This empirical approach is effective in 95% of cases of infection (O'Brien et al., 1995). According to one study, when combined therapy with cephalosporin and gentamicin was tried to treat eyes with infectious keratitis, there was a clinical lack of response in 13% and treatment failure in 4%, whereas when ciprofloxacin monotherapy was used in another nonrandomized study there were no treatment failures in all cases (Ly et al., 2006). There are several causes for failure of

fluoroquinolone monotherapy such as inadequate frequency of applications and late initiation of therapy. These are considered risk factors for eye perforation in patients with infectious corneal ulcers. In clinical practice, fluoroquinolones are considered effective empirical therapy because of their readily availability and relative safety (Titiyal et al., 2006). On the other hand, both fortified vancomycin and gentamicin remain at least 95% effective against OS bacteria (Marangon et al., 2004b). To achieve the therapeutic levels of the antibiotic in the cornea, frequent topical application of the drug is recommended. Antibiotic eye drops should be instilled every 5 minutes in the first 25 minutes then every 15 minutes for the next hours. Then, the frequency can be reduced to one drop hourly according the clinical response. Subsequent treatment is decided according to clinical response (Kanski, 2011).

Reduced pain and discharge are the two early symptomatic indicators of a favourable response to therapy. The initial signs of satisfactory response to treatment are arrest of progression (failure to worsen), stabilization of the depth of infiltrate and reduced infectious activity at the infiltrate's margins. The other subsequent signs of improvement comprise continuous healing of epithelial defect, clearing of the stromal infiltrate with decreasing adjacent oedema and anterior chamber reaction. As a general rule, treatment should be continued at least until the epithelium has completely healed (one week after the healing of the epithelial defect in *P. aeruginosa* infection) (Yang et al., 2006). Corticosteroids can be used to minimize the adverse sequelae of

infectious keratitis such as perforation, vascularization, and scarring. However, corticosteroids have been associated with inhibition of healing and if antibiotic therapy is improper, corticosteroids have been found to promote bacterial replication. Hence corticosteroids should only be used after initial evidence of successful antibiotic treatment. Interestingly, a recent randomized controlled study has shown that the topical steroids use did not correlate with any overall improvement in the final visual of patients with infectious keratitis (Srinivasan et al.)

Povidone-iodine may be used to reduce the load of bacteria in corneal ulcers before starting antibiotics therapy (Gregori et al., 2006). However, a single application of 5% betadine (povidone-iodine) has not found to reduce the bacterial load of corneal ulcers more than just scraping alone, possibly because of poor penetration and the large number of pathogens (Thomas and Geraldine, 2007).

Surgical intervention

Surgical intervention is mandatory if stromal necrosis develops to perforation. Small perforations with mild necrotic bed of the ulcer can be treated by the application of cyanoacrylate corneal glue. If the necrosis is extensive or perforation is large, penetrating keratoplasty is indicated (Hill, 1986). It has been found that debulking and layer-by-layer removal of host corneal tissue can protect the iris while doing therapeutic keratoplasty in eyes with perforated corneal ulcers with incarcerated iris (Vajpayee et al., 2006).

In severe bacterial keratitis, it has been reported that early amniotic membrane transplantation (AMT) with topical corticosteroid provides quick pain relief and allows healing of the epithelium (Gicquel et al., 2007). Moreover, The transplanted amniotic membrane (AM) improves the healing process, resulting in decreased corneal haze and less neovascularization (Keay et al., 2006). Human AM has antibacterial, antiangiogenic, anti-inflammatory and antifibroblastic properties. These characteristics may play a role in the use of AM transplantation in the treatment of infectious keratitis (Barequet et al., 2008). Studies have shown that human AMT promotes rapid epithelialization and reduces stromal inflammation and ulceration in herpes simplex keratitis (Heiligenhaus et al., 2003). When used with antibiotics as adjunctive treatment, AMT enhanced epithelialisation and prevented corneal perforation in infectious keratitis. Indeed, AM also promoted wound healing, reduced inflammation and neovascularization and improved visual acuity without scarring (Barequet et al., 2008, Kim et al., 2001). Furthermore, Gicquel et al reported immediate pain relief and epithelial healing attributed to early AM transplantation combined with topical corticosteroids in patients with severe non healing infectious ulcers (Gicquel et al., 2007).

Conjunctival flaps can also be used to treat peripheral infectious ulcerations as the conjunctival vessels help in healing and scarring. However, conjunctival flaps should not be placed over a corneal perforation (Tuli et al., 2007).

After corneal healing, persistent anterior stromal scars can sometimes be removed by excimer laser phototherapeutic keratectomy (Prochazkova et al.). Deeper scars may require lamellar or penetrating keratoplasty. This procedure should preferably be done after closure of superficial or deep vessels by performing fine needle diathermy, argon laser occlusion or use of anti vascular endothelial growth factors (VEGFs) to reduce risk of vascular graft rejection (Pillai et al., 2000).

1.2.2.2 Parasitic keratitis (*Acanthamoeba keratitis*)

Acanthamoeba is a free-living genus of amoeba that is abundant in the environment. It survives in diverse conditions and has been isolated from soil and dust, air and water (such as ponds, swimming pools, hot tubs, and contact lens disinfectant solutions) (Illingworth and Cook, 1998). Patients who use contact lenses are at particular risk, they form the majority of cases with this infection. Furthermore, co-contamination with bacteria appears to be an important risk factor for the adherence of *Acanthamoeba* to hydrogel lenses (Gorlin et al., 1996). Rinsing the lenses in tap water may predispose specifically to *Acanthamoeba* infection (Lam et al., 2002).

1.2.2.2.1 Clinical features

Generally, patients with *Acanthamoeba* keratitis complain of symptoms like: pain out of proportion of clinical appearance (Azuara-Blanco et al., 1997), photophobia, tearing and reduced visual acuity with a history of contact lens wear (Parmar et al., 2006a). The early signs of

Acanthamoeba keratitis can include punctuate epithelial erosions (McCulley et al., 2000), epithelial irregularity of vesicular appearance in a linear or pseudo-dendritic pattern with little discharge (Azua-Blanco et al., 1997), limbitis, infiltrates in anterior stromal and perineuritis. A mild anterior chamber reaction may be seen. There may be a dendriform keratitis that is often mistaken for a herpes simplex infection. As the condition progresses, a complete or partial stromal ring-shaped infiltrate is often observed, usually with an overlying epithelial defect (Joseph et al., 2006). In some circumstances, the presence of sterile scattered subepithelial and stromal infiltrates, especially in the peripheral cornea, may be evident. In advanced cases, marked stromal thinning and opacification occur frequently (Parmar et al., 2006a). In addition to the sight-threatening keratitis, infection by *Acanthamoeba* can also lead to iritis, hypopyon, scleritis, cataract and glaucoma (Umapathy et al., 2005).

1.2.2.2.2 Diagnosis

History of contact lens wear with exposure to contaminated water, severe pain in the affected eye, negative laboratory cultures for bacteria, fungi and viruses, together with a lack of response to conventional antimicrobial therapy may suggest *Acanthamoeba* keratitis (Moshirfar et al., 2006). Corneal scrapings should always be performed to confirm the diagnosis of *Acanthamoeba* keratitis. However, corneal biopsy may be required if microbiology examination and culture is inconclusive. The cysts of *Acanthamoeba* can be diagnosed by using

Gram's and Giemsa stains or by using Calcofluor white stain with fluorescent microscope. After performing the corneal scrapings or biopsies, the samples are inoculated onto a lawn of *E. coli* on non-nutrient agar or buffered charcoal-yeast extract agar to get the best recovery rate of the organisms (Dart et al., 2009). More recently, *in vivo* confocal microscope has been used to detect the cysts and trophozoites in the corneal tissue (Pfister et al., 1996). Impression cytology has also given the advantage of diagnosing superficial infections by using the histological and molecular analysis. (Sawada et al., 2004) Indeed, polymerase chain reaction (PCR) has been shown to be a sensitive method of detecting *Acanthamoeba's* DNA in the corneal scrapings and tears (Mathers et al., 2000).

1.2.2.2.3 Treatment

In the last decade, the main treatment was a combination of propamidine with neomycin, paromomycin, and/or imidazoles which were effective in only 50% of cases (Ficker et al., 1990). Later, cationic antiseptic factors such as polyhexamethylene biguanide (PHMB) and chlorhexidine have showed high effectiveness *in vitro* against *Acanthamoeba* cysts (Elder and Dart, 1995). There is interaction between the electropositive biguanide groups and the plasma membrane which may compromise the integrity of the mucopolysaccharide plug participates in the formation of the cyst (Seal et al., 1996). Povidone-iodine 2.5% to 5% solution was also found to be effective on both the trophozoites and the cysts (Gatti et al., 1998).

Augusto Blanco et al reported that an effective treatment protocol for *Acanthamoeba* keratitis which was combined topical therapy of hourly PHMB 0.02% and propamidine isethionate (Brolene) 0.1% along with Polyfax (polymyxin B sulphate and bacitracin zinc) ointment four times a day. The frequency of the application could be tapered gradually according to the clinical improvement. The period of treatment may take several months until complete healing and eradication of the trophozoites and cysts (Azuara-Blanco et al., 1997).

Corticosteroid application should probably be limited to cases with stromal infiltration at the site of the infection and with evident improvement of the infectious process (Azuara-Blanco et al., 1997) or patients with limbitis, scleritis, or uveitis (Bacon et al., 1993).

Surgically, AMT has been found to reduce the ocular inflammation, pain, and corneal neovascularization in *Acanthamoeba* ocular infection. It can be used in the inflammation phase which may defer any further surgical procedure (Bourcier et al., 2004). Penetrating keratoplasty, if needed, should be deferred to at least 6 months after complete healing to reduce the risk of rejection. However, therapeutic corneal grafting could be the only cure for refractive infections with high risk of failure (Azuara-Blanco et al., 1997).

1.2.2.3 Fungal Keratitis

Fungi are ubiquitous organisms which are frequently seen in the developing and tropical countries. Basically, they can be classified into filamentous and Yeast-like fungi. In tropical climates, trauma with plant

material is considered the main reason of fungal keratitis with filamentous fungi (*Fusarium*, *Aspergillus*), whereas in cooler climates, Yeast-like fungi such as *Candida* spp (Thomas and Geraldine, 2007). Trauma is the most important predisposing factor of the filamentous fungi infection, whereas OS disease, systemic disorders, and CL wear form the risk factors for *Candida* infection of the eye. Recently, a multi-country outbreak of *Fusarium* keratitis emphasizes that CL wear is a major risk factor for fungal keratitis (Thomas and Geraldine, 2007, Galarreta et al., 2007).

1.2.2.3.1 Clinical features

Filamentous fungal keratitis is a slowly progressive infection with serrated margins, raised slough and coloration other than yellow. According to one study, the probability of fungal infection if one of the previous signs is present was 63%; the presence of all three signs suggests an 83% chance of filamentous fungal keratitis (Erie et al., 1993). However, slow progression keratitis which resembles bacterial ulcer with overlying epithelial defect and isolated infiltrate are considered frequent features of *Candida* infection (Thomas and Geraldine, 2007).

1.2.2.3.2 Diagnosis

A clinical suspicion must be maintained with all corneal ulcers which do not respond to the classical antimicrobial treatment, especially with a history of chronic corneal disease, prolonged corticosteroid use or trauma with vegetable contamination. Also, patients with post LASIK

infections are at high risk (Kuo et al., 2001, Sridhar et al., 2000). To confirm the diagnosis and begin treatment, laboratory exams are required and scrapings for stains and culture should be obtained. Gram's stain, Giemsa stain, Gomori's methenamine silver, periodic acid Schiff (PAS), Calcofluor white and KOH are specific stains for fungi. Blood agar, Sabouraud agar or brain-heart infusion broth are the favourite media for fungal culture. However, media used for bacterial culture can be used for fungal culture if antibacterial agents are added (Thomas and Geraldine, 2007). Deep corneal biopsy is required in any case of deep stromal infiltrate with intact epithelium (Yanoff and Duker, 2004). Furthermore, IVCM may be useful in identification the fungal hyphae in the living cornea (Winchester et al., 1997). Recently PCR is found to be a sensitive and rapid method in the diagnosis of fungal corneal ulcers (Said et al., 2011, Kumar et al., 2005).

1.2.2.3.3 Treatment

For filamentous fungi, topical natamycin 5% or econazole 1% are considered the first line of treatment, whereas topical amphotericin B 0.15% is classified as the drug of choice for the candida infection (Said et al., 2011, Thomas, 2003). As an initial line of treatment, a reasonable approach for fungal keratitis would be a combination of amphotericin B 0.1 to 0.3% (which is the drug of choice for *Candida*) and econazole 1% (which is more effective against filamentous fungi). (Said et al., 2011) Oral fluconazole (200 mg) can be used in deep stromal infiltration (Galarreta et al., 2007, Thomas, 2003, Kalkanci and

Ozdek, 2010). For patients with hypopyon, an intravenous injection of fluconazole (100 mg) twice daily and atropine drops once daily are indicated. Intrastromal corneal injection of amphotericin B (5mg per 0.1 ml), sub-conjunctival fluconazole (0.5–1.0 ml of a 2% solution) and topical fluconazole with oral ketoconazole are other new ways of administration. (Thomas and Geraldine, 2007) Furthermore, an anterior chamber tap with intracameral injection of 5 µg of amphotericin B is an extremely useful procedure in the management of fungal ocular infections confined to the anterior segment (Sridhar et al., 2002). Recently, voriconazole, an agent derived from fluconazole has been approved for the treatment of invasive Aspergillosis and for serious infections caused by *Fusarium* species in patients intolerant of, or refractory, to other antifungals. Previous in vitro studies have shown that voriconazole has fungistatic activity against most yeasts and hyaline filamentous fungi. It exhibits dose-dependent pharmacokinetics and is well tolerated after oral or parenteral administration with resultant high and sustained blood and tissue levels following daily doses of 50 to 200 mg. Voriconazole is currently not a FDA approved drug for topical ophthalmic use (Ozbek et al., 2006).

According to Chen et al, when AMT along with antifungal agents were used to treat acute culture-proven fungal keratitis in 23 eyes, complete epithelialization was achieved in 75% of cases with active disease and in all cases with inactive disease (Chen et al., 2006). However, if the infection is not controlled with the intensive antifungal therapy, lamellar keratoplasty is recommended. Penetrating keratoplasty should be done

if lamellar keratoplasty fails, especially, in cases of filamentary fungal infection, where lamellar or penetrating keratoplasty may reduce the load of the infected tissue and promote healing (Lam et al., 2002).

CHAPTER TWO

2 Antimicrobial peptides gene expression by ocular surface cells in response to *Acanthamoeba castellanii*: An in vitro study

2.1 INTRODUCTION

The ocular surface comprises of cornea, conjunctiva, and tear film. Like other mucosal surfaces, it is in direct contact with the environment and exposed to environmental pathogens such as bacteria, viruses, fungi, and protozoa. It also maintains a population of commensal organisms, which have the potential to cause opportunistic disease. To combat these threats, the ocular surface has developed innate and adaptive immune mechanisms (Knop and Knop, 2007). One important component of the innate response is the repertoire of AMPs which can be considered to represent the eukaryotic analogues of antibiotics (Gordon et al., 2005b, Sang and Blecha, 2008). At the OS, hBD1-3 and 9, LEAP1- 2, LL37 (McIntosh et al., 2005), and RNase7 (Mohammed et al., 2010b) are the main AMPs.

Acanthamoeba is a ubiquitous free-living genus of amoeba that can survive in diverse conditions. The life cycle of *Acanthamoeba* has two stages: a replicative trophozoite stage that under adverse conditions such as extreme temperature, starvation, or osmolarity changes can develop into a dormant cyst stage (Cordingley et al., 1996, Jaison et al., 1998). *Acanthamoeba* is notorious as a cause of serious corneal infection particularly amongst wearers of soft CL. The infection is sporadic but two outbreaks have been recently reported in Chicago and Singapore (Por et al., 2009, Joslin et al., 2006). The mechanism by which this infection occurs is directly related to the ability of *Acanthamoeba* trophozoites to adhere to mannose glycoproteins on the corneal epithelium via the amoeba's mannose-binding receptor (Yang et al., 1997, Hurt et al., 2003, Cao et al., 1998). This binding induces production of a cytolytic factor, mannose-induced protein (MIP133), by the *Acanthamoeba* (Clarke et al., 2006). Subsequently, a number of matrix metalloproteases are activated, killing corneal epithelial cells, and penetrating the cornea by dissolution of the basement membrane and the underlying collagen of the Bowman's zone and stroma (Mitra et al., 1995, Mitro et al., 1994, Cao et al., 1998).

Although there are several studies on the gene expression of AMPs in OS cells challenged with microbial stimuli, there is no work on AMPs expression by any human cell type in response to *Acanthamoeba*. In this study, I characterized the profile of AMPs gene expression by a human corneal epithelial cells exposed to one of the most frequently

isolated species of *Acanthamoeba* from corneal infections; *Acanthamoeba castellanii* (Omana-Molina et al., 2010).

2.2 METHODS

This study was conducted in collaboration with prof Norjahan Penjwani in New England Eye Centre, Tufts University School of Medicine, Boston, Massachusetts, USA. The cellular stimulation with *Acanthamoeba castellanii* was performed in the USA whereas the gene profile of the studied AMPs was analyzed at our department in Nottingham.

Aseptic conditions were applied in all *in vitro* experiments. The laminar flow air hood and sterile solutions and containers were used at all times.

2.2.1 Human cell culture

According to previously described protocols (Gipson et al., 2003), the Telomerase reverse transcriptase-immortalized human corneal limbal epithelial cells (HCLE) were maintained in keratinocyte serum-free media (K-SFM; Invitrogen, Carlsbad, CA) supplemented with 0.2 ng/ml epidermal growth factor (EGF), 25 µg/ml bovine pituitary extract (BPE) and 0.4 mM CaCl₂ at 37 °C in a 5% CO₂ humidified incubator. The HCLE were sub-cultured in 6-well cell culture plates (9.5 cm²; BD, Franklin Lakes, NJ) until confluency was reached and then starved overnight in growth supplement and BPE free media before exposure to *Acanthamoeba*.

2.2.2 Isolation and culture of *Acanthamoeba castellanii* trophozoites

Acanthamoeba castellanii trophozoites: An *Acanthamoeba* strain derived from an infected human cornea (MEEI 0184; *A. Castellanii*, genotype T4) was used throughout this study. The parasites were axenically cultured in a proteose peptone-yeast extract-glucose (PYG) medium prior to the exposure study (Jensen et al., 1970).

2.2.3 *Acanthamoeba* exposure of HCLE

The final density of the *Acanthamoeba* used was 2×10^5 amoebae/ ml. 1.5 ml of amoebae suspension was used for each 60 mm dish. Amoeba from PYG media were washed and suspended in the following media: [1 ml of Non-essential amino acid, 10 ml of 4% BSA and 89 ml of Eagle's minimal essential medium, (EMEM) with L-Glutamine] prior to stimulating HCLE cells. The confluent HCLE cells were incubated with *Acanthamoeba castellanii* trophozoites and samples were collected at 1, 3, 6 and 9 and 24 hours. Control samples were obtained from non stimulated HCLE. At each time point, the culture media was removed and 700 μ l of RLT buffer (Qiagen, USA) was added to each well for 15 minutes until the cells were fully solubilised and the lysate was collected and stored at -80°C . Additionally, the suspension of *Acanthamoeba* culture (without cells) was collected separately and spun down for 2 minutes at 134000 g. Then, 700 μ l of RLT buffer (Qiagen) was added and the samples were kept at -80°C for further analysis. All

tests were done in triplicate and each of the triplicate set of tests was on cells of the same passage.

2.2.4 Isolation of total RNA

Total RNA was extracted from each RLT lysate using RNeasy minikit (Qiagen, Crawley, UK) according to the manufacturer's instructions. Briefly, cell lysates were homogenised with a spin column (QIAshredder; Qiagen) and mixed with 70% ethanol in equal volume (1:1). The mixture was then applied onto spin columns and centrifuged for 15 seconds at 134000 g. The filtrate was discarded, and the spin column was washed with buffer RW1 (Qiagen) and then with buffer RPE (Qiagen) by centrifugation. Total RNA was eluted in 15 µl of RNase-free water (Qiagen) and quantified using the Nanodrop Spectrophotometer (Thermo Fisher Scientific, USA).

The Nanodrop measures the absorbance of the UV light of the RNA sample at 260nm (A260) to determine its concentration. After calibrating and blanking the machine with 1µL RNase-free water, the UV absorption of 1µL of each RNA sample was measured. In principal, the UV absorbance at A260 is specific to RNA and DNA, while the absorbance at A280 is mainly due to the protein absorption. A value of about 2 of the A260/A280 ratio was always sought to define the pure RNA (Fleige and Pfaffl, 2006).

2.2.5 Complementary DNA (cDNA) synthesis

Reverse transcription into cDNA of 4 µg template RNA was carried out according to the manufacturer's instructions (Quantitect Reverse Transcription kit, Qiagen, Crawley, UK). The reaction was performed using a reverse transcription kit (Qiagen). Briefly, total purified RNA was mixed with genomic DNA wipeout buffer (Qiagen) on ice. The mixture was incubated at 42°C for 3 minutes on a thermal cycler (Hybaid Ltd, UK) and then placed on ice. The reverse transcription enzyme mix (Quantitect reverse transcriptase, Quantitect RT buffer, and RT primer mix; Qiagen) was prepared on ice and mixed with total RNA mixture. The final mixture was then incubated on a thermal cycler at 42°C for 30 minutes, followed by reverse transcriptase deactivation at 95°C for 3 minutes. DNA Samples were then stored at 20°C until further analysis. In each experiment, one sample without reverse transcriptase was prepared to act as a negative control.

2.2.6 Quantitative real-time PCR

2.2.6.1 Basics of RT-PCR (Taqman assay)

Quantitative real-time PCR is an extremely sensitive technique which can amplify and simultaneously quantify a specific DNA molecule. It follows the same principle of the standard PCR but it is considered much more sensitive. Indeed, it can detect the products during the reaction progression in real time manner not at the end of the reaction (like the standard PCR). Also, it is rapid and able to detect and

quantify very small amounts of specific nucleic acid sequences. In this regard, *Taqman* assays are very sensitive, specific and highly reproducible (Bustin 2000; Kuhne and Oschmann 2002). A *Taqman* probe consists of fluorophores dyes which are designed to anneal to the specific target DNA. Before the attachment of the probe to the template DNA, the **quencher** fluorophore reduces the fluorescence from the **reporter** fluorophore. Once the *Taqman* probe has attached to its specific piece of the template DNA after the high temperature denaturation, the reaction cools and the primers anneal to the DNA. Then, the **Taq** polymerase begins to add nucleotides and removes the *Taqman* probe from the template DNA (figure 1). This causes separation of the quencher from the reporter fluorophores. Subsequently, the reporter fluorophore emits its energy which can be quantified using a computer. The amount of energy in each cycle is directly proportional to the amount of genetic product generated in that cycle (Biosystems, 2009).

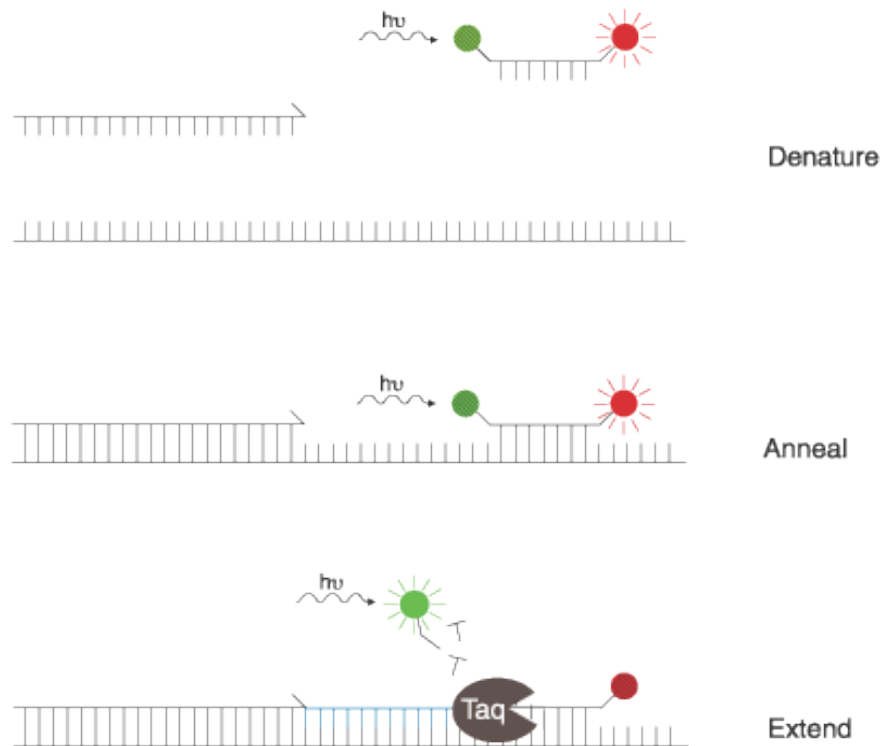


Figure 1. Another three step view of the TaqMan probe working: before the probe is met with the Taq polymerase, energy is transferred from a short-wavelength fluorophore (green) to a long-wavelength fluorophore (red). When the polymerase adds nucleotides to the template strand, it releases the short-wavelength fluorophore, making it detectable and the long-wavelength undetectable (Department of Biology, 2003).

2.2.6.2 RT-PCR set up

RT-PCR based on *Taqman* assays (Applied Biosystems, UK) was used to measure the relative gene expression of the human hBD1-3 & 9, LEAP1-2, LL37, RNase7 according to established methodologies in our department (Abedin et al., 2008, Mohammed et al., 2010a, Mohammed et al., 2010b).

All samples were kept on a cold tray to ensure no nucleic acids damage. Pre-optimised *Taqman* gene expression assays (Applied

Biosystems) were used in this study. All RT-PCR reactions were run on 96 well optical tubes (Stratagene, Europe) in the Mx3005p real-time PCR system (Stratagene, Europe). For each sample, the RT-PCR experimental setup was carried out as detailed in the manufacturer's protocol (Applied Biosystems). Briefly, template cDNA was diluted to 1:5 using nuclease-free water. Each reaction was prepared to 20 μ L final reaction volume with 10 μ L of 2 \times gene expression master mix, 1 μ L of 20 \times assay (primers and probe mix; *TaqMan*; Applied Biosystems), 5 μ L diluted cDNA, and 4 μ L nuclease-free water. Each 96-well plate was run with the gene of interest and respective endogenous control *Taqman* assay (hypoxanthineguanine phosphoribosyltransferase, HPRT) (Applied Biosystems, UK).

Non-template and non-reverse transcriptase samples were used as negative controls. All experiments were done in triplicate. The thermal profile of the RT-PCR assays is shown in Table 1

Table 1. Thermal cycler profile used in this study. The standard profile consists of three stages (activation, hold and cycle. Data collection was performed at cycle stage).

Thermal Profile of each RT-PCR cycle			
Initial setup/ 1 cycle each		Each of 40 cycles	
		Denature	Anneal/ Extend
Activation	Hold	Cycle	
2 min 50 °C	10 min 95 °C	15 sec 95 °C	1 min 60 °C

Details of the target genes and primer codes used in our study are listed in Table 2.

Table 2. showing detailed information about the genes and primer codes used in our study

Gene Symbol	Taqman assay ID	Accession number
HPRT	4333768F	NM_000194.1
DEFB1/Hs00174765_m1	Defensin, beta1/HBD1	NM_005218.3
DEFB4/Hs00823638_m1	Defensin,beta4/HBD2	NM_004942.2
DEFB103A/Hs00218678_m1	Defensin,beta103A/HBD3	NM_018661.2
CAMP/Hs00189038_m1	Cathelicidin AMP	NM_004345.3
HAMP/Hs00221783_m1	Hepcidin AMP (LEAP 1)	NM_021175.2
LEAP2/Hs00364834_m1	Liver expressed AMP2	NM_052971.2
Hs00261482_m1	RNase7	NM_032572.3
Hs02760065_g1	DEF109	NM_001037380

2.2.6.3 Data analysis:

The raw RT-PCR data were acquired using the MxPro software (version 4.01; Stratagene, UK). Then, it was transported to Microsoft Excel spreadsheet and analysed using the $\Delta\Delta$ CT method (Bustin, 2000). The help of a statistician was sought at all times. The statistical significance was set at $P=0.05$ using the Student's t -test. Data was represented as mean, standard error of the mean (SE) and standard deviation (SD) of two independent experiments performed in triplicate. Prism software 5

(GraphPad Software, San Diego, CA) was used for graphical representation.

2.3 RESULTS

AMPs expression in *Acanthamoeba*-exposed HCLE showed a statistically significant up-regulation in 7 of the 8 studied AMPs.

HBD1 was the only AMP which showed variable decrease in the gene expression. It showed reduced expression at all time points with the down-regulation at the 6 hour time point (0.6 fold) reaching statistical significance ($P=0.038$, figure 2A). HBD2 gene expression gradually increased with a dramatic and significant four folds increase at 9 hours ($P=0.036$, figure 2B).

HBD3 gene expression showed a significant up-regulation at 3, 6, and 9 hours (7 folds, 7.5 folds, and 10 folds, respectively) ($P= 0.044$, $P=0.00050$, $P=0.017$ respectively, figure 2C).

HBD9 gene showed a trend towards decreased expression for the first 6 hours but this did not reach statistical significance. It increased and reached a significantly higher level at the 9 hour time point (1.5 fold, $p=0.002$, figure 2D)

LL37 gene expression varied slightly over the time course with a slight but significant increase at the 9 hours time point ($p=0.003$, figure 2E)

LEAP1 gene expression was variable at the earlier time points but was significantly unregulated at 9 hours (5 folds increase, $p=0.001$, figure 2F).

LEAP2 gene expression showed a significant down regulation at the 3 hours time point ($p=0.002$, figure 2G) and then a statistically significant up-regulation at 6 and 9 hours (2 and 3.5 folds increase, $p=0.033$ and 0.0001 respectively, figure 2G).

RNase7 gene expression showed significant up-regulation at all time points; figure 2H), with the highest expression of 3.5 fold at 9 hours ($p=0.006$, figure 2H).

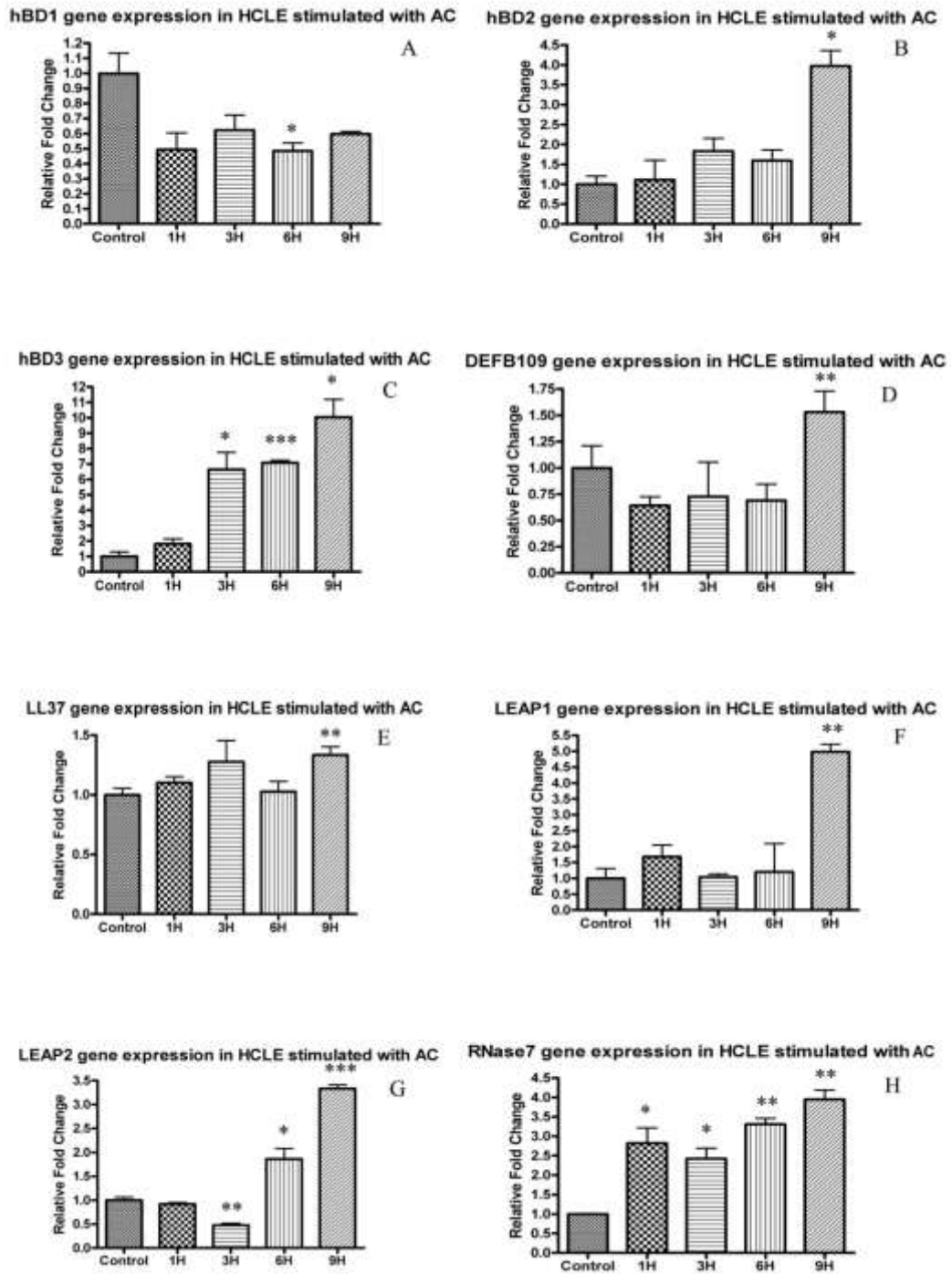


Figure 2 The AMPs gene expression in HCLE stimulated with *Acanthamoeba castellanii*. (AC: *Acanthamoeba castellanii*, DEFB109: hBD9) (*p value is less than 0.05, **p value is less than 0.01, ***p value is less than 0.001).

In samples collected at 24 hours, all the HCLEs were lysed and meaningful information could be obtained by RT-PCR.

Quantitative RT-PCR of cDNA obtained from lysate of *Acanthamoeba castellanii* maintained in culture for up to 24 hours did not show any AMP expression.

2.4 DISCUSSION

AMPs are a component of the innate immune defence and as such respond early to any external challenge with microbes. These responses are known to occur within a few hours of the microbe interacting mainly with the toll like receptors of the surface cells (Ueta and Kinoshita, 2009). Hence I decided to study the responses in the early time points following infection (most host cells had lysed when extending the time course study to 24 hours and meaningful information could not be obtained by RT-PCR).

The up-regulation of AMPs and other epithelial-derived components of innate immunity, e.g. inflammatory cytokines, is thought to be a key component of an effective defence against infection at the ocular surface (Hazlett, 2004). AMPs contribute to the host defence by direct action on microbes and also by augmenting other defence pathways via host cell stimulation (Huang et al., 2007a). It is also demonstrated that AMPs can work synergistically with more than one AMP working together in mounting a host defence response. Two or more AMPs acting together may have equally potent antimicrobial effects at smaller

concentrations. This strategy may be a way of overcoming undesirable side effects of AMPs on host cells seen at higher concentrations (McDermott, 2009).

The anti-amoebic effect of specific AMP (Magainins) has been previously established (Schuster and Jacob, 1992, Feldman et al., 1991). Schuster et al showed that Magainin peptide in combination with silver nitrate and/or other antimicrobial agents have *in vitro* activity against *Acanthamoeba trophozoites and cysts* (Schuster and Jacob, 1992). Sacramento et al have recently shown increased permeabilisation of *Acanthamoeba castellanii* with peptides of α -helical or β -sheeted AMPs. Some of these peptides were hydrolysed by *Acanthamoeba* culture supernatants suggesting enzymatic digestion. They suggested use of more specific peptides that are resistant to proteolysis produced by the organism or the combined use of the AMPs with specific protease inhibitors (Sacramento et al., 2009). This study is therefore of relevance as the potential to treat *Acanthamoeba* corneal infections with AMPs has been demonstrated.

This *in vitro* study demonstrated statistically significant up-regulation of 7 AMPs out of 8 studied following interaction of epithelial cells with *Acanthamoeba castellanii*.

HBD3 has independent broad spectrum *in vitro* antimicrobial activity against Gram-negative bacteria, Gram-negative bacteria, fungi and some viruses. This action is least affected by salt found in tear film on the ocular surface compared with the other AMPs (Harder et al., 2001,

Huang et al., 2007a). In this study hBD3 was the most significant, almost doubling the gene expression at three hours and showing a ten fold increase at 9 hours. This AMP had the maximum increased expression of all AMPs studied and the increase also started at an early time point. This was followed by LEAP1, hBD2 and RNase7. At the 9 hour time point hBD3 expression was two and a half times more than hBD2 and RNase7 and two times that of LEAP1. This up-regulation could suggest a specific anti-amoebic role of the hBD3 on the ocular surface.

LEAP1 showed significant up regulation only at the 9 hour time point. This AMP was initially noted for its antimicrobial effects and has been linked to iron metabolism (Pigeon et al., 2001). Its expression was predominantly detected in the liver and to a much lower extent, in the heart. It is now recognized for iron homeostasis and through this mechanism may contribute to the innate immunity by restricting iron availability to microbes (Ganz, 2006) like lactoferrin which is a known constituent of tears (Flanagan and Willcox, 2009). LEAP1 has demonstrable *in vitro* antibacterial activity against Gram-positive and Gram-negative bacteria as well as the yeasts (Krause et al., 2000).

Like LEAP1, hBD2 also showed up-regulation of the gene expression at 9 hours. This AMP's expression is up-regulated by pro-inflammatory cytokines such as TNF- α and IL -1 β (Wang et al., 2003). AT the ocular surface, hBD2 is known to be inducible in response to Gram-positive and Gram-negative bacteria (McDermott, 2009). It has potent

antimicrobial effect against *P. aeruginosa* and *S. aureus* (Huang et al., 2007a).

HBD1 is constitutively expressed on the ocular surface and its expression does not change much with bacterial infection (Huang et al., 2007a, Abedin et al., 2008). In this study, with *Acanthamoeba* too, it showed down-regulation at all time points. This could be explained by the non-inducible nature of this AMP on the ocular surface (McDermott, 2009) which could indicate a limited antimicrobial role of the hBD1 in infectious diseases.

LL37 has good activity against both Gram-negative and Gram-positive bacteria. Additionally, it has antiviral effects when tested *in vitro* (Huang et al., 2007a, Gordon et al., 2005a). However, in response to *Acanthamoeba*, its up-regulation was not as much as has been reported with bacteria and may represent a differential response to protozoan infection.

The expression of hBD9 showed *in vitro* significant up-regulation at 9 hours with variable down-regulation at early stages. Our group has previously shown down-regulation of hBD9 gene expression in patients with *Acanthamoeba* keratitis (Abedin et al., 2008). This down-regulation could be related to the fact that all the patients with *Acanthamoeba* keratitis were CL wearers. Interaction of hydrophilic contact lenses with epithelial cells *in vitro* has demonstrated a down-regulation in expression of hBD2 following exposure to *P. aeruginosa* (Maltseva et al., 2007). Unlike in samples taken from patients' eyes, *in*

in vitro exposure to *Acanthamoeba* showed up-regulation of hBD9 suggesting that expression of this AMP is susceptible to external influences.

LEAP2 showed early down-regulation at 3 hours then up-regulation at 6 and 9 hours, though comparatively less than other AMPs. Although, LEAP2 in chickens is known to have killing activities against *Salmonella* spp and Gram-positive bacteria (Townes et al., 2009). It is well documented that human LEAP2 is not a microbicidal peptide. The secondary structure of this AMP has a negative effect on its antibacterial activity in humans (Hocquellet et al., 2009).

RNase7 exhibits broad spectrum antimicrobial activity *in vitro* against several potentially pathogens like Gram-positive bacteria, Gram-negative bacteria and *Candida albicans*. Furthermore, RNase7 shows extremely high activity against vancomycin-resistant *Enterococcus faecium* (Harder and Schroder, 2002). In our study, RNase7 gene expression revealed remarkable early up-regulation in HCLE in response to *Acanthamoeba castellanii*. This continued to increase gradually. This finding could suggest a possible role of this highly cationic AMP in the anti-amoeba activity.

There was no AMPs gene expression in samples taken from lysate of *Acanthamoeba* alone which confirmed the specificity of the *TaqMan* probes against the human AMPs genes in the HCLE.

This study provides a comprehensive profile of the ocular surface AMP gene expression in response to *A. castellanii* infection. The profile differs

from that seen following bacterial infection and illustrates the differential expression in response to different organisms. Although, further studies of the AMPs' protein expression are required, this study provides the foundation upon which further studies to elucidate anti *Acanthamoeba* activity of specific AMPs. *Acanthamoeba* infection of the cornea is a serious and sight threatening condition with not licensed drug available for its treatment. Dilute disinfectant agents such as PHMB and chlorhexidine (Dart et al., 2009) are employed in a non-specific manner. The potential of using AMPs singly or in combination to combat this infection is a promising avenue for further exploration.

CHAPTER THREE

3 Antimicrobial peptide gene expression by ocular surface cells in response to *Pseudomonas aeruginosa* and *Staphylococcus aureus*

3.1 INTRODUCTION

S. aureus and *P. aeruginosa* are common causative organisms of infectious keratitis. In fact, *P. aeruginosa* is the leading cause of bacterial corneal infections associated with extended contact lens wear (Robertson et al., 2007, Willcox and Holden, 2001, Willcox, 2007). Also, *S. aureus* is a commonly isolated bacterium from the corneal infectious infiltrates of people with ocular surface diseases and previous ocular surgery (Willcox, 2010, Vajpayee et al., 2007). The *in vitro* bactericidal activity of the human AMPs (human defensins and LL37) against Gram-negative and positive bacteria is well documented (Huang et al., 2007a, Huang et al., 2007b, Harder et al., 2001, Sang and Blecha, 2008, Garreis et al., 2010a).

Although there are several studies on the gene expression of AMPs in human corneal epithelial cells challenged with microbial stimuli, there are no reports which address differential expression of AMPs in these cells in response to different types of bacteria. The aim of this study was to characterize the profile of AMP gene expression in human OS cells challenged with the Gram-negative bacterium (*P.aeruginosa*) and the Gram-positive bacterium (*S. aureus*).

3.2 METHODS

Aseptic conditions were applied in all *in vitro* work. The laminar flow air hood (Envair, UK) and sterile solutions and containers were used at all times.

3.2.1 Cell culture

Simian virus (SV) 40 immortalized transformed human corneal epithelial cells (HCECs) were a kind gift from Felicity Rose (School of Pharmacy, The University of Nottingham, Nottingham, UK). These cells were originally obtained from immortalisation of primary corneal epithelial cells following infection with recombinant SV40-adenovirus vector (Araki-Sasaki et al., 1995).

The cells were maintained in cell culture medium (Epilife; Cascade Biologics, Paisley, UK) containing human keratinocyte growth supplement (HKGS; Cascade Biologics), antibiotic mixture (gentamicin and amphotericin B; Cascade Biologics), and anti-mycoplasma agent (Plasmocin; Invivogen, Europe). The HCECs were then plated onto 12-

well culture plates and grown until they reached 70- 90% confluence in humidified conditions (5% CO₂, 37°C). The cellular confluency and health was checked by phase contrast microscopy (Nikon Eclipse TS100, Japan) (figure 3).

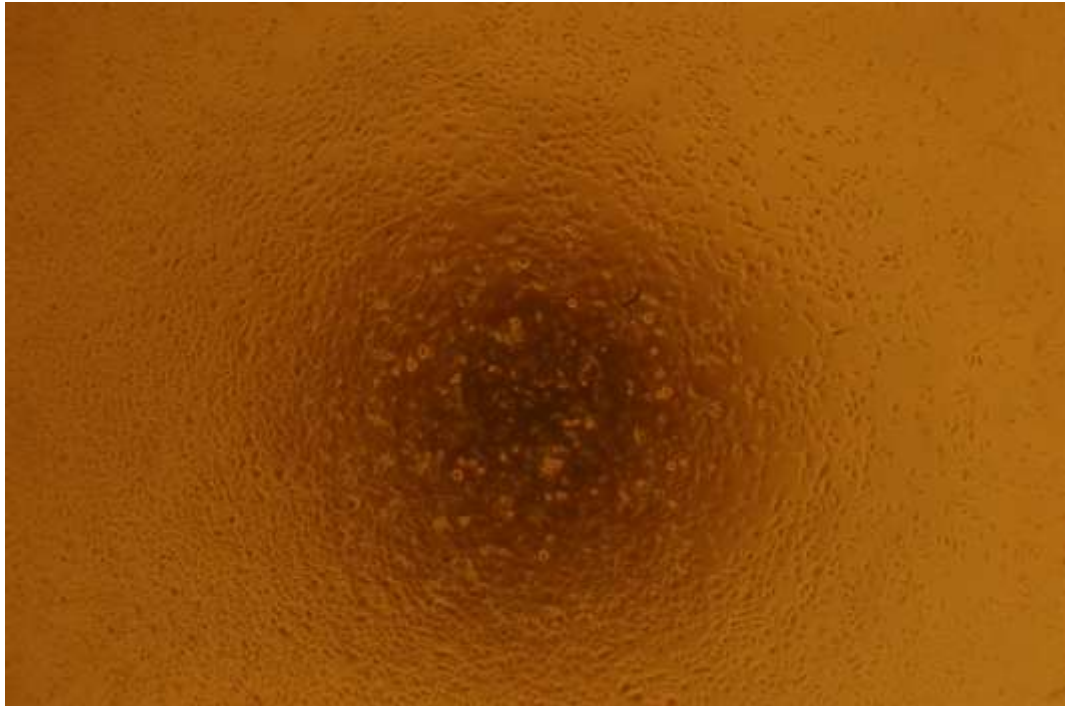

Figure 3. Healthy HCECs with 70% confluence under the microscope

Upon reaching 70-90% confluency, HCECs were passaged. The incubating medium was removed and cells were incubated with 5mL of TrypLE Express (Invitrogen, UK) for 5 minutes at 37°C to detach. Then HCECs were centrifuged for 5 minutes at 250g. The formed cellular pellet was then re-suspended in fresh supplemented Epilife medium and split appropriately. In this study, cellular passages 8-14 were used. Before bacterial exposure, HCECs were starved overnight in HKGS-free media.

3.2.2 Bacterial exposure/ stimulation of HCECs

P. aeruginosa and *S. aureus* derived from pathogenic human ocular isolates were used in this study (Kindly obtained from the Microbiology department of the Queens Medical Centre, Nottingham). The bacteria were cultured in a blood agar media prior to the stimulation studies and were then stored in a 1:1 mixture of Brain-Heart Infusion Broth (BHIB) and glycerol in -80°C . Prior to experimentation, bacteria were inoculated onto blood agar plates and incubated for overnight at 37°C with 5% CO_2 . Bacteria were then grown in BHIB medium in the orbital shaker overnight at 37°C . After 24 hours, 5 ml of the culture was centrifuged at $112 \times g$ for 15 minutes and, after washing with PBS, the pellet was re-suspended in 10 ML of Epilife by vigorous vortex mixing and the optical density of the bacterial suspension was measured at 620 nm and normalised to 0.2 by dilution in Epilife. The cytotoxic effects of serial dilutions of the bacterial suspension on HCECs were assessed microscopically. With both bacterial isolates, dilutions of 1:8 or higher were found to have no observable effects on cell morphology after 24 h of incubation. Henceforth, a 1:10 dilution of the suspension was used to challenge HCECs. The colony forming units (CFU) of each suspension were determined retrospectively by plate count to be 1.3×10^7 and 2.1×10^7 CFU for *S. aureus* and *P. aeruginosa*, respectively. Subsequently, confluent HCECs were incubated with 1.5 ml of *P. aeruginosa* or *S. aureus* suspensions and samples of HCECs were collected at 1, 3, 6 and 9 hours. Control samples were obtained from

non-stimulated HCECs. At each time point, the culture media was removed and 700 µl of RLT buffer (Qiagen) was added to each well for 15 minutes until the cells were fully solubilised and the lysate was collected and stored at -80° C. Also, the supernatant suspension of *P. aeruginosa* and *S. aureus* (without HCEC cells) were collected separately and centrifuged for 2 mins at 287 × *g*. 700 µl of RLT buffer (Qiagen) was added and the samples were kept at -80° C for further analysis. All tests were done in triplicate with cells at the same cell passage number.

3.2.3 Isolation of total RNA and cDNA synthesis.

Total RNA was extracted from RLT lysate using the RNeasy Mini kit. Furthermore, reverse transcription into cDNA of 4 µg of template RNA was carried out. A comprehensive description of the used protocol has been mentioned in details in **Chapter two**.

3.2.4 Quantitative RT-PCR

RT-PCR analysis was performed to measure the relative gene expression of the following AMPs: hBD1-3 and 9, LL37, LEAP1 and 2 and RNase7. Detailed description of the RT-PCR protocol has been mentioned in **Chapter two**.

3.3 RESULTS

3.3.1 Modulation of AMPs gene expression in HCEC cells in response to challenge with *P. aeruginosa*:

AMPs gene expression in HCECs stimulated with *P. aeruginosa* showed a statistically significant up-regulation in 5 of the 8 AMPs targeted in this study (figure 4). Only hBD9 and LEAP1 showed early and significant decreases in gene expression. Indeed, hBD9 was significantly down-regulated at 1 and 3 hours (figure 4D), whereas LEAP1 showed statistically significant decreases at all time points (figure 4F). While the gene expression of LEAP2 was variably increased (figure 4G), the mRNA level of hBD1, hBD2, hBD3, RNase7 and LL37 was significantly up-regulated, with LL37 reaching 10-fold increase at 6 hours (figure 4E).

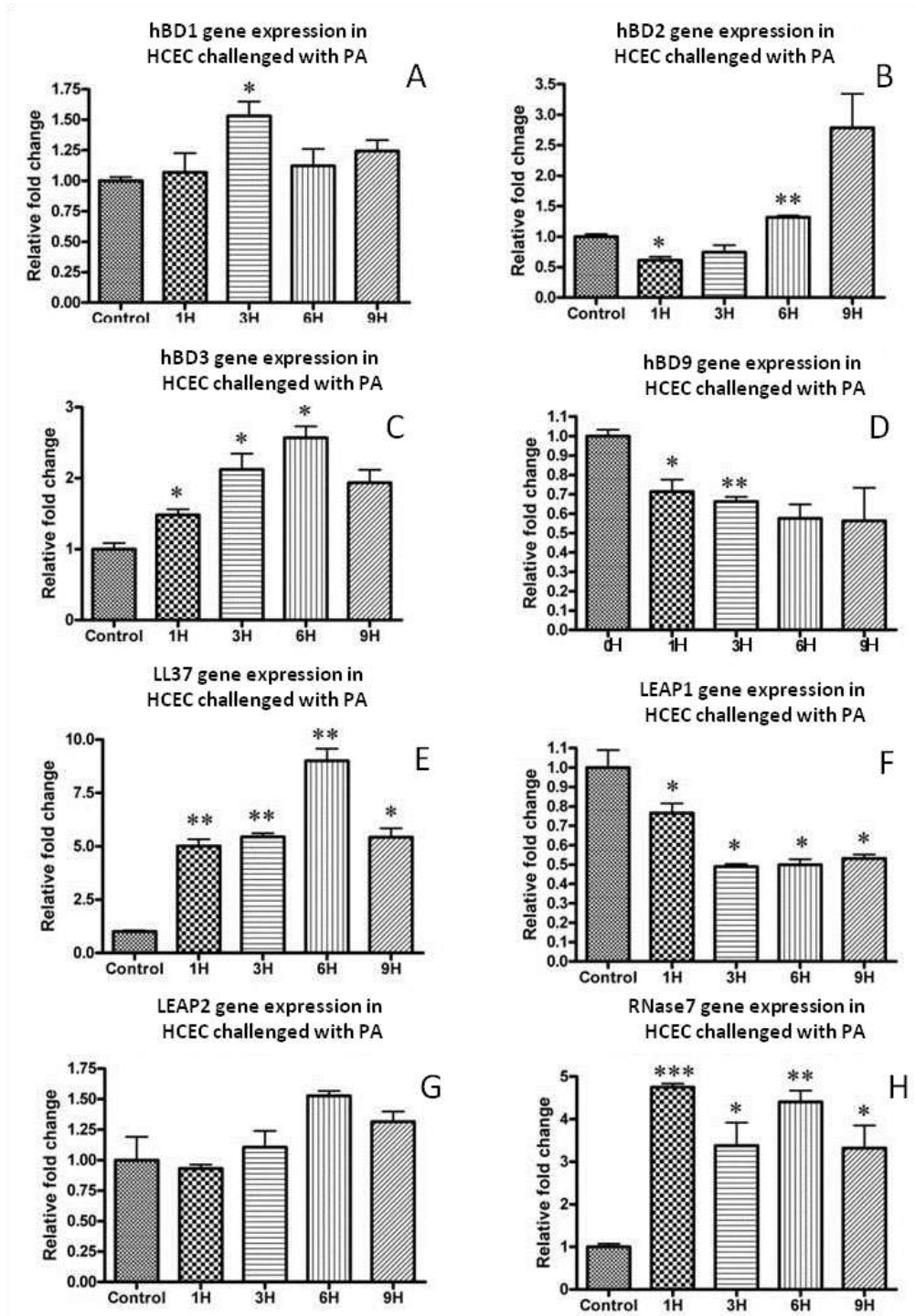


Figure 4. AMP gene profile in HCEC challenged with *Pseudomonas aeruginosa*. PA: *Pseudomonas aeruginosa*, hBD: human beta defensin, LL37: human cathelicidin, LEAP: Liver expressed antimicrobial peptide, RNase7: Ribonuclease 7. X axis shows time points in hours (H). (*p value is less than 0.05, **p value is less than 0.01, ***p value is less than 0.001)

3.3.2 Modulation of AMPs gene expression in HCEC cells in response to challenge with *S. aureus*:

Each of the studied AMPs showed an overall up-regulation but only hBD3, LL37, LEAP2 and RNse7 reached statistical significance at 6, 1, 6 and 6 hour, respectively (figures 5C, 5E, 5G and 5H, respectively). Although it was not statistically significant, only the mRNA of hBD9 showed an immediate increase at 1 hour followed by a gradual decline thereafter (figure 5D).

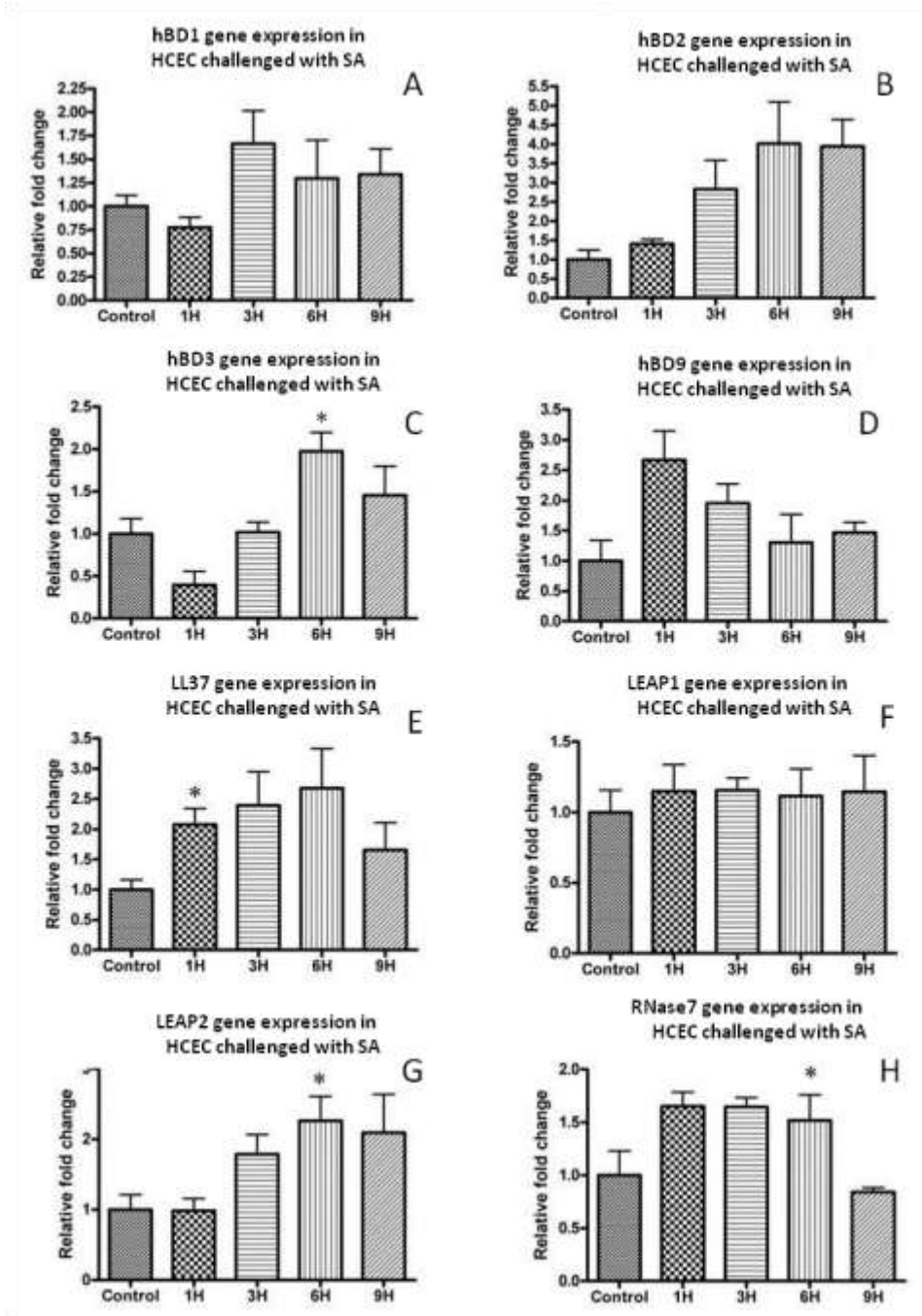


Figure 5. AMP gene expression in HCECs challenged with *Staphylococcus aureus*. SA: *Staphylococcus aureus*, hBD: human beta defensin, LL37: human cathelicidin, LEAP: Liver expressed antimicrobial peptide, RNase7: Ribonuclease 7. X axis shows time points in hours (H). (*p value is less than 0.05, **p value is less than 0.01, ***p value is less than 0.001)

For all samples, RT-PCR did not detect a product when reverse transcriptase was not used during cDNA synthesis thus excluding primer binding to genomic DNA and confirming the specific amplification of only cDNA (negative control). Similarly, no products were generated during negative control RT-PCR reactions of cDNA obtained from lysates of *P. aeruginosa*, or *S. aureus* maintained in culture for 24 hours in the absence of HCECs.

3.4 DISCUSSION

At the OS, AMPs form a main component of the innate immune system and play a role in protecting the ocular surface from environmental challenges besides bridging the innate and adaptive immune systems. Interactions between pathogen-associated molecular pattern molecules (PAMPs) and host cell pattern recognition receptors (PRRs) such as the toll like receptors (TLRs) are considered to be the first step in initiating the production of cytokines, other stimulatory factors and AMPs, thus initiating innate and adaptive immunity (Mogensen, 2009, Janeway and Medzhitov, 2002). At the OS, AMPs are mainly secreted from corneal and conjunctival epithelial cells and the neutrophils. Up-regulation of AMPs and inflammatory cytokines is considered to be the key to achieving effective protection against invading microbes at the OS (Hazlett, 2004, Garreis et al., 2010a, Wiesner and Vilcinskas, 2010). AMPs participate in innate defence either through direct microbicidal activity or by augmenting other defence pathways resulting from cellular stimulation (Huang et al., 2007b, McDermott, 2009). More than

one AMP can work synergistically to achieve potent microbicidal activity at lower concentrations than those required for AMPs acting alone. In this way the harmful side effects of AMPs on host cells seen at higher concentrations might be minimised (McDermott, 2009, Cassone and Otvos, 2010).

The AMP response to any external insult or microbial invasion is known to occur at an early stage; typically these responses occur within a few hours of the microbe interacting with the toll like receptors of the surface cells (Ueta and Kinoshita, 2009, McDermott, 2009). Of note, the *in vitro* production of hBD3 in response to bacterial challenge is exceedingly fast and can occur within minutes of exposure (Garreis et al., 2010b).

In chapter two, the profile of ocular AMPs gene expression in an immortalized HCLE challenged with *Acanthamoeba castellanii* was shown. All the studied AMPs (except for hBD1) showed significant up-regulation at a late time point (9 hour) with hBD3 reaching the highest levels (10-fold increase) (Otri et al., 2010). Similar comprehensive information on the profile of AMP expression following exposure to bacterial pathogens is not known. Hence I studied the expression of a range of AMPs by corneal epithelial cells challenged with *P. aeruginosa* and *S. aureus*.

The obtained data in this study showed that all the studied AMPs were constitutively expressed by un-challenged HCEC. The constitutive expression of hBD1-3 (McIntosh et al., 2005, McDermott, 2004), hBD9

(Abedin et al., 2008, Mohammed et al., 2010a), LL37 (McIntosh et al., 2005, McDermott, 2004), LEAP 1 & 2 (McIntosh et al., 2005) and RNase7 (Mohammed et al., 2010b) in OS cells has been previously reported. However, the inducible nature of the hBD3 production has also been reported by McIntosh *et al* who detected a greater percentage of hBD3 in OS cultures taken from infected corneas than in those from healthy corneas (McIntosh et al., 2005). Moreover, hBD2 expression was also found to be inducible by conditions mimicking injury, inflammation and in response to bacterial products (Gordon et al., 2005b, Narayanan et al., 2003, McDermott et al., 2001, McDermott et al., 2003, Haynes et al., 1999).

This study showed an overall up-regulation of 6/8 and 8/8 of the studied AMPs following HCEC challenge with *P. aeruginosa* and *S. aureus*, respectively. This increase was statistically significant in 5 AMPs for *P. aeruginosa* treated cells group and in 4 AMPs for *S. aureus*-treated cells. LL37 and hBD2 showed the highest levels of up-regulation in both groups, with 9- and 4- fold increases, respectively. The expression profiles of the AMPs that were up-regulated were largely similar but not identical in cells treated with the two microbes, suggesting that the cell response is in part specific for the invading organism. This may reflect the different spectrum of PAMPs present on Gram-negative and Gram-positive bacteria (Mogensen, 2009).

HBD1 was up-regulated in the both the *P. aeruginosa* and *S. aureus* groups reaching statistical significance only in the *P. aeruginosa*

category at the 3 hour time point. Notably, the expression of this gene was modest, which is in line with the findings of others. It has been reported that hBD1 is constitutively expressed at the ocular surface and its expression does not change much with bacterial infection (Huang et al., 2007a, Abedin et al., 2008, McDermott, 2009). Moreover, Yuan et al. have demonstrated the initial down-regulation of hBD1 at the murine OS with fungal keratitis. (Yuan et al., 2010) The relative lack of responsiveness of hBD1 gene expression to the bacterial pathogens is perhaps not surprising as it has been reported to have only modest antimicrobial activity against *P. aeruginosa* and no activity was detected against *S. aureus* (Huang et al., 2007a).

At the ocular surface, hBD2 has been known to be inducible in response to bacterial infections (Harder et al., 1997) and HCECs have been shown to up-regulate hBD2 in response to *S. aureus* or its exoproducts in a TLR2-dependant manner (Kumar et al., 2006) or in response to infection with *P. aeruginosa* (Kumar et al., 2007b, Garreis et al., 2010b). It is also up-regulated by pro-inflammatory cytokines such as TNF- α and IL -1 β (Wang et al., 2003, Haynes et al., 1999). According to this study, the gene levels of hBD2 showed overall increase in response to both microbes, which was statistically significant only in the *P. aeruginosa* group. In accordance with this finding, it has been previously reported that hBD2 has only good anti-bacterial activity against *P. aeruginosa* with weak activity against *S. aureus* strains (Huang et al., 2007a). However, Garreis has found that supernatants of

P. aeruginosa and *S. aureus* have significantly up-regulated hBD2 expression in corneal epithelial cells (Garreis et al., 2010b).

HBD3 showed gradual but significant increase in gene expression in *P. aeruginosa* treated cells reaching its highest levels at 6 hours of 2.5-fold. This gene also showed gradual and significant increase in the *S. aureus* treated cells at 6 hour time point. It is known that bacterial supernatant such as *S. aureus* induces hBD3 expression in corneal epithelial cells suggesting that hBD3 directly participates in innate immune defence (Garreis et al., 2010b). Moreover, hBD3 has independent broad spectrum *in vitro* antimicrobial activity against Gram-negative and Gram-positive bacteria, fungi and some viruses. Indeed, hBD3 has good activity against both *P. aeruginosa* and *S. aureus* supporting its antimicrobial role and indicating an important role in ocular surface defence (Huang et al., 2007a). The action of this AMP is least affected by salt found in tear film on the OS compared with the other AMPs (Dhople et al., 2006, Harder et al., 2001, Huang et al., 2007c, Batoni et al., 2006, Garreis et al.).

When stimulating the corneal epithelial cells with *P. aeruginosa*, hBD9 gene expression showed significant down-regulation at all time points. In *S. aureus* treated cells early up-regulation was observed, which gradually and steadily decreased. Interestingly, our group has previously shown an *ex vivo* down-regulation of hBD9 gene expression in impression cytology samples taken from patients with infectious keratitis and dry eye syndrome (Abedin et al., 2008). Premratanachai

et al have reported the down-regulation of hBD9 after *in vitro* stimulation of gingival keratinocytes with *Candida albicans* (Premratanachai et al., 2004). Recently, an initial increase in hBD9 mRNA levels followed by a significant down-regulation in response to PAMPs and inflammatory cytokines stimulation has also been reported (Mohammed et al., 2010a).

The gene expression of LL37 was significantly increased in all the *P. aeruginosa* and *S. aureus* treated cells, showing the highest levels of up-regulation in HCEC challenged with *P. aeruginosa* (9-fold at 6 hours). Previous studies too have shown LL37 to effectively protect the ocular surface from *P. aeruginosa* infections (Redfern et al., 2011). Indeed, LL37 has *in vitro* bactericidal activity against both Gram-negative and Gram-positive bacteria in addition to its anti-viral effect (Huang et al., 2007a, Gordon et al., 2005a). LL-37 also has a chemotactic effect on leukocytes stimulating inflammation (Befus et al., 1999, Niyonsaba et al., 2001, Mendez-Samperio, 2010). Redfern *et al* have recently reported that the production of LL37 is stimulated by the TLR agonists which may play a role in providing the ocular surface with direct defence against various pathogens and stimulating the innate and adaptive immunities through the immune and inflammatory activities (Redfern et al., 2011, Mendez-Samperio, 2010). Huang *et al* has also reported that LL-37 can induce cellular migration and production of inflammatory mediators following injury or insult to the ocular surface (Huang et al., 2007a, Mendez-Samperio, 2010).

The expression of the LEAP1 gene was significantly down-regulated in *P. aeruginosa*-treated cells but did not change in *S. aureus*-treated cells. LEAP1 has demonstrable *in vitro* antibacterial activity against Gram-positive, Gram-negative bacteria and yeasts (Krause et al., 2000). Specifically, it has potent bactericidal effects against both *P. aeruginosa* and *S. aureus*. Its expression was predominantly detected in the liver and to a much lower extent, in the heart (Krause et al., 2000). It is now recognized for its physiological role in iron homeostasis and through this mechanism may contribute to the innate immunity by restricting iron availability to microbes (Ganz, 2006, Pigeon et al., 2001). At the ocular surface its role as an antibacterial agent may be limited but may have a greater role against virus infections, as reported by Abedin *et al.* (Mohammed et al., 2011)

LEAP2 was up-regulated in all samples but showed a statistical significance only in *S. aureus*-treated cells (though comparatively less than other AMPs). Although, LEAP2 have killing activities against *Salmonella* species and Gram-positive bacteria in chickens (Townes et al., 2009), it is well documented that human LEAP2 lacks microbicidal properties (Hocquellet et al., 2009).

The RNase7 gene showed early, consistent and statistically highly significant up-regulation in cells treated with either pathogen, reaching its highest levels in *P. aeruginosa*-treated cells (5 folds at 1 hour). Levels of expression remained elevated throughout the 9-hour experimental period in *P. aeruginosa*-treated cells, but fell back to close

to untreated levels by 9 hours in *S. aureus*-treated cells. RNase7 exhibits broad spectrum antimicrobial activity *in vitro* against Gram-positive bacteria including *S. aureus*, Gram-negative bacteria including *P. aeruginosa*, and the yeast *Candida albicans* (Harder and Schroder, 2002). Notably, RNase7 shows extremely high activity against vancomycin-resistant *Enterococcus faecium* (Harder and Schroder, 2002, Torrent et al.). The constitutive presence of RNase-7 (both protein and mRNA) on human ocular surface was previously reported by our group. This expression was increased in response to IL-1 β , suggesting an active role during inflammation related to ocular surface infection (Mohammed et al., 2010b). Reithmayer and co-workers detected increased levels of RNase7 in normal human scalp skin treated with LPS of *P. aeruginosa* or *Escherichia coli*, lipoteichoic acid (LTA) from *Streptococcus pyogenes* or flagellin (Reithmayer et al., 2009).

This study provides a comprehensive profile of the OS AMPs' gene expression in response to important Gram-negative (*P. aeruginosa*) and Gram-positive (*S. aureus*) bacterial pathogens. The differences in the AMP expression profile between these two pathogens illustrates the differential expression in response to different organisms, which is likely to be a reflection of the different PAMPs associated with these pathogens, and their respective PRRs. The potential of using AMPs singly or in combination to combat ocular infections is a promising avenue for further exploration.

CHAPTER FOUR

4 Variable Gene Expression of Human Beta Defensins 3 and 9 at the Human Ocular Surface in Infectious Keratitis.

4.1 INTRODUCTION:

In this chapter the gene expression of hBD3 and 9 in patients with infectious keratitis was studied. Impression cytology (IC) was used as a method in obtaining the OS samples from those patients.

IC is a minimally invasive technique of harvesting the superficial layers of the ocular surface epithelium by the application of specially designed membrane (Singh et al., 2005). It was first described by Egbert et al as a minimally invasive conjunctival biopsy (Egbert et al., 1977). By comparison, conjunctival biopsies destroy much of the morphological information whereas cellulose acetate filter paper preserves its morphology and permits the use of histological techniques. Practically, impression cytology refers to the application of a piece of biologically inert nitrocellulose membranes containing a small amount of cellulose acetate filter over the surface of the eye to get the superficial 2 to 3 layers of the conjunctival or corneal epithelium. The nitrocellulose filter is negatively charged. DNA is negatively charged due to the phosphate

backbone and will not stick to the nitrocellulose on its own, however, any DNA that has been bound by protein (which has positive charge) will bind to the membrane (Helwa and Hoheisel, 2010). Originally, IC has been used for evaluation of the degree of squamous metaplasia and goblet cell numbers in ocular surface diseases such as dry eye, Stevens–Johnson syndrome, pemphigoid, and vitamin A deficiency, and the effect on these of various therapies. It has also been used to demonstrate corneal epithelial abnormalities, including the presence of goblet cells indicating a stem cell deficiency disorder (Dart, 1997). Recently, this technique has undergone a lot of modifications so it can be used to make clinical, molecular and histopathological diagnosis (Thiel et al., 1998, Singh et al., 2005, Tseng, 1985). It has been widely used to evaluate the gene expression of AMPs on the OS by using RT-PCR (Connor et al., 1991, Singh et al., 2005).

HBD9 is a recently discovered AMP at the human OS by our group (Abedin et al., 2008). In contrast to most other AMPs, it showed reduced *ex vivo* gene expression in patients with infectious keratitis and dry eye disease compared to the healthy controls (Abedin et al., 2008). In a previous study, our group showed variable hBD9 gene expression in response to activation of innate immune effectors (Mohammed et al., 2010a). Moreover, in **chapter two**, it was demonstrated that the *in vitro* gene expression of hBD9 was variably down-regulated at early time points and then up-regulated at later time points in human corneal epithelial cells co-cultured with *Acanthamoeba castellanii* (Otri et al., 2010). Also in **chapter three**, hBD9 showed an early and significant

decrease in its mRNA level in HCECs exposed to *P. aeruginosa* whereas it was variable up-regulation and then gradual down-regulation in cells treated with *S. aureus*.

HBD3 has an independent broad spectrum *in vitro* antimicrobial activity (Huang et al., 2007a, Harder et al., 2001). In a **chapter two**, the *in vitro* gene expression of hBD3 was shown to increase about ten fold in HCLE challenged with *Acanthamoeba castellanii*. This increase was the highest among the AMPs studied (Otri et al., 2010). Furthermore, as shown in **chapter three**, its gene expression was significantly up-regulated in OS cells treated with *P. aeruginosa* and *S. aureus*.

Therefore, a conclusion that hBD3 and hBD9 may play significant roles in infection control and onset was drawn. Studying their roles during microbial infection may lead to a further understanding of the mechanisms by which infectious organisms overcome host defences to cause infection. Based on the previous results and to improve the understanding of the hBD9 and hBD3 roles in response to infection or inflammation, I sought to further investigate the *ex vivo* gene expression of these AMPs at the ocular surface. This gene profile was studied in patients with different eye infections before and after treatment compared to healthy controls.

4.2 METHODS

4.2.1 Overview

Human OS specimens were obtained by IC from healthy controls and patients with *Acanthamoeba* and Gram negative and positive bacterial keratitis, both during active infection and after healing (details are mentioned later). The RNA extraction was optimized to improve the RNA yield from impression cytology samples. When good quality RNA and quantity was obtained, the gene expression of hBD3 and 9 was determined using quantitative RT-PCR.

4.2.2 Ethical approval

Research was conducted in accordance with the tenets of the Declaration of Helsinki. Local ethics committee and National Health Service Trust had approved all research (reference number: OY100201).

4.2.3 Impression cytology samples collection

Following due consent from patients, impression cytology samples were collected from healthy controls and patients with infectious keratitis during the acute fresh infection and 2-3 weeks after of complete healing. This was defined by complete resolution of the clinical infection and inflammation which correlates with complete cessation of any antibiotic treatment (clinical details of the studied samples are mentioned later). Briefly, the cellulose ester filter of pore size 0.45 μm was used (Millipore Corporation, Bedford, MA). Each filter disc with a

diameter of 13 mm was cut into two halves which were applied to the upper OS under topical anaesthesia (Proxymetacaine hydrochloride 0.5% minims) (Bausch and Lomb, Surrey, UK). The discs were applied to cover the upper bulbar conjunctiva and adjacent limbus and peripheral cornea, at a site distal to the actual ulcer or abscess (when applicable) for 30 seconds and gently peeled off. To obtain the maximum yield of RNA, each area was sampled twice using separate filters applied sequentially to the same site. The second filter allowed us to sample the cells in the deeper layers as well. Cells from both filters were then combined in one tube. The samples were stored in RLT buffer (Qiagen, Crawley, UK) at -80 °C until RNA extraction. Later, after optimizing the RNA extraction, samples were kept in RNA later buffer (Qiagen, Crawley, UK) instead of RLT buffer. The samples were then stored at -80 °C until RNA extraction.

4.2.4 Extraction of total RNA

4.2.4.1 The original method in extracting the RNA

Total RNA was isolated using RNeasy minikit according to the manufacturer's instructions. After thawing out the samples in RLT buffer, the tubes were briefly vortexed and then the filters were removed. The left cellular lysates were homogenized with a QIA-shredder spin column and mixed with 70% ethanol in equal volume (1:1). The mixture was then applied onto spin columns and centrifuged at 21000 g for 15 seconds. The filtrate was discarded, and the spin

column was washed with buffer RW1 and then with buffer RPE by centrifugation. Total RNA was eluted in 12 µl of RNase-free water.

4.2.4.2 The optimized method in extracting the RNA

This method of RNA extraction was used after failing in getting good yields of RNA according to the original method.

Promptly after removing the filter from the ocular surface, it was dipped into a tube with RNA later solution to protect the cellular RNA from degradation. The samples were then stored at -80° degree till further analysis. At the time of RNA extraction, the sample was thawed out on ice, and then the filter was removed and immersed in RLT lysis buffer in a separate tube. The residual RNA later buffer was spun down for 5 minutes at *134000 g*, then the buffer was discarded and a RLT lysis buffer was added to the pallet and kept in a second tube (to preserve the residual cells in the RNA later buffer). The two tubes were left for about 10 minutes and then vortexed for 5 minutes, spun for 30 seconds at *134000 g*. The filter was removed from the first tube and the lysed samples in both tubes were combined together in one tube. The lysates were then homogenized with a QIA-shredder spin column. The rest of the steps of the RNA extraction was performed as mentioned previously using the RNeasy Mini Kit and RNeasy Micro Kit (according to the original method of RNA extraction mentioned before).

4.2.5 RNA quality and quantity control

The ultra violet (UV) light absorbance of the eluted RNA and the contaminants at 280 and 260 nm wavelengths were assessed using the Nanodrop Spectrophotometer (Thermo Fisher Scientific).

For the IC samples, RNA quantity was considered as good when it measured a value of 45 ng/μl or more. Also, good RNA quality was ascertained when the A260/A280 ratio showed a value of more than 1.8 (Fleige and Pfaffl, 2006). These previous readings were established depending on a previous optimization study at our department and based on Weichenhan protocol (http://www.science.ngfn.de/dateien/RNA_quality_and_quantity_control.pdf).

4.2.6 Complementary DNA synthesis

Reverse transcription of 500 ng template RNA into cDNA was carried out according to the manufacturer's instructions (Quantitect Reverse Transcription kit, Qiagen). Using this reverse transcription kit template RNA was mixed with genomic DNA wipeout buffer (Qiagen) on ice, and the volume was adjusted with water. The mixture was incubated at 42°C for 3 minutes on the thermal cycler (Hybaid Ltd). The reaction then was placed on ice. The reverse transcription enzyme mix (Quantitect reverse transcriptase, Quantitect RT buffer, and RT primer mix; Qiagen) was prepared on ice and mixed with total RNA mixture. The final mixture was then incubated on the thermal cycler at 42°C for

30 minutes, followed by reverse transcriptase deactivation at 95°C for 3 minutes. Samples were stored at -20°C until further analysis. The RNA and cDNA in each impression cytology sample were analysed individually and processed for the RT-PCR. In each experiment, one sample without reverse transcriptase was prepared to act as a negative control.

4.2.7 Quantitative real-time polymerase chain reaction (Taqman assay)

As mentioned previously, aseptic conditions were applied while preparing the RT-PCR samples. Quantitative RT-PCR analysis was used to measure the relative gene expression of the human beta defensins 3 and 9 (hBD3 and hBD9) according to the manufacturer's protocol (Applied Biosystems) and to methods established in our department and reported previously (Abedin et al., 2008). Briefly, pre-optimised Taqman gene expression assays (Applied Biosystems) were used to study each defensin gene and the endogenous control (HPRT). RT-PCR reactions were run on a 96-well optical plate (Stratagene) in the Mx3005p real-time PCR system (Stratagene). For each sample, the RT-PCR experimental setup was carried out as detailed in the manufacturer's protocol (Applied Biosystems). Initially, template cDNA was diluted to 1:2 using nuclease-free water to perform the RT-PCR in triplicate. Each reaction was prepared to 20 µL final reaction volume with 10 µL of 2× gene expression master mix, 1 µL of 20× assay (primers and probe mix; TaqMan; Applied Biosystems), 5 µL diluted

cDNA, and 4 μ L nuclease-free water. Appropriate negative (non-template control and reverse transcriptase control) and positive (HPRT) controls were also run in each experiment. Each 96-well plate was run with the gene of interest and respective endogenous control (HPRT). The samples were run in triplicate. Non-template and reverse transcriptase samples were used as negative controls, whereas and HPRT was used as endogenous positive control in each experiment.

The thermal profile of the RT-PCR cycles was previously described in details (in **chapter 2**). Detailed information about the genes used in this study is given in table 1.

Table 3. Details of genes and accession numbers used in the study (Applied Biosystems, Europe)

Gene symbol	Taqman assay ID	Accession number
HPRT	4333768F	NM_000194.1
DEFB103A/Hs00218678_m1	Defensin, beta103A/hBD3	NM_018661.2
Hs02760065_g1	DEFB109 (hBD9)	NM_001037380

4.2.8 Data analysis

The raw RT-PCR data were acquired using the MxPro software (version 4.01; Stratagene, UK) and then transported to an Excel spreadsheet. The help of a statistician was sought at all times. Depending on the $2^{-\Delta\Delta CT}$ formula, the RT-PCR data were statistically analysed. The resultant data was statistically analysed by the Kruskal-Wallis non-parametric statistical analysis test assuming a non-Gaussian distribution of data. Dunn's Test was also used to compare multiple

groups. The statistical significance was set at $p < 0.05$. Prism software 5 (GraphPad Software, San Diego, CA) was used for graphical representation.

4.3 RESULTS

4.3.1 The RNA yield using the original and the optimized methods

During the first year of our study, 123 impression cytology samples (taken from 91 subjects) were analysed (without using the RNA later buffer). There were 74 samples taken from healthy controls and 49 samples obtained from patients with infectious keratitis. All these samples showed poor RNA quantity (less than 45 ng/ μ l) (figure 6). The mean RNA readings were 21 ± 17 ng/ μ l. These samples were all excluded from our RT-PCR analysis.

After using the optimized method in RNA extraction the RNA readings showed a better mean value of 69 ± 59 ng/ μ l (figure 7). A total of 89 impression cytology samples were analysed (29 healthy controls, 31 patients with active infectious keratitis and 29 patients post healing). Of these, only 60 IC samples were processed to RT-PCR analysis (as the others showed low RNA yield) and were included in this study. In details, there were 24 samples taken from healthy controls (as control samples were run with each batch of infected samples, the controls were obtained from the same eight healthy volunteers). Also, 18 samples from 18 patients were collected during different types of active

ocular infection and 18 further samples from the same patients after complete healing. Five samples (2 *Acanthamoeba* keratitis, 2 gram negative [1 *Kleibsell*a spp., 1 *P. aeruginosa*], and 1 gram positive [*S. aureus*] bacterial infections) were excluded from the study due to poor post-treatment RNA yields. Details are provided in table 4.

All samples included in this study showed good RNA quantity (more than 45 ng/ μ l) and quality (A260/A280 ratio of about 2) (figure 7).

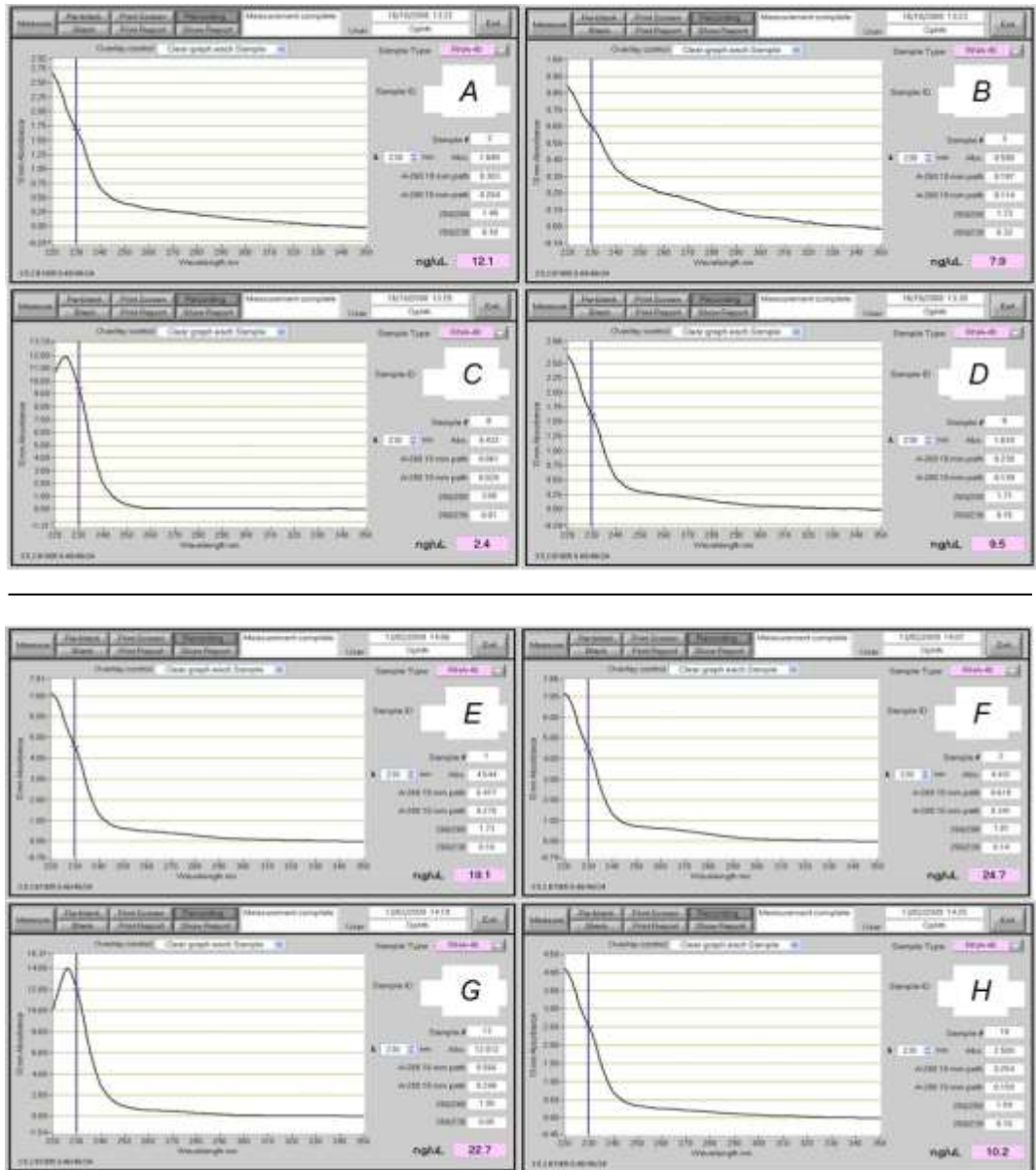


Figure 6. Poor samples of extracted RNA using the original method of RNA extraction

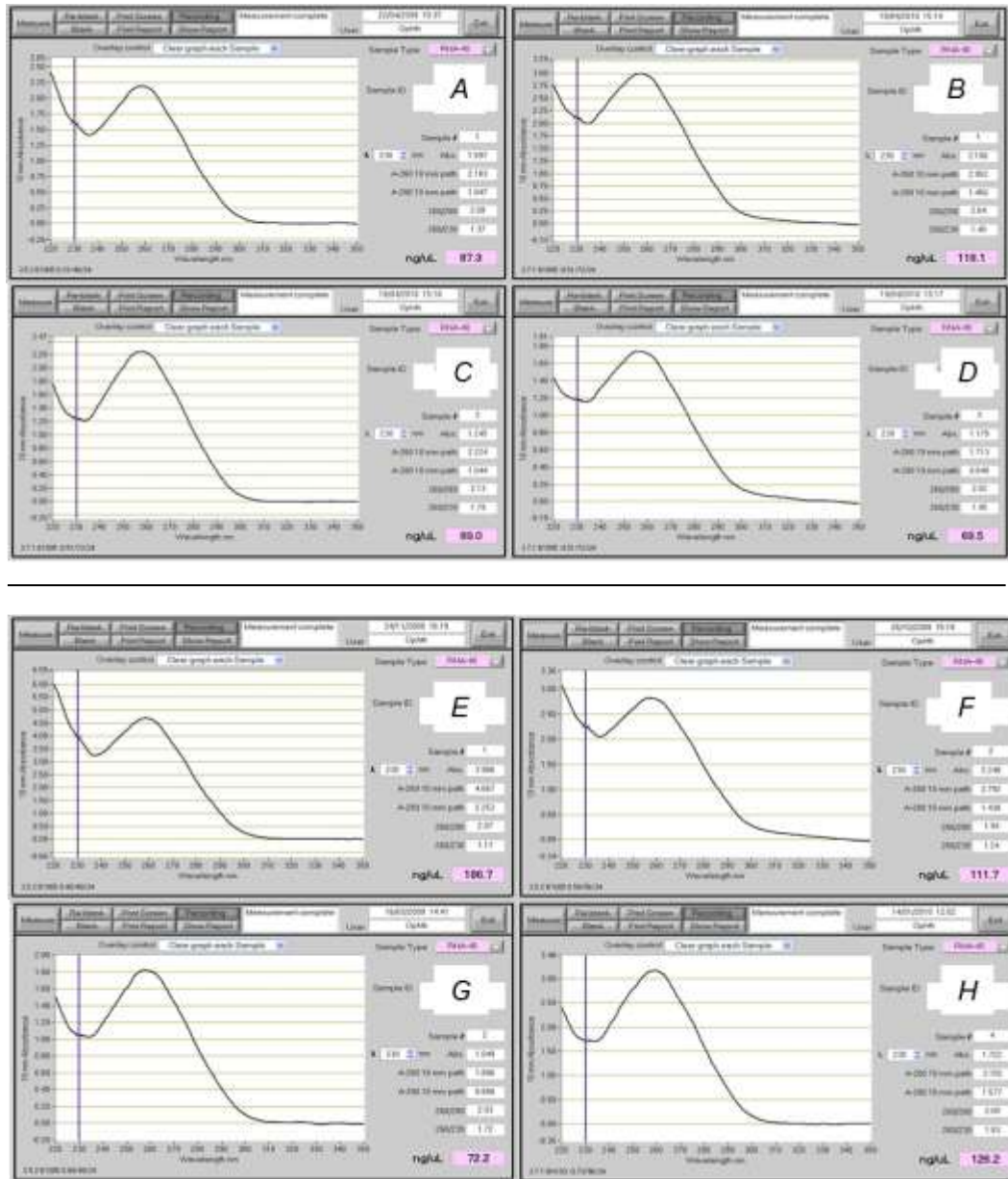


Figure 7. Good samples of extracted RNA using the optimized RNA extraction method

4.3.2 Disease diagnosis

Disease diagnosis was validated by microbiological examination of the corneal scrapings in all cases; except for 3 cases of *Acanthamoeba* keratitis, where the diagnosis was based on the clinical manifestations

and distinct double wall cysts on *in vivo* confocal microscope (IVCM) as has been previously reported (Alomar et al., 2009). Details of the isolated organisms are elaborated in table 4.

Table 4. Causative organisms and number of impression cytology samples taken in each group. Spp: species. IVCM: in vivo confocal microscopy. Figures in parentheses in middle column are the number where RNA yield was sufficient for analysis.

Diagnosis	During Active infection	After complete healing	Healthy Controls
<i>Acanthamoeba</i>	7 (4 culture positive 3 IVCM)	7 (5)	8
Gram-negative bacteria	6 (3 <i>Pseudomonas aeruginosa</i> 1 <i>Haemophilus influenzae</i> , 1 <i>Moraxella</i> spp 1 <i>Kleibsellia</i> spp)	6 (4)	8
Gram-positive bacteria	5 (3 <i>Staphylococcus aureus</i> 2 <i>Pneumococcus</i> spp.)	5 (4)	8

4.3.3 Gene analysis

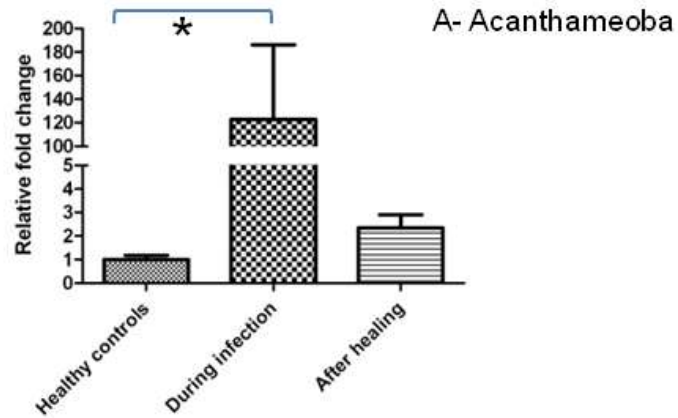
RT-PCR analysis was carried out for hBD3 and hBD9 expression in a total of 24 samples from healthy controls 18 samples from active keratitis and 13 samples post healing (after excluding 5 cases with low RNA yield).

4.3.3.1 Relative gene expression of hBD3

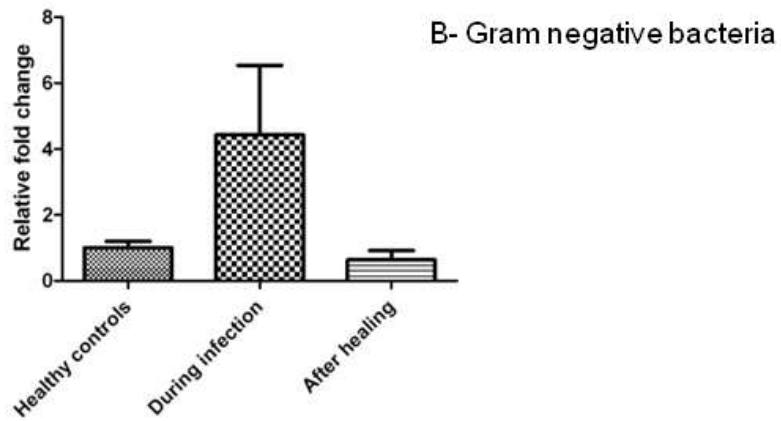
HBD3 showed low level of gene expression in all normal control subjects. Its expression was up-regulated during all types of acute infectious keratitis. This was significantly increased compared to

controls ($P < 0.05$) during acute *Acanthamoeba* keratitis (about 120 fold) and returned to almost the level of the control after healing (figure 8A). Although it was not statistically significant, there was an overall 4 and 10 fold increase in the gene expression of hBD3 during Gram negative and positive bacterial keratitis, respectively. This expression showed down-regulation following treatment (which was significant in gram positive bacterial infection). Expression almost returned to the initial level of healthy subjects after healing of gram negative bacterial keratitis (figure 8B). Interestingly, the gene expression of hBD3 showed significant further reduction compared to levels in healthy controls after treatment of Gram positive infection (figure 8C).

N= 8 healthy controls, N= 7 acute infection
and N= 5 post healing



N= 8 healthy controls, N= 6 acute infection
and N= 4 post healing



N= 8 healthy controls, N= 5 acute infection
and N= 4 post healing

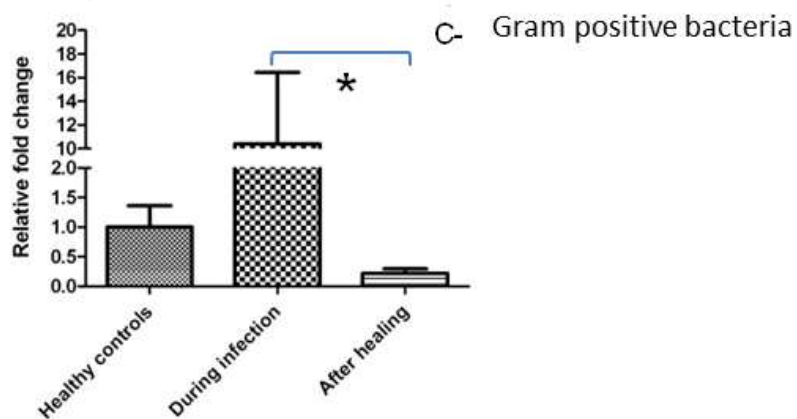
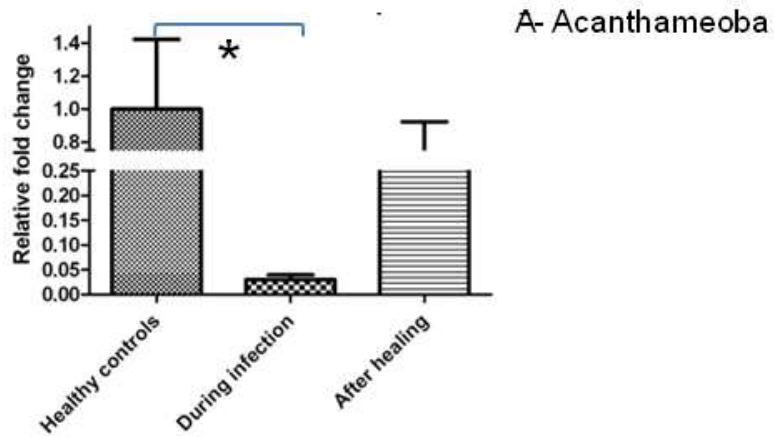


Figure 8. Relative gene expression of hBD3 in impression cytology samples taken from patients with *Acanthamoeba* keratitis, Gram negative and positive bacterial keratitis compared to healthy controls. (* = p value is less than 0.05)

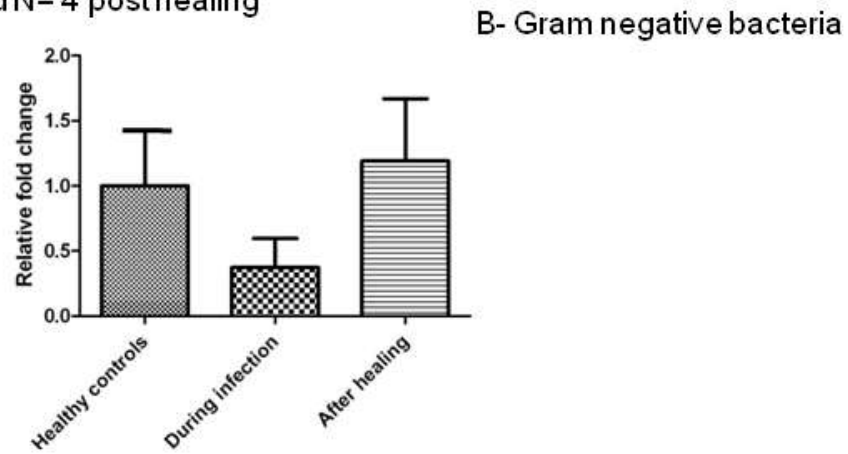
4.3.3.2 Relative gene expression of hBD9

Assessing hBD9 expression in patients with acute *Acanthamoeba* keratitis, demonstrated significant down regulation (50 fold, $P < 0.05$), which increased again after healing, but not to the level observed in healthy controls (figure 9A). Also, in Gram negative bacterial keratitis, hBD9 expression modestly decreased during infection and returned to near control level following complete healing (figure 9B). In Gram positive bacterial keratitis, there was significant 5 fold down-regulation in the gene expression during active infection ($P < 0.05$) which showed further decrease after healing ($P < 0.05$) (figure 9C).

N= 8 healthy controls, N= 7 acute infection and
N= 5 post healing



N= 8 healthy controls, N= 6 acute infection
and N= 4 post healing



N= 8 healthy controls, N= 5 acute infection
and N= 4 post healing

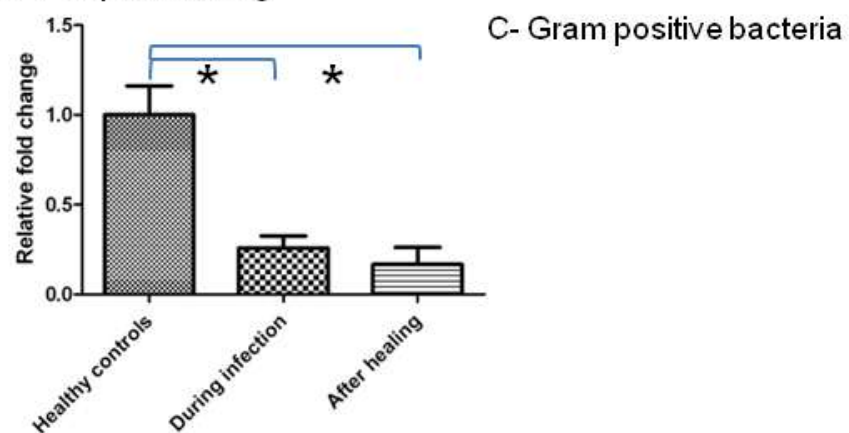


Figure 9. Relative gene expression of hBD9 in impression cytology samples taken from patients with *Acanthamoeba* keratitis, Gram negative and positive bacterial keratitis compared to healthy control. (* = p value is less than 0.05)

4.4 DISCUSSION

Initially, low yields of RNA were repeatedly obtained in all samples taken from the OS of the healthy subjects and patients with infectious keratitis. All these samples were excluded from my study leading to a failure in recruiting any patients during the first 12 months. In an attempt to tackle this problem, RNA later was used depending on previous reports which showed its role in preserving the RNA and improving its quantity (Sikulu et al., 2011, Freidin et al., Linnarsson, 2010). Also, vortexing and spinning of the IC filters down were introduced depending on a previous experience of one of senior lecturers at the Microbiology department at the University of Nottingham to provide an effective separation of the OS cells.

This led to the optimized method in the RNA extraction which improved the quantity and quality of the analysed RNA in most cases. However, some samples still produced poor RNA yield mainly because of the poor cellular yield obtained from infected eyes. Indeed, it was not possible to get any good sample from eyes tearing excessively as this prevented adherence of the filter paper to the ocular surface. Using the previous novel method in optimizing the RNA extraction improved the mean RNA quality obtained from 21 ± 17 to 69 ± 59 ng/ μ l with all samples showing a A260/A280 ratio of more than 1.8.

After the succeeding in improving the RNA yields, RT-PCR analysis of the impression cytology was performed. The main purpose was to

measure the mRNA of hBD9 and hBD3 in patients with ocular infections (during and after the infection) compared to healthy controls.

The antimicrobial activity of hBD3 but not hBD9 proteins is well established (Huang et al., 2007a, Garreis et al., 2010b). Indeed, hBD3 protein has *in vitro* bactericidal activity against *P. aeruginosa* and *S. aureus*. This effect is salt independent, which implicates an active *in vivo* antimicrobial potency in the presence of tears (McDermott et al., 2006, Harder et al., 2001). In addition, hBD3 has been linked to the initiation of the adaptive immune response through its ability to activate dendritic cells in the cornea and conjunctiva (McDermott, 2009). These multiple roles of hBD3 at the OS are consistent with its up-regulation in all cases of acute infectious keratitis, both bacterial and *Acanthamoeba*, demonstrated in this study. When compared with healthy controls, it showed a statistically significant 122 fold increase in acute *Acanthamoeba* keratitis, while it showed only 4 and 10 fold up-regulation in Gram-negative and Gram-positive bacterial keratitis respectively. The expression decreased rapidly in all the studied groups after healing, returning to almost normal level (controls). Such a decrease in AMPs gene expression after the initial up-regulation during the acute stage of infection has been previously reported for murine fungal keratitis (Yuan et al., 2010). The significant *ex vivo* up-regulation of hBD3 gene in patients with acute *Acanthamoeba* keratitis is in keeping with my previous study (**chapter two**) where hBD3 gene expression was shown to up-regulate most significantly among the studied AMPs in HCLE treated with *Acanthamoeba castellanii*

trophozoites (showing a 10 fold increase) (Otri et al., 2010). This consistent and significant *ex vivo* and *in vitro* up-regulation of hBD3 gene during *Acanthamoeba* infections could suggest a specific anti-amoebic role of this gene on the ocular surface. The potential role of AMPs as anti-amoebic treatment was previously reported (Feldman et al., 1991, Schuster and Jacob, 1992, Sacramento et al., 2009). Fieldman and co-workers have shown that the *in vitro* combination of Magainin (a host defense AMP) with silver nitrate is active against *Acanthamoeba* trophozoites and cysts (Feldman et al., 1991). Recently, Sacramento et al (Sacramento et al., 2009) reported that beta defensin induces permeabilization and relative resistance against *Acanthamoeba castellanii* protease activity, suggesting a possible *in vitro* anti-amoebic activity of AMPs.

Another important finding of this study was the significant down-regulation of hBD9 gene expression during acute microbial infections (especially *Acanthamoeba* keratitis, 40 fold decrease). This would support the hypothesis that *Acanthamoeba* specifically targets this gene in order to invade the corneal epithelium and bind to the mannose receptors, as a first step in its pathogenesis (Clarke and Niederkorn, 2006). The ability of *Acanthamoeba* to inhibit this gene could be one of the factors related to its virulence. However, the mechanism by which *Acanthamoeba* dampens the defensin-mediated host defence is unknown. It has been shown that the binding to the mannose glycoprotein on the corneal epithelium via the 136 kDa mannose binding protein of the trophozoites can release several proteases that

interfere with the host immune-response (Sacramento et al., 2009). Most of AMPs are sensitive to proteases and *Acanthamoeba* is known to secrete large amounts of proteases (Sacramento et al., 2009). The degradation role of secreted proteinase produced from *Acanthamoeba* on host defense proteins (Ig and IL-1) and its participation in *Acanthamoeba* virulence has been previously described (Na et al., 2002). This study has demonstrated that *Acanthamoeba* can also suppress defensin expression at the gene level. Down-regulation of human beta defensins genes in response to inflammatory or infectious stimuli has previously been demonstrated (Abedin et al., 2008, Premratanachai et al., 2004, Yuan et al., 2010). Premratanachai et al have reported the down-regulation of hBD9 gene after *in vitro* stimulation of gingival keratinocytes with *Candida albicans* (Premratanachai et al., 2004). The absence of hBD2 gene expression in the limbal region of mice with allergic conjunctivitis compared with control has been shown by Ikeda et al (Ikeda et al., 2006). Furthermore, Yuan et al have demonstrated the initial down-regulation of both hBD1 and hBD2 in the murine OS with fungal keratitis (Yuan et al., 2010). Recently, an initial increase in hBD9 mRNA levels followed by a significant down-regulation in response to stimulation provided by pathogen associated molecular patterns and inflammatory cytokines has also been reported (Mohammed et al., 2010a).

Similar to *Acanthamoeba* keratitis, this study demonstrated a modest down-regulation of hBD9 during acute Gram-negative infection which was significantly down regulated in Gram-positive bacterial keratitis.

After healing, the mRNA level of hBD9 returned almost to control level in Gram negative bacterial group but remained down-regulated in the Gram positive bacterial group. This variation in return to normal level could be a time related phenomenon or may suggest continuing subclinical activation at the cellular level. The reduced level of hBD9 during active bacterial keratitis has already been shown (Abedin et al., 2008). Whether the reduced expression is a cause or effect of the infection is unclear. It remains to be seen what relationship, if any, exists between this defensins and the cytokines, which are known to be a part of the intracellular signalling cascade. Conversely, Mohammed et al (Mohammed et al., 2010a) have found that the human corneal epithelial cells treated with Lipopolysaccharides (LPS, a TLR4 agonist) and flagellin (TLR5 agonist) of the Gram-negative bacteria and Pam3CSK4 (TLR2/TLR6 agonist), a synthetic homologue of polysaccharide (cell-wall protein) from Gram-positive bacteria induced hBD9 mRNA expression. Thus, it suggests that hBD9 response can vary in relation to different pathogenic organisms and between *in vitro* and *in vivo* conditions indicating a significant role of AMPs at the OS.

This study demonstrated an optimised method to improve the RNA yield obtained from impression cytology samples for RT-PCR processing. Also, this is the first study to demonstrate the variable gene expression pattern of hBD3 and hBD9 at the OS in infected corneas and after healing compared with healthy controls. This report clearly indicates the importance of AMP-mediated host defence in different OS infections especially vision-threatening *Acanthamoeba* keratitis. Further

studies to explore the potential anti-amoebic activity of hBD3 and the key role of hBD9 in the *Acanthamoeba* keratitis pathogenesis would help our understanding of the pathogenesis of corneal infections. Also, further analysis of the protein expression of these AMPs during ocular infections is needed to determine the overall profile of these AMPs. However, this was not possible in our study because of the limited cellular yield of impression cytology samples.

CHAPTER FIVE

5 Does Human Beta Defensin-3 have Anti-bacterial Effect?

5.1 INTRODUCTION

Because of the AMPs potential and potent antimicrobial activity, defensins are the most studied AMPs in humans. Among these, hBD3 protein exhibits strong activity against Gram-positive and Gram-negative bacteria and fungi, including *S. aureus* and *E.coli*) (Harder et al., 2001, Song et al., 2009, Huang et al., 2007c, Starner et al., 2005, Sahly et al., 2003, Joly et al., 2004). Furthermore, hBD3 protein can, unlike other human defensins that are salt sensitive, maintain its broad spectrum of activity in the presence of physiological saline which raises the possibility of it being potentially used as a topical antimicrobial agent on the ocular surface (Huang et al., 2007a, Harder et al., 2001).

In **chapter two**, the *in vitro* gene expression of hBD3 showed ten folds increase in HCLE stimulated with *Acanthamoeba castellanii* compared to controls. This significant up-regulation of hBD3 gene was the most - significant among all the AMPs studied (Otri et al., 2010). Furthermore, in chapter four, the gene expression of hBD3 demonstrated 120 fold increase in IC samples taken from the ocular surface of patients with

active *Acanthamoeba* keratitis compared with the healthy controls. Also, in **chapter three**, the *in vitro* gene expression of hBD3 showed significant increase in samples of HCEC treated with both *P. aureuginosa* and *S. aureus* compared to controls. Furthermore, when compared to samples from healthy subjects, the gene expression of hBD3 had increased up to 4.5 and 34 fold in IC samples taken from patients with Gram-negative and Gram-positive bacterial corneal infections, respectively (Otri et al., 2012).

Based on the results of my previous work and to characterize the potential antimicrobial activity of hBD3, I sought to further investigate the microbicidal activity of the recombinant protein of HBD3 against Gram negative (*E.coli*) and Gram positive (*S. aureus*) bacterial isolates.

5.2 METHODS

According to the manufacturer's instructions, two different recombinant hBD3 (rhBD3) proteins (ABD Serotec, catalogue number: PHP211) and (Thermo Scientific, catalogue number: RP87647) were reconstituted in 200 μ l of distilled water to get a final volume of 20 μ g with a concentration of 0.1 mg/ml after reconstitution. In addition, in separate experiments, these proteins were also reconstituted in 20 μ l of 10 mM acetic acid and 4 mM of hydrochloric acid as advised by the manufacturers to get a final volume of 20 μ g with a concentration of 1.0 mg/ml after reconstitution. The bactericidal activities of hBD3

(reconstituted with distilled water, acetic acid and hydrochloric acid) at concentrations of 5, 10, 20 and 40 µg /ml were tested.

The antimicrobial activity of hBD3 was tested as previously described using the conventional colony counting method (Harwig et al., 1994). Suspensions of *S. aureus* and *E. coli* isolated from human corneal infections were used in this experiment. Briefly, the microorganisms were grown in BHIB (OXOID, Hampshire, UK) overnight at 37°C in an incubator. Then 50 µl of the suspension were added to 1 ml of the fresh BHIB and incubated in an orbital shaker at 37°C for 3 hours to obtain the mid logarithmic-phase cells. An aliquot of 25 ml of the culture was centrifuged for 10 minutes and the pellet was re-suspended in 10 ml of Dulbecco's phosphate buffered saline (PBS) (Sigma-Aldrich, Ayrshire, UK). The optical density of 1 ml of the suspension was measured at 620 nm and recorded a value of 0.2. This optical density corresponds to approximately 5×10^7 colony forming units (CFU)/ ml of bacteria (Harwig et al., 1994). This suspension was diluted to 5×10^6 CFU/ ml in PBS. Thereafter, 10 µl from each bacterial suspension was added to 90 µl of a mixture of PBS and hBD3 protein at the concentrations described above. This mixture was incubated in at 37°C for 3 hours and then a 10 fold serial dilution (10^{-1}) was prepared by vortex mixing and transferring 10 µl to 90 µl of the buffer. We repeated this process to prepare further dilutions (up to 10^{-8}). Ten µl aliquots of each sample were spread over the surface of agar base (OXOID, Hampshire, UK). The plates were incubated at 37° C for 24 hours. The first dilution at which colonies were discrete and culture was not confluent were used to count

the total number of colonies, those are only plates with up to 500 CFU per plate (Harwig et al., 1994). The mean number of colonies per plate multiplied by the dilution ratio enabled the evaluation of colony forming units/mL in the original 100 μ L incubation mixture. Similarly, bacterial suspensions in PBS, in distilled water alone, acetic acid alone and hydrochloric acid alone (without hBD3 protein) were used as negative controls for each bacterial suspension.

All assays were done in triplicate and each experiment was repeated three times. The numerical data obtained from the mean of the CFU count were entered in an Excel spread sheet and exported to the SPSS software package (version 16.0 , IBM, Chicago, IL) for statistical analysis. The parametric T-test was used to compare between 2 independent samples (the treated sample and the control). The significance value was set at $P < 0.05$.

5.3 RESULTS

Overall, when using distilled water for reconstitution and compared with the negative control (distilled water alone), no significant antimicrobial activity of the hBD3 was confirmed. This was applicable at all concentrations and against both *S. aureus* and *E. coli*. After the use of the acetic acid and the hydrochloric acid for reconstitution, hBD3 protein showed potent activity against the studied bacteria at all concentrations. However, when compared with the antimicrobial

activity of the acidic solvent alone (without the hBD3 protein), there was no significant difference between both groups.

The following tables illustrate the detailed information about the antimicrobial assays.

5.3.1 Testing the antibacterial effect of the HBD3 against *S. aureus*

5.3.1.1 HBD3 reconstituted in distilled water and tested against *S. aureus*

Table 5. Showing the Colony forming units in serial dilutions of *S. aureus* bacteria tested against 40, 20, 10 and 5 µg /ml of HBD3 reconstituted in distilled water. The colony forming units were also calculated in bacterial samples treated with distilled water alone (as a negative control) at the previous concentrations. The P value of the T.test of the difference between the two groups was also calculated and shown.

Dilution of the <i>S. aureus</i>	10 ⁻¹	10 ⁻²	10 ⁻³	10 ⁻⁴	10 ⁻⁵	10 ⁻⁶	10 ⁻⁷	10 ⁻⁸
Colony forming units in serial dilutions of <i>S. aureus</i> bacteria tested against 40 µg /ml of HBD3								
Mean CFU in HBD3samples	NC	NC	NC	NC	23.6±0.6	4.6±0.5	0	0
Mean CFU in water samples	NC	NC	NC	NC	25.3±1.5	2.3±1.5	0	0
P value	N/A	N/A	N/A	N/A	0.15	P=0.09	1	1
Colony forming units in serial dilutions of <i>S. aureus</i> bacteria tested against 20 µg /ml of HBD3								
Mean CFU in HBD3samples	NC	NC	NC	NC	22±1	2.3±5.7	0	0
Mean CFU in water samples	NC	NC	NC	NC	21±2.6	2.3±5.7	0	0
P value	N/A	N/A	N/A	N/A	0.57	1	1	1
Colony forming units in serial dilutions of <i>S. aureus</i> bacteria tested against 10 µg /ml of HBD3								
Mean CFU in HBD3samples	NC	NC	NC	NC	21.3±2	1.6±0.5 7	0	0
Mean CFU in water samples	NC	NC	NC	NC	21.6±1.5	1.3±0.5 7	0	0
P value of the difference	N/A	N/A	N/A	N/A	0.83	0.51	1	1
Colony forming units in serial dilutions of <i>S. aureus</i> bacteria tested against 5 µg /ml of HBD3								
Mean CFU in HBD3samples	NC	NC	NC	NC	18.6±0.57	1.6±0.5	0.33 ±0.5	0
Mean CFU in water samples	NC	NC	NC	NC	17±1	1.6±0.5 7	0	0
P value	N/A	N/A	N/A	N/A	0.67	1	0.37	1

(NC: Not countable, N/A: Not applicable, mean CFU= mean± standard deviation)

5.3.1.2 HBD3 reconstituted in 10 mM of acetic acid & 4 mM of hydrochloric acid and tested against S. aureus

Table 6. Showing the Colony forming units in serial dilutions of S. aureus bacteria tested against 40 µg /ml of HBD3reconstituted in 10mM of acetic acid & 4 mM of hydrochloric acid. [Exactly similar results were obtained at concentrations of 20, 10 and 5 µg /ml of HBD3 (results not shown)]

Dilution of the S. aureus	10⁻¹	10⁻²	10⁻³	10⁻⁴	10⁻⁵	10⁻⁶	10⁻⁷	10⁻⁸
Mean CFU in HBD3samples	0	0	0	0	0	0	0	0
Mean CFU in samples with acetic & hydrochloric acids	0	0	0	0	0	0	0	0

**5.3.2 Testing the antibacterial effect of the HBD3
against *E. coli***

**5.3.2.1 HBD3 Reconstituted in distilled water and tested
against *E.coli***

Table 7. Showing the Colony forming units in serial dilutions of *E. coli* bacteria tested against 40, 20, 10 and 5 µg /ml of HBD3 reconstituted in distilled water. The colony forming units were also calculated in bacterial samples treated with distilled water alone (as a negative control) at the previous concentrations. The P value of the T.test of the difference between the two groups was also calculated and shown.

Dilution of the <i>E. coli</i>	10 ⁻¹	10 ⁻²	10 ⁻³	10 ⁻⁴	10 ⁻⁵	10 ⁻⁶	10 ⁻⁷	10 ⁻⁸
Colony forming units in serial dilutions of <i>E. coli</i> bacteria tested against 40 µg /ml of HBD3								
Mean CFU in HBD3samples	NC	NC	NC	NC	26±1	2.3±0.57	0	0
Mean CFU count in water samples	NC	NC	NC	NC	26±1	2±1	0	0
P value	N/A	N/A	N/A	N/A	1	0.64	1	1
Colony forming units in serial dilutions of <i>E. coli</i> bacteria tested against 20 µg /ml of HBD3								
Mean CFU in HBD3samples	NC	NC	NC	NC	18.3±2	1.6±0.57	0	0
Mean CFU count in water samples	NC	NC	NC	NC	19.3±5.7	1.6±0.57	0	0
P value	N/A	N/A	N/A	N/A	0.46	1	1	1
Colony forming units in serial dilutions of <i>E. coli</i> bacteria tested against 10 µg /ml of HBD3								
Mean CFU in HBD3samples	NC	NC	NC	NC	20±1.73	2±1	0	0
Mean CFU count in water samples	NC	NC	NC	NC	20±1.52	2±1	0	0
P value	N/A	N/A	N/A	N/A	0.81	1	1	1
Colony forming units in serial dilutions of <i>E. coli</i> bacteria tested against 5 µg /ml of HBD3								
Mean CFU in HBD3samples	NC	NC	NC	NC	18.6±0.57	1.3±0.57	0	0
Mean CFU count in water samples	NC	NC	NC	NC	18.3±1.5	1.6±0.57	0	0
P value	N/A	N/A	N/A	N/A	0.74	0.52	1	1

(NC: Not countable, N/A: Not applicable, mean CFU= mean± standard deviation)

5.3.2.2 HBD3 reconstituted in 10 mM of acetic acid & 4 mM of hydrochloric acid and tested against E. coli

Table 8. Showing the Colony forming units in serial dilutions of E. coli bacteria tested against 40 µg /ml of HBD3reconstituted in 10mM of acetic acid & 4 mM of hydrochloric acid. [Exactly similar results were obtained at concentrations of 20, 10 and 5 µg /ml of HBD3 (results not shown)]

Dilution of the E. coli	10 ⁻¹	10 ⁻²	10 ⁻³	10 ⁻⁴	10 ⁻⁵	10 ⁻⁶	10 ⁻⁷	10 ⁻⁸
Mean CFU in HBD3samples	0	0	0	0	0	0	0	0
Mean CFU in samples with acetic & hydrochloric acids	0	0	0	0	0	0	0	0

5.4 DISCUSSION:

The antibacterial activity of HBD3 has been reported in relation to Gram-positive and Gram-negative bacteria (Joly et al., 2004, Huang et al., 2007a, Song et al., 2009, Garcia et al., 2001a). My previous *in vitro* studies with *Acanthamoeba* showed that corneal cells infected with this organism demonstrated a 10 fold significant increase in gene expression for hBD3. This led to believe that hBD3 may have amoebicidal activity as well. To test this hypothesis, it was imperative that we establish and optimised antibacterial activity of our acquired samples of HBD3 such that they could be then run in parallel with experiments to evaluate anti amoebicidal activity if any. My primary aim was not to merely repeat previous experiments to confirm published data on antimicrobial activity of HBD3. *E.coli* and *S. aureus* were

selected as was done by others (Joly et al., 2004, Huang et al., 2007a, Song et al., 2009).

The antibacterial activity of hBD3 protein will depend on the source of the molecule and the nature of the solvent in which it is dissolved for use in the experiments. With regard to the former, two human rhBD3 sourced from ABD Serotec and Thermo Scientific companies were used. According to the manufacturer, the rhBD3 was expressed in *E.Coli*. It consisted of 45 amino acids, with a molecular weight of 5.1kD (ABD Serotec) and 4.3 kD (Thermo Scientific) as described in the methods section. The commercially available rhBD3 used in similar studies were all 45 amino acid long and 5.1 kD weight (Nuding et al., 2009, Starner et al., 2002, Starner et al., 2005, Liberatore et al., 2009). All of these rhBD3 were reported to exhibit antimicrobial activity against Gram-positive bacteria (*S. aureus*) and Gram-negative bacteria (*E.coli*) by the manufactureres. Furthermore, they were all expressed in *E. coli* and refolded before purification.

My initial results using the rhBD3 reconstituted in distilled water were inconclusive. No antibacterial activity was demonstrable. Hence, according to manufacturer's instructions, I reconstituted the rhBD3 in acidic medium using acetic acid in set one of experiments and HCl in another. The acidic solvent media was used as controls and I was surprised to note that all antibacterial activity could be attributed to the acid rather than to the protein. Indeed, when the antibacterial activity of the rhBD3 dissolved in acidic media was compared with the acidic

media alone (control), the differences were not statistically significant. I concluded that the acidic solvent was responsible of the antibacterial effect, and by itself stopped the growth of the bacteria at all dilutions. Importantly, the potent in vitro antibacterial activity of the acetic acid has been documented before (Rhee et al., 2003, Thorp et al., 1998, Nagoba et al., 1997, Moussa et al., 2009, Larsen et al., 2011). To support this contention that in some of the previously reported studies the acidic solvent could be responsible for the antibacterial effect rather than the hBD3 tested, I comprehensively reviewed the literature related to the microbicidal effect of the recombinant hBD3 and focused onto the methodology in preparing the protein and testing its anti-microbial effect. This yielded interesting results discussed below.

The potent antibacterial activity of the commercially available rhBD3 against oral Gram-negative and positive bacteria has been previously reported by Joly et al using the radial diffusion method. However, acetic acid was used for hBD3 reconstitution without testing its effect alone as a negative control (Joly et al., 2004). In another study, Nuding et al have also used the acetic acid for reconstitution of the commercially available rhBD3. They reported in the methods section that they had used the solvent (acetic acid) as a negative control but have not reported the results of the negative control in their paper. They concluded that hBD3 protein had good activity against dominant anaerobe genera of the gut, using the conventional colony count method (Nuding et al., 2009). It has also been reported by Starner et al in two separate studies that HBD3 reconstituted in acetic acid

exhibited a unique spectrum of anti-bacterial activity against isolates from lung sepsis in the neonate (Starner et al., 2005) and against *Haemophilus influenza* (Starner et al., 2002). However, in both studies, radial diffusion method was used and no negative control of acetic acid alone was prepared. Fazakerley et al have also reported the antibacterial activity of the hBD3 against canine *Staphylococcus pseudintermedius*. As the previous studies, they have used the acetic acid for protein preparation without testing against the acetic acid alone as a control (Fazakerley et al., 2010). Moreover, Maisetta et al tested the hBD3 protein activity against gingival bacteria. They also used acetic acid for the hBD3 reconstitution and did not use any negative control (Maisetta et al., 2011). Recently, the bactericidal activity of one of the commercially available hBD3 has been proved to be active. This protein was reconstituted in physiological saline (instead of acetic acid) and it showed activity against *S. aureus* and *E.coli* using the conventional colony count method (Liberatore et al., 2009). The same protein with the same catalogue number but reconstituted in acetic acid has also shown to be active against different types of *Nocardia*. Importantly, it was tested against the acetic acid as a negative control and showed potent broad spectrum activity against some types of *Nocardia* whereas others showed resistance (Rieg et al., 2010). It is possible that this hBD3 product has the right formulation to demonstrate true antibacterial activity. However, this specific sample was not available for us to try.

On the other hand, the anti-bacterial activity of the synthesized analogue of the in-house hBD3 which was recombinantly cloned or chemically synthesized has been shown to be active against most bacteria. The cloning process comprises encoding the cDNA with amino acids containing the natural form of hBD3 into vectors while the chemical synthesis involving enzymatic reactions to arrange the amino acids and cysteine bonds in an order identical to the naturally secreted hBD3. In most of the studies which used these methods of preparing the hBD3 protein, derivatives of acetic acid or hydrochloric acids were involved in the preparation process and it is not clear if attempts were made to get rid of acetic acid before the final test (Song et al., 2009, Sahly et al., 2003, Garcia et al., 2001a, Hoover et al., 2000, Scudiero et al., 2010). However, it was technically not practical to compare our results using the commercially available hBD3 with the cloned or chemically synthesized hBD3 used in other studies. Interestingly, the original study reporting novel bactericidal activity of hBD3 was by Harder et al who demonstrated a salt-insensitive broad spectrum of potent antimicrobial activity against many potentially pathogenic microbes. Recombinant hBD3 expressed in *Escherichia coli* and chemically synthesized hBD3 were shown to be indistinguishable from naturally occurring peptide with respect to their antimicrobial activity using the conventional colony count method. Trifluoroacetic acid was used in preparing the hBD3 without testing its antimicrobial as a negative control (Harder et al., 2001). It has also been shown by many authors that the use in house hBD3 was active against different

pathogenic bacteria. Acetic acid was used for reconstitution in all these studies but no results were reported about testing it alone as a negative control (Garcia et al., 2001a, Sahly et al., 2003, Hoover et al., 2000, Scudiero et al., 2010). Differently, Song et al have reported that the rhBD3 prepared by cloning was active against the intracanal bacteria. They used phosphate-buffered saline for dissolving which served as a negative control. No acetic solvents were used in this study (Song et al., 2009).

In this study, in the product data sheets accompanying the ABDseroTec HBD3 samples, it was specifically claimed that the hBD3 protein exhibits antimicrobial activity against *S. aureus* and *E. coli*: "Exhibits antimicrobial activity against Gram-positive bacteria *S.aureus* and Gram-negative *P. aeruginosa* and *E. coli*". The Thermo scientific product sheet, however, reported the general antibacterial activity of their product: "having a wide ranging antimicrobial activity". As our conclusions contradicted this claim we corresponded with the companies to obtain their experimental protocols, which we hoped to duplicate in our lab. I specifically requested the manufacturers to send us the protocol used by them in confirming the antimicrobial activity of the rHBD3. The manufacturers were very co-operative and initially confirmed that they had tested the antimicrobial activity of these HBD3 but later acknowledged that the protein was only tested in chemotaxis assay (not antibacterial assay). In addition, the online datasheet of HBD3 (catalogue number: PHP211) on the ABDseroTec website has been changed to "Exhibits chemotactic activity on monocytes" without

mentioning anything about its antimicrobial activity (<http://www.abdserotec.com/product/defensin-beta-3-recombinant-protein-php211.html>).

The final communication from ABDseroTec stated: "Thank you for your patience. My sincere apologies but the labs have advised me that they have been unable to setup the antimicrobial assay for the HBD3. The original assay was performed by an external lab that we no longer have access to. The labs, however, have confirmed the peptide to be active by chemotaxis (on monocytes). I appreciate that there would be significant differences between the chemotaxis assay and the antimicrobial assay and that a chemotactically active BD-3 may not necessarily retain its antimicrobial properties."

A refund was requested from one of the companies (ABDseroTec) and was gratefully received. On the other hand, the final communication from Thermo Scientific stated: "Unfortunately we have not tested the protein in a proliferation assay, only in chemotaxis assays on several different cell types. Therefore we can't comment on your protocol. I have attached the chemotaxis protocol that we use for the bioassay. Perhaps you can test the functionality of the protein in the chemotaxis assays."

Surprisingly, the rhBD3 from Thermo Scientific company (catalogue number: RP-87647) has been discontinued afterwards (<http://www.pierce-antibodies.com/beta-3-Defensin-Recombinant-Protein--RP87647.html>)

This study highlights the technical pitfalls that might affect experimental studies and adhering to basic principles, such as use of proper controls, is essential. With regard to the antimicrobial efficacy of HBD3, even though we were unable to demonstrate this, the available evidence from a few well conducted studies would suggest that its gene expression is up-regulated in infections (Otri et al., 2010, Garreis et al., 2010b, Huang et al., 2007c) and that it does have a microbicidal effect against a range of organisms (Song et al., 2009, Liberatore et al., 2009, Rieg et al., 2010).

CHAPTER SIX

6 Corneal Densitometry as an Indicator of Corneal Health

6.1 INTRODUCTION

Infectious corneal ulcers are important causes of ocular morbidity and may lead to severe visual loss if not diagnosed and treated properly. Prompt diagnosis and close follow up are essential for better visual results. At present, clinical examination is the mainstay for the early diagnosis of the infectious keratitis. The depth and dimensions of the infectious corneal infiltrate and the size of the epithelial defect provide important information about the response to treatment.

Sequential anterior segment photography over the course of an infectious keratitis lesion can allow evaluation of ulcer and infiltrate dimensions. The physician can review the series of photos and evaluate response to therapy. This method is however fairly subjective and suffers from the limitation related to differences in magnification and exposure at different visits making exact comparison difficult without use of image analysis software. Recently, corneal imaging has been used as a means of recording extent of infiltrate and determining the initial response to treatment. The new technology of anterior segment optical coherence tomography is very useful in observing the

progress of corneal infections. It can provide numerical values of the dimensions and depth of the infiltration and the overall inflammatory state of the cornea with high quality cross sections of the entire cornea (Konstantopoulos et al., 2008, Konstantopoulos et al., 2007). Furthermore, *in vivo* confocal microscopy is another new technology which can provide cellular and sub-cellular images of the corneal tissue at various depths and help in the diagnosis of fungal or *Acanthamoeba* keratitis but does not identify bacteria (Daxer et al., 1998). These technologies are however not available in all centres and there is always a need for novel approaches to quantify the extent and depth of ulcers and infiltrates and use this information in analyzing the healing process, in particular the response to the treatment.

Scheimpflug photography of the anterior segment is also a relatively new imaging modality and is superior to the slit-lamp photography. In comparison to anterior segment OCT, it provides better quantification of light scattering and can help in assessing corneal infiltrates (Wegener and Laser-Junga, 2009). The OCULUS Pentacam (Oculus Inc., Germany) is a non-invasive optical system which takes up to 50 cross-sectional images of the entire anterior segment within 2 seconds depending on the Scheimpflug principle (Oculus, 2003, Cho et al., 2010).

To understand the Scheimpflug image principle, a description of three planes should be known: the film, the lens and the sharp focus planes (figure 10). The film plane is a flat imaginary surface upon which the

film is fixed. The lens plane is another flat imaginary surface passing through the optical centre of the lens. If these two planes are not absolutely parallel, they will intersect along a straight line. The plane of sharp focus is a third imaginary surface positioned such that any object lying on it will be imaged sharply (by the lens) on the film plane. For an ordinary camera, the three planes are parallel to one another and so they never intersect.

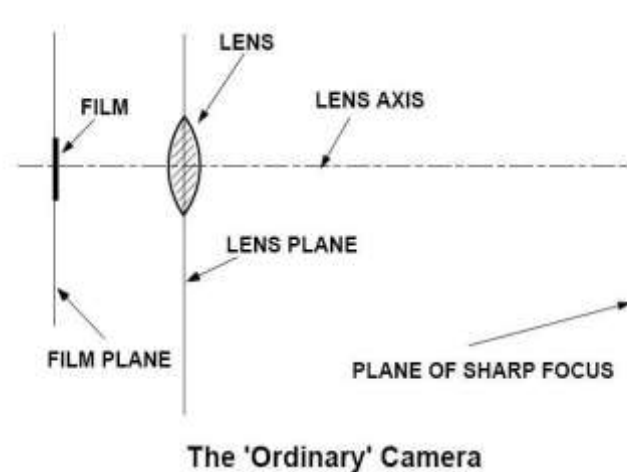


Figure 10. The angles of the ordinary camera, using the example of a photographic lens (Merklinger, 1992).

The Scheimpflug principle states that if a lens is tilted such that the lens plane intersects the film plane, the plane of sharp focus must also pass through that same line of intersection (figure 11). The line formed by the intersection of the lens plane, film plane and plane of sharp focus will be called the Scheimpflug line. The major advantage of Scheimpflug over other imaging techniques is that the entire depth of the structure imaged is in focus. This provides impressive image

sharpness even in scenes with significant depth of field, not like the ordinary camera (figure 12) (Merklinger, 1992).

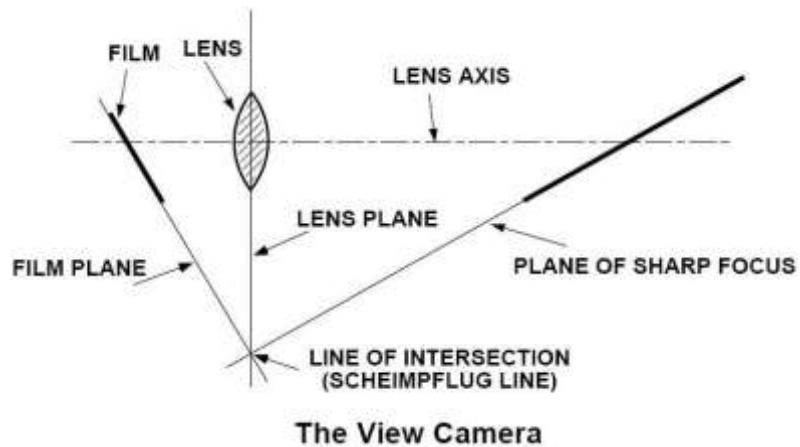


Figure 11. The angles of the Scheimpflug principle, using the example of a photographic lens (Merklinger, 1992).

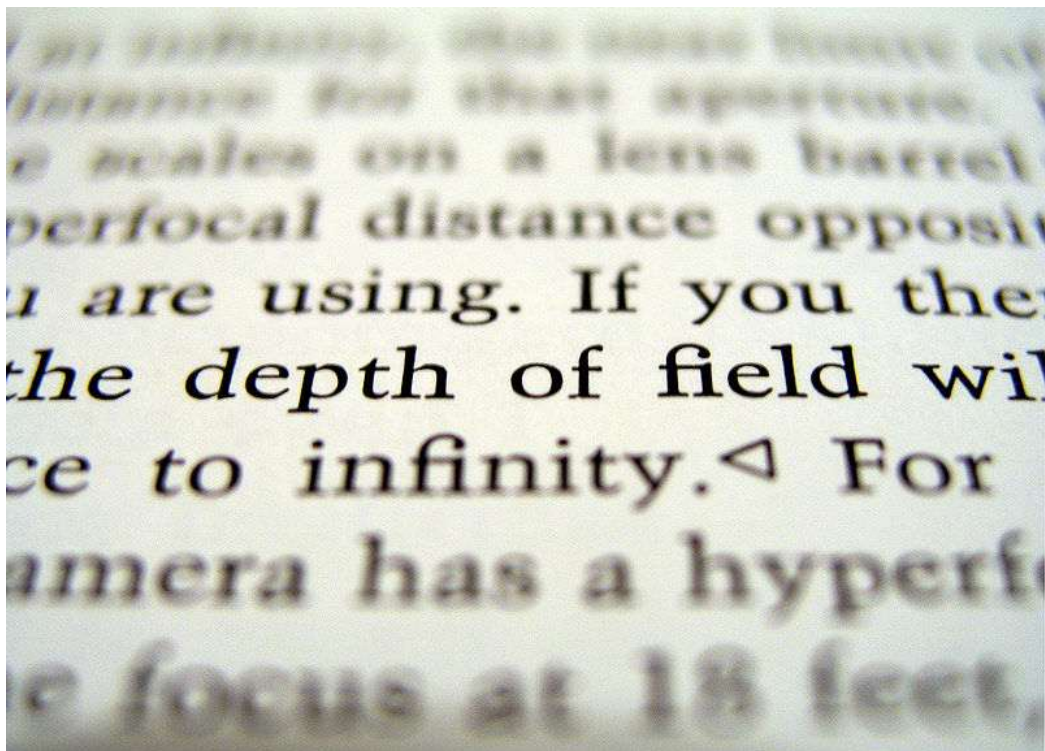


Figure 12 With a normal camera, when the subject is not parallel to the image plane, only a small region of the text is in focus. Conversely, with Scheimpflug dependent devices, the whole text will be clear even with non-parallel planes.

Depending on the previous principle, Oculus Pentacam has specifically been designed to assess the anterior segment of the eye from the anterior corneal surface to the posterior lens surface in a single scan without contacting the cornea. The Pentacam requires minimal experience for image acquisition (Buehl et al., 2006), it simultaneously provides complete corneal pachymetry, corneal topography, densitometry of cornea (measuring the scattering of the light) and lens including opacities and anterior chamber analysis (depth, angle, and volume) (Oculus, 2003). The ability to measure changes in corneal transparency non-invasively and objectively could enable more precise monitoring of progression and improve patient management.

Corneal densitometry has previously been used to assess and quantify the degree of sub-epithelial corneal haze and stromal scarring in refractive surgery patients (van de Pol et al., 2001, Takacs et al., 1995, Matsuda et al., 2007). The use of this novel technique in assessing corneal transparency in patients with infectious keratitis has not been reported before and could provide a useful standard when assessing the clarity of cornea during and after corneal infections.

The aim of this study was to measure the corneal density of the clear corneas of healthy subjects to establish 'normal' values and then to investigate the imaging capabilities of the Pentacam in patients with microbial keratitis at the active stage of the disease and during the healing process.

6.2 METHODS

This prospective study was approved by Queen's Medical Centre, University Hospitals NHS Trust (reference number: 1487).

6.2.1 Normal Eyes

After obtaining informed consent, 64 eyes of 40 healthy controls were studied. Routine slit-lamp examination was carried out before Pentacam scanning (Oculus Pentacam Rotating Scheimpflug Camera; Oculus, Wetzlar, Germany) to exclude any corneal opacity. The automatic release mode of the Pentacam was used to determine when correct focus and alignment with the corneal apex had been achieved. This reduced operator dependent variables associated with manual scanning. Imaging was performed using the 50 scans setting obtained in 2 seconds. Pentacam examination was carried out and densitometry values were ascertained by two different methods:

6.2.1.1 Corneal densitometry at different points:

Corneal density was measured at four different axes (180, 45, 90 and 135) at 5 different points along each axis - the centre of the cornea, 1.5 mm either side of centre and 3.5 mm either side of centre (figure 13). Overall, the densitometry measurements of the central point of the cornea, the central 3 mm, and the peripheral 7 mm for each axis were reported. The measurements of temporal, nasal, inferior, and superior halves of the cornea were also assessed by mixing and matching between values.

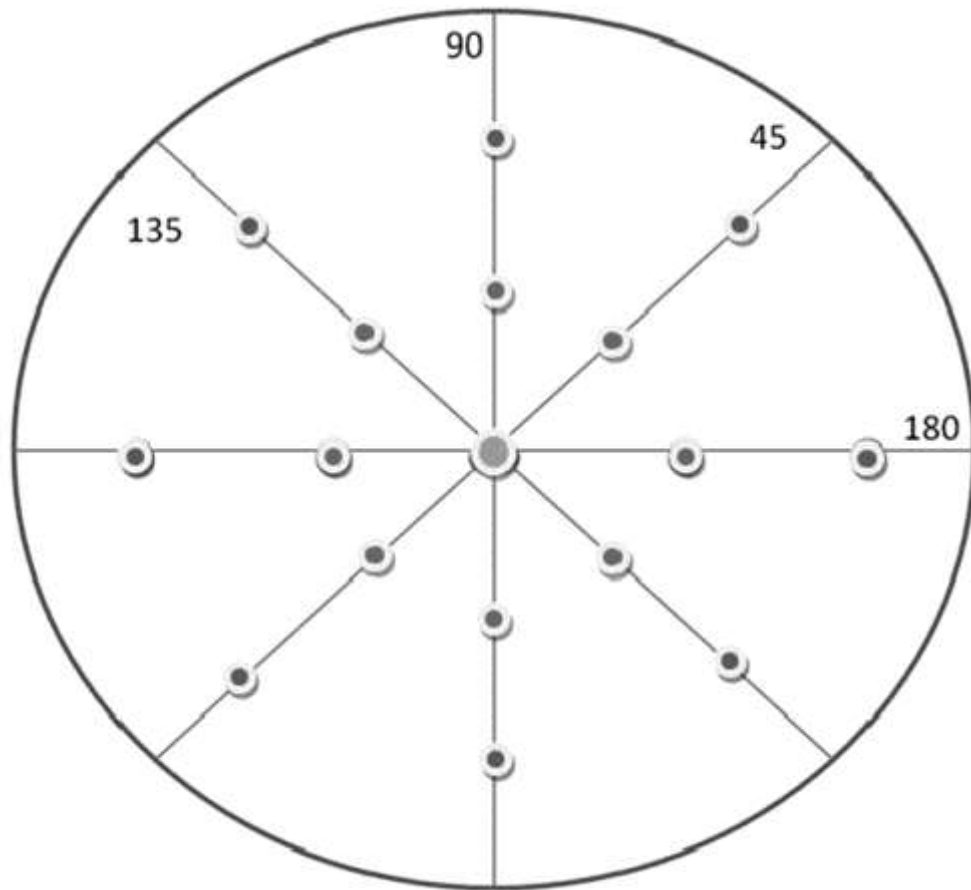


Figure 13 The figure illustrates the 4 axes (45, 90, 135 and 180 degrees) and the 5 points on each axis where densitometry was performed. The inner points were 1.5 mm and the outer were 3.5 mm from the centre.

The corneal density (densitometry) was measured using the caliper tools provided by the Pentacam Oculus software. This allowed the operator to mark a point on the cross sectional scan of the cornea (from epithelium to endothelium) and the software calculated the densitometry value at the defined point (figure 14A). The average readings and the standard deviations were then calculated.




Figure 14. This figure shows the two different methods in measuring the density of the cornea: the densitometry at different points (A) and the densitometry of the total cross sectional areas (B).

6.2.1.2 Corneal densitometry of total cross sectional area:

The central 7 mm area of the cross section of the cornea along each of the 4 axes (180, 45, 90 and 135) was manually defined (figure 14B) and densitometry was then automatically measured for the entire area. The density was measured using the caliper tools by assigning the specified area on the cross sectional scan of the cornea and the software calculated the densitometry value of that defined area. The average and the standard deviation readings were then recorded.

For densitometry readings at each point, the instrument gives a maximum, a minimum and an average reading. Similarly, measuring corneal density of the total cross sectional area gives a maximum and an average (but not minimum) reading. These were recorded separately.

6.2.2 Patients with Bacterial keratitis

Informed consent was obtained from all recruited subjects. Routine slit-lamp examination was carried out and the location, depth and diameter of the corneal infiltrates were recorded. Pentacam examination was then performed prior to any intervention such as for taking samples for microbiological examination by corneal scrapes.

Fifty two patients with bacterial keratitis who presented to the eye unit in Queen's Medical Centre in Nottingham, UK were prospectively studied. Sixteen patients were excluded from this study. Of these, 13 patients had un-reliable Pentacam images as indicated by the reliability threshold of the instrument. Inability of the patient to fixate, photophobia, excessive tearing and discharge and poor patient cooperation due to pain and eye condition were factors that prevented good readings from being obtained. A further three patients were excluded because they defaulted on scheduled follow up visits.

Thirty six patients were thus available for analysis. In these, the Pentacam examination was carried out at two time points; at presentation and 4 to 6 weeks after the complete resolution (complete cessation of treatment). The automatic release mode of the Pentacam was used in all examinations. The density (densitometry) of the stromal infiltrate was measured using the caliper tools. The principles of measuring densitometry at specific points and across a cross sectional area, were applied to the patients with keratitis as well.

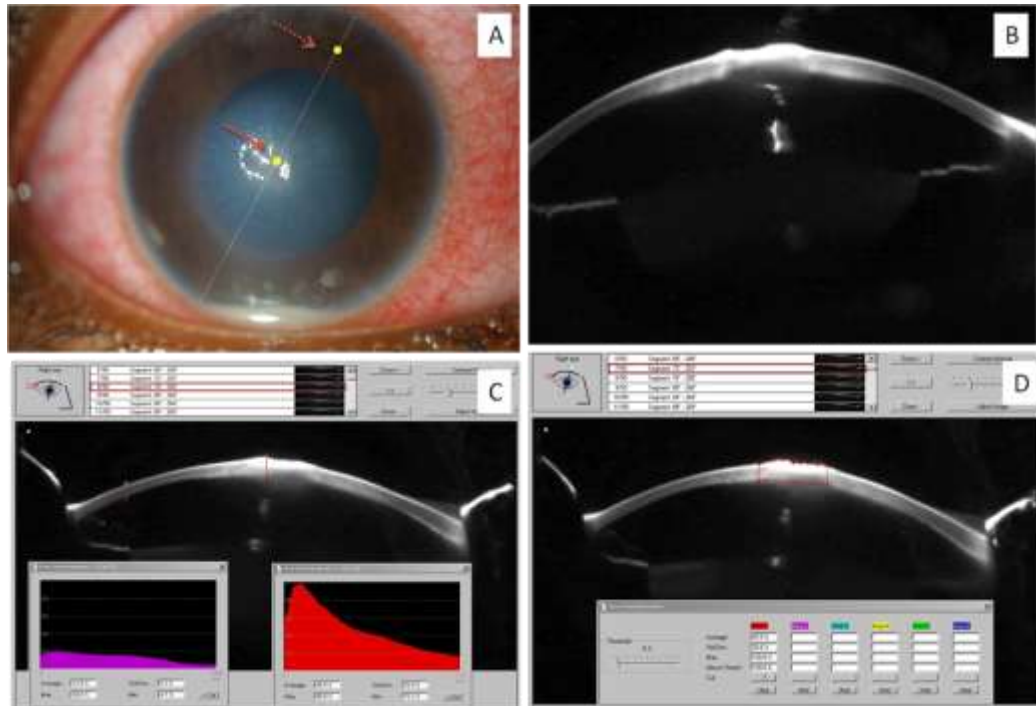


Figure 15. Densitometry in patient with active infectious keratitis. A demonstrates active central infectious keratitis (dark arrow) and the furthest away point of clear cornea (dotted point). B illustrates the Pentacam overview of the corneal ulcer. C shows how to measure the corneal density during the active stage of infection at two different points: the central involved ulcer (central point) and the furthest away point of clear cornea (at the periphery). D shows how the total cross sectional area of the infiltrate was measured. All the measurements were calculated at the same axes.

6.2.2.1 Corneal densitometry at specific points

The corneal density was measured at the site of maximal infiltrate by placing one caliper arm on the epithelial surface of the cornea and the second arm on the endothelial surface passing through the centre of the infiltrate. Densitometry was also performed at a point in clear cornea furthest away from the infiltrate, just within the limbus (figures 15C and 17C). The location of this point on the morphometry grid was noted and densitometry at the same point was measured at each visit. For densitometry readings at each point, the instrument gives a

maximum, a minimum and an average reading. These readings were analyzed separately.

6.2.2.2 Corneal densitometry of total cross sectional area:

The area over which the infiltrate extended was manually defined using the caliper arms and densitometry of the entire defined area was measured (figures 15D and 17D). For densitometry readings of cross sectional area, the instrument gives a maximum and an average reading. These readings were analyzed separately.

After 4-6 weeks of complete healing of keratitis with residual scarring (figures 16A and 16B & 18A and 18B), the average densitometries at the same point and of the same area on the same axis were measured again using the principles described above, regardless of the location of the scar tissue (figures 16C and 16D & 18C and 18D).

The corneal thickness measurements for the infected areas were also ascertained from the Pentacam imaging in all eyes examined. All scans and measurements were carried out by the same investigator.

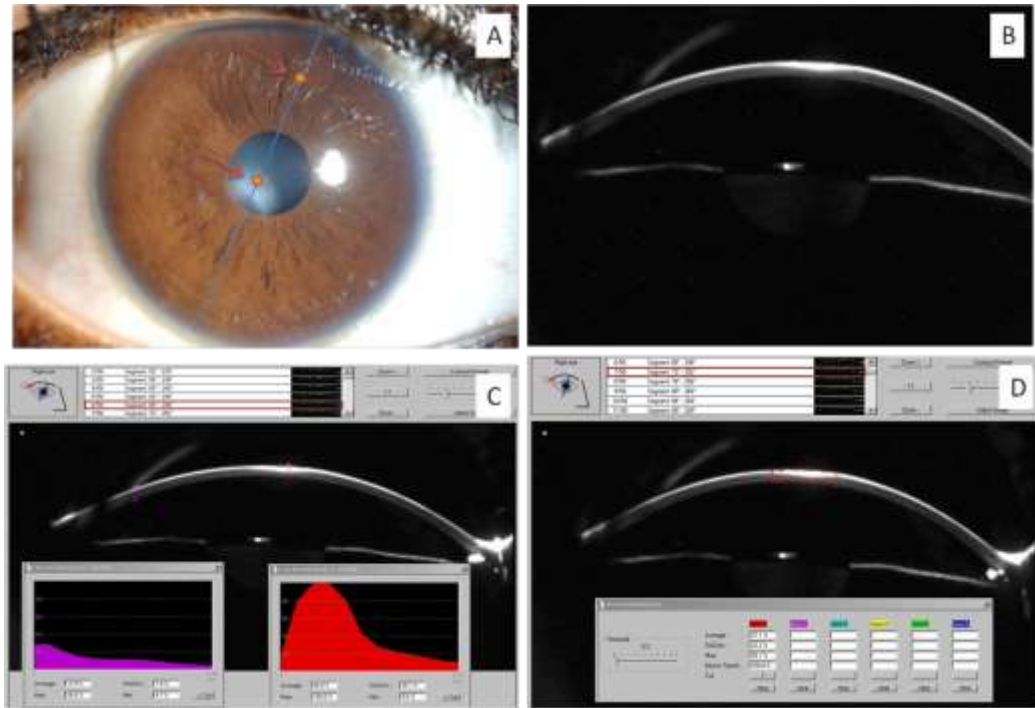


Figure 16. Densitometry in patient with healed infectious keratitis. A shows the corneal scarring after the full healing of the active ulcer of the previous patient (dark arrow) and the furthest away point of clear cornea (dotted arrow). B reveals the Pentacam overview of the corneal scar. C illustrates the densitometry at the central scarring (central point) and at the furthest away point of clear cornea (at the periphery). D shows how the total cross sectional area of the infiltrate was measured. All the measurements were calculated at the same axes.

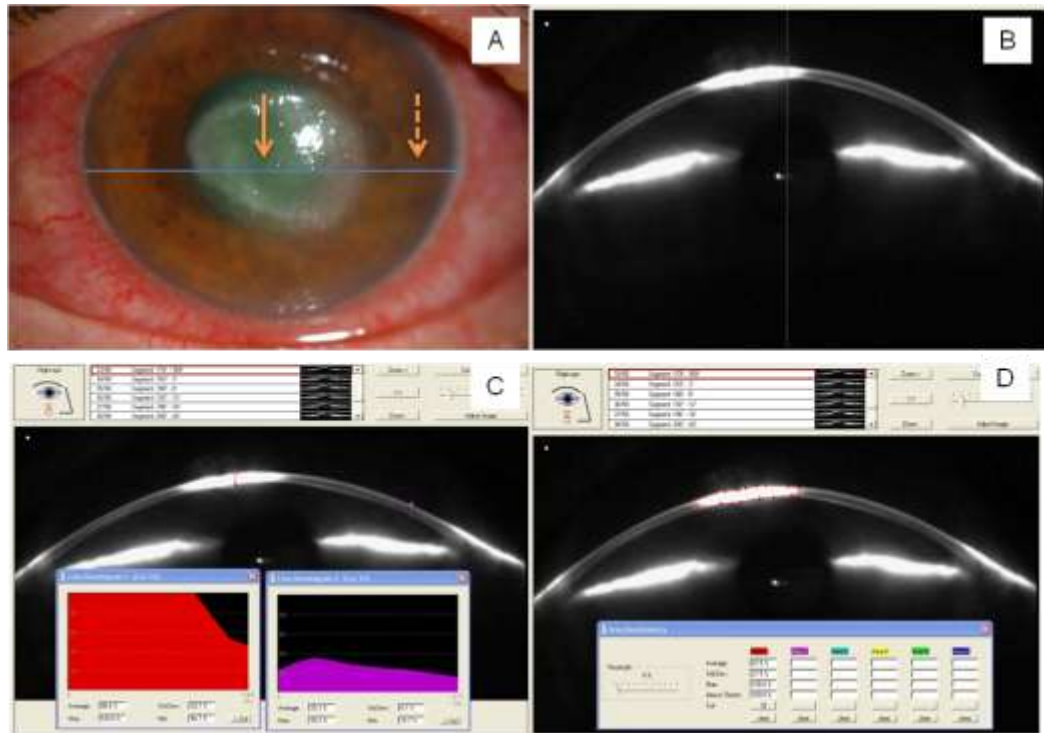


Figure 17 Another example of Densitometry in patient with active infectious keratitis. A demonstrates active central infectious keratitis (dark arrow) and the furthest away point of clear cornea (dotted point). B illustrates the Pentacam overview of the corneal ulcer. C shows how to measure the corneal density during the active stage of infection at two different points: the central involved ulcer (central point) and the furthest away point of clear cornea (at the periphery). D shows how the total cross sectional area of the infiltrate was measured. All the measurements were calculated at the same axes.

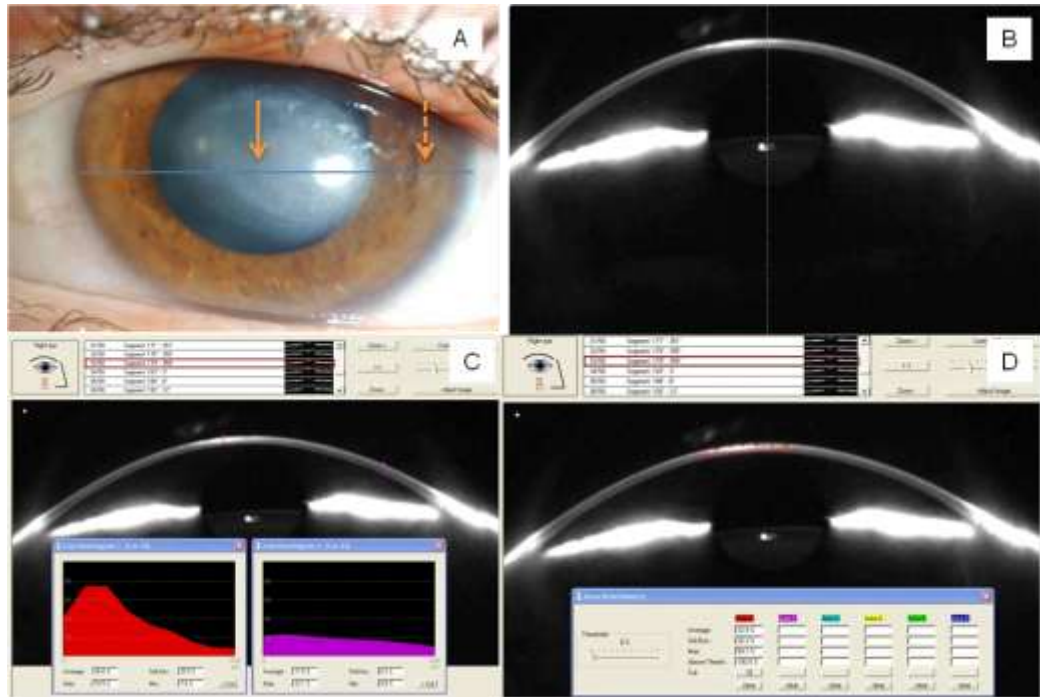


Figure 18 Another example of Densitometry in patient with healed infectious keratitis. A shows the corneal scarring after the full healing of the active ulcer of the previous patient (dark arrow) and the furthest away point of clear cornea (dotted arrow). B reveals the Pentacam overview of the corneal scar. Fig 8C illustrates the densitometry at the central scarring (central point) and at the furthest away point of clear cornea (at the periphery). D shows how the total cross sectional area of the infiltrate was measured. All the measurements were calculated at the same axes.

6.2.3 Statistical analysis

The numerical data obtained from the study points or cross sectional areas were entered in an Excel spread sheet and exported to the SPSS software package (version 16.0 , IBM, Chicago, IL) for statistical analysis. The significance value was set at $P < 0.05$. After testing the normality of the obtained data, the relevant test was performed. The parametric T-test or the non parametric Mann Whitney test were used to compare between 2 independent samples, whereas Wilcoxon test was performed to show the difference between two non parametric

related samples. The correlation between two non-parametric groups was analyzed using Spearman rank test.

6.3 RESULTS

6.3.1 Control group

The mean age of the 40 healthy subjects studied was 35 ± 14 years, (range from 23 to 76 years). Twenty four were males and 16 were females. Of the 64 eyes examined, there were 31 left eyes and 33 right eyes. No statistical relationship was found between gender of the subjects and the values of the densitometry (Man Whitney, $P>0.05$). Additionally, no correlation was found between the densitometry readings and the age of the healthy subjects (Spearman correlation: 0.845, $P>0.05$).

6.3.1.1 Densitometry:

The densitometry values by the two different methods are shown in table 9. The densitometry measured at different points ranged from 9 to 17.4 and the densitometry of total cross sectional area ranged from 10 to 20.5. For the healthy controls, there was no statistical difference between the measurements of the densitometry examined by the two different methods i.e. point measurements and area measurement (Mann Whitney, $P>0.05$). When the densitometry values were compared at different points, there was no statistically significant difference between the upper and lower corneal halves and the nasal and temporal sides. Similarly, no significant difference of the

densitometry readings was observed between the central 3 mm and the peripheral 7 mm. Furthermore, when densitometry values from right and left eyes were compared for the different locations, no statistically significant difference was noted. The Mann Whitney test was used for all comparisons ($P>0.05$).

Table 9 Densitometry values of healthy controls. (N/A: not applicable)

	Average	Maximum	Minimum
Densitometry at different points	12.3 ± 2.4	19±4.4	4.7±0.9
Densitometry of total cross sectional area	12.99 ± 2.58	22± 4.1	N/A

6.3.2 Study group with infectious keratitis

Thirty six eyes of 35 patients were studied (18 left and 18 right eyes) with mean age of 43 ± 13 years, (range from 19 to 84 years). There were 17 males and 19 females. The mean period between the initial and the last densitometry measurements was 51 days (range 35 to 177 days)

There was a statistically significant difference between the mean age of the healthy controls and the patients with infectious keratitis (T-test for 2 independent groups, $P<0.05$).

6.3.2.1 Microbiological Results

Of the 36 eyes studied, corneal scrapes were not done for 3 eyes; 16 showed no growth and the remaining 17 cases showed *S. aureus* (6), *P.*

aeruginosa (3), Gram positive *bacillus* (2), *Moraxella* (1), *kleibsella* (1), *Coliform* (1), *Propionibacterium* (1) *Pneumococcus* (1) and *Acanthamoeba* keratitis (1).

6.3.2.2 Clinical examination

Slit lamp examination of the 36 eyes with infectious keratitis revealed 19 eyes with central corneal infection (within the central 4 mm) and 17 with peripheral lesions. Thirteen of the 36 eyes had deep infectious infiltrates (more than 50% depth). The mean diameter of these infectious infiltrates was 2.5 mm (range 1 to 5.5 mm).

6.3.2.3 Pachymetry

The mean pachymetry was 544 ± 74 μm micrometers (range 372 to 630 μm). There was no correlation between the pachymetry and densitometry readings (spearman rank correlation= 0.057, $P > 0.05$).

6.3.2.4 Densitometries at site of infection

6.3.2.4.1 Densitometry by point method

As shown in table 10, the maximum, minimum and average densitometries values at specific corneal points during the acute infection showed statistically important increase when compared to the values after complete healing (Wilcoxon, $P < 0.0001$ for each comparison).

Table 10 Densitometry measurements at points of infection in both the acute stage and 4-6 weeks after complete resolution.

	Mean	Maximum	Minimum
Densitometry during acute infection	47.6±12	91.8±18	24.6±14.5
Densitometry after complete healing	38.1±13	76.7±23.5	14.2±8

6.3.2.4.2 Densitometry of total cross sectional area of infection

Similarly, the average and maximum densitometries of cross sectional areas during active infection were significantly more than the readings after complete healing (Wilcoxon, $P < 0.0001$) (Table 3).

There was no statistical difference between the densitometries measured at different points (table 10) and of total cross sectional area (table 11) (Mann Whitney, $P > 0.05$).

There was no correlation between the pachymetry and the densitometry values obtained by the point method (spearman correlation: -0.19 , $P > 0.05$). Similarly, no correlation was found between the pachymetry and the densitometry values obtained by the total cross sectional area method (spearman correlation: -0.145 , $P > 0.05$).

The densitometry values from patients were also compared to controls. There was significant increase in the average, maximum and minimum corneal densitometries during active infection compared with the control readings (Mann- Whitney, $P < 0.0001$ for each comparison).

There was no correlation between the densitometry readings and the diameter of the infiltrates (Spearman rank correlation= 0.25, $P > 0.05$) nor was there any significant statistical relationship between the densitometry values and the location or depth of the infiltrates (Mann Whitney test, $P > 0.05$)

Table 11 Densitometry measurements of total cross sectional area of infection in both the acute stage and 4-6 weeks after complete resolution.

	Mean	Maximum
Densitometry during acute infection	58.4±19.5	89.4±17.8
Densitometry after complete healing	33.4±17.3	62.14±25

6.3.2.5 Densitometries at points of furthest away clear cornea

The corneal densitometry values obtained from the clear cornea at a point furthest away from the active infection were significantly lesser than readings obtained from the site of active infection at all stages (Mann-Whitney, $P < 0.0001$) (Table 12). Interestingly, the densitometry readings in the furthest away clear cornea of the infected eye showed a significant increase when compared with healthy controls both during the active infection and after complete healing (Mann-Whitney, $P < 0.0001$) (Table 12). Clinically, the active infiltration was replaced by scar tissue. The clear cornea furthest away from the corneal infiltrate showed significant decrease in densitometry after

complete healing when compared with the values of the same points during the active keratitis (Wilcoxon test, $P < 0.0001$).

Table 12 Shows the corneal densitometry values 1. Of healthy controls and 2. At sites of infectious infiltrates and 3. At points of clear cornea furthest away from the infiltrates; during active infection and 4-6 weeks after complete clinical resolution.

	Mean	Maximum	Minimum
Densitometry of healthy controls	12.3±2.4	19±4.4	4.7±0.9
Densitometry at site of acute infection	47.6±12	91.8±18	24.6±14.5
Densitometry at site of infection after complete healing	38.1±13	76.7±23.5	14.2±8
Densitometry of furthest away point of clear cornea during infection	29±19	47.5±29	8.6±4.9
Densitometry of furthest away point of clear cornea after complete healing	20±11	33.3±22	8.2±5.2

6.4 DISCUSSION

The Pentacam *Scheimpflug* system is a relatively new imaging modality which is superior to slit-lamp photography in many aspects. It can

provide valid and reproducible data in evaluating the entire corneal tissue with minimal examiner experience (Shankar et al., 2008b, Shankar et al., 2008a). It provides precise information about corneal topography, corneal and lens densitometry and the anterior chamber anatomy (Oculus, 2003).

Densitometry of the corneal tissue provides information about the clarity of the cornea. The normal cornea does not absorb visible light and light scatter is minimal. Densitometry therefore gives an indication of the transparency of the cornea. With the Pentacam, densitometry of the whole cornea is possible in a single scan. The density is standardized from 0 to 100. Therefore, 0 means the cornea shows no clouding and 100 means the cornea is completely opaque (Cho et al., 2010). The major sources of light scattering are the anterior superficial corneal epithelial cell layer and the posterior corneal endothelium. As expected from an optically transparent tissue, the normal cornea scatters light predominantly at the air/tear film and tear film/cornea interface where the change in the index of refraction of light is greatest with only minor scattering by structures inside corneal tissue, e.g. nerves and cell nuclei. The corneal stroma maintains its clarity through the regular arrangement of collagen fibrils in a lattice-type structure in lamellar sheets. It is both the spacing of the fibrils within the arrangement and the size of the collagen fibrils that influence clarity (Maurice, 1957, O'Donnell and Wolffsohn, 2004). Moreover, The very precise organization of the extracellular matrix (ECM) surrounding these collagen fibrils can also play a major role in corneal transparency.

The ECM confers unique water-holding properties and preserves the hydration of the corneal tissue within its normal limits.(Fini, 1999, Maurice, 1957) The state of corneal hydration (which is maintained at 75%) is another important factor in corneal transparency (Daxer et al., 1998, O'Donnell and Wolffsohn, 2004).

In bacterial keratitis, the cornea is invaded with inflammatory cells and microbes and swells. Light scatter increases with a loss in transparency due to the disruption of the collagen matrix caused by the inflammation and infection (Fernando H Murillo-Lopez, 2010). After healing of infectious keratitis, the resultant corneal scarring is another significant cause of reduced corneal transparency.

To our knowledge, the evaluation of corneal densitometry as a measure of corneal transparency has not been reported in the literature. In this study we established the densitometry of normal corneas and also used the technique to obtain quantitative data in patients with corneal infections. This enabled us to objectively measure progress or response to therapy. We found that the average corneal densitometry of the healthy controls is 12.99 ± 2.58 and 12.3 ± 2.4 using two different methods of analysis. It did not correlate with age and gender. These normal values could be used as bench marks for future studies undertaken to evaluate corneal pathology. In infectious keratitis, the corneal stroma in the area of infection swells and undergoes necrosis and the keratocytes shows apoptosis as a protective phenomenon against the infective organisms (Vemuganti et al., 2004). Depending on

microbial toxins and pro-inflammatory cytokines released, acute inflammatory cells (mainly neutrophils) surround the site of infection causing necrosis of the stromal lamellae and ulceration. Different bacterial toxins and enzymes (including elastase and alkaline protease) may be produced during corneal infection, contributing to the destruction of corneal tissue (Fernando H Murillo-Lopez, 2010, Vemuganti et al., 2004).

In normal controls, the total densitometry value is made up of epithelial, stromal and endothelial reflectivity, of which the epithelial component has the greatest contribution. In our study, all patients had corneal ulcers and hence were lacking the epithelial layer. Despite this the total densitometry values were still higher in areas of infection. Moreover, when the minimum densitometry values, which indicate stromal reflectivity, of patients and controls are equated, a more valid comparison can be made. The stromal reflectivity of patients' corneas was much higher than that of controls.

We found that, although densitometry values were greatest at the site of active infection/infiltration, the values were also increased, compared to controls, at areas of clear cornea furthest away from the infection. This increase was statistically significant when compared to normal controls. This suggests that a much wider area of the cornea, if not the entire cornea is affected by the infective focus and responds dynamically to the insult at any specific site. This could be related to an increase in host inflammatory cells in the corneal tissue as they migrate

from the limbus towards the focus of infection and also to the 'activation' of stromal keratocytes in an infected cornea. Studies on patients undergoing refractive surgery have reported keratocyte activation, which can persist for months after the intervention (Vesaluoma et al., 2000, Moilanen et al., 2003, Erie, 2003, Erie et al., 2003). Interestingly though the densitometry at a point of clear cornea furthest away from the involved area declined as the infection resolved, it continued to show increased values, compared to controls, even after complete healing of the ulcer. This suggests that the effects of infection persist beyond 4 weeks after clinical healing and factors such as keratocyte activation and disappearance of invading white cells take longer to return to normal. Thus clinically visible resolution of signs may not correspond with a return to complete physiological normality, which is likely to take longer. We expect that over time the densitometry of the cornea at points furthest from the infiltrate will return to normal but a longer follow up will be required to ascertain this.

In some patients, pre-existing changes related to corneal transplantation for example, could also have contributed to this persistent increase in densitometry values. Similarly, in our study, the values of corneal densitometry of the scarred areas after complete healing were statistically more than the values of the controls. The lack of the corneal clarity in the affected areas is attributed to the scar formation with an increased number of scar keratocytes (fibroblasts), change in extra cellular matrix composition, increase in the number of

collagen fibrils and the irregular order of these fibrils (Fini, 1999, Vemuganti et al., 2004). After corneal healing, there is a change in collagen from the original type I collagen (25–30 nm) to type III collagen that is typically present in an area of corneal haze or scarring and has a larger fibre diameter (30–50 nm) (Anderson et al., 1996, SundarRaj et al., 1990). These larger and irregular stromal fibrils can cause an increase in the amount of light scatter. The corneal light scattering resulting from the scarring was less than the scattering related to active infection. This is likely to be due to the elimination of inflammatory cells and the microbial colonies.

No correlation between the pachymetry and the densitometry values was found. This is probably because of the fact that there were several cases where the affected area was thin with surrounding infiltration or abscess. The overall densitometry readings were thus very high despite the low pachymetry.

The main limitations of our study were the short period of follow up after complete healing of the infectious keratitis and the small number of the healthy controls. Additionally, the significant difference between the age of the healthy controls and the patients with infectious keratitis was another drawback although our statistical analysis showed that there was no correlation between age and densitometry readings. The Pentacam instrument itself was limited in capturing reliable images in some patients who had frequent blinking, photophobia, excessive tearing or discharge and poor cooperation or fixation.

Light scattering from active infectious corneal infiltrates is more than that resulting from the corneal scarring after healing. Subclinical activation of the keratocytes and/or inflammation in clear cornea furthest away from the corneal infection suggests that the host response extends far beyond the immediate area of infection and indeed may occur through the entire cornea. These changes persist beyond 4 weeks, which was the duration of follow up of this study.

CHAPTER SEVEN

7 Profile of Sight Threatening Infectious Keratitis: A Prospective Study

7.1 INTRODUCTION

Infectious keratitis is an avoidable and treatable sight-threatening disease that can affect the young and old alike. Despite improvements in treatment, infectious corneal ulcers remain a threat with the potential for permanent and severe visual loss adding to the social and healthcare burden of the individual and the community. The morbidity from severe corneal ulcers (loss of vision, duration of hospital stay and surgical intervention) (Wong et al., 2003) is totally different from that of mild corneal infections. Demographic and geographic factors affect the distribution of the causative organisms of infectious corneal ulceration. Regional differences can be considerable and diagnostic and therapeutic resources have to be tailored to the specific needs of a given region. Moreover, the profile of organisms, drug efficacy and resistance change over time necessitating standard protocols of diagnosing and treating infectious keratitis to be reviewed regularly. Comprehensive studies of severe sight threatening infectious keratitis are therefore important as they provide useful information on the predisposing factors, aetiology and visual outcomes thus informing the

development of management strategies and protocols. In this regard, prospective studies are more valuable as they provide detailed information on the current profile of the disease.

We have conducted a prospective study of the sight threatening infectious keratitis in Nottinghamshire, England over a period of 3 years. The aim was to ascertain the incidence, demography, predisposing factors, clinical and microbiological diagnosis, treatment given, follow up duration, visual outcomes and complications in patients with severe infectious corneal ulceration.

7.2 METHODS

This study followed the Tenets of the Declaration of Helsinki and was approved by the Queens Medical Centre, University Hospitals NHS Trust (No. 1487). All patients who were diagnosed with severe corneal infections at the Queens Medical Centre, Nottingham, UK, under the care of two consultants, between Sep 2007 and Sep 2010 were recruited in this study. Informed consent was obtained from all patients. Severe corneal ulcers were defined as sight threatening corneal infections that needed to be treated intensively and urgently, this included at least one of the following criteria: remarkable visual loss without any other attributable cause, part of the lesion within the central 4 mm of the cornea, peripheral location with more than 2 mm diameter, any hypopyon or significant pain (Keay et al., 2008, Dart et al., 2008). Viral infections were excluded. The following data were obtained from all subjects: personal details, duration of symptoms,

date of admission (if applicable) and previous treatment (if any). The predisposing factors, initial visual acuity (VA), ocular signs, medical treatment including drugs, dose and duration, length of hospital admission (if applicable), any surgical intervention, complications and final visual outcome, were recorded for all patients. Corneal scrapings when undertaken, the culture results and whether tested sensitivities affected the course of treatment were also noted. Corneal scrapings were smeared on to glass slides for gram stain and inoculated on to agar plates (blood agar, chocolate agar and Sabouraud dextrose agar) for microbiological culture. Special media made of non-nutrient agar plates inoculated with E coli were used when *Acanthamoeba* keratitis was suspected. All cultures were incubated for at least one week (up to 3 weeks in *Acanthamoeba* keratitis).

All visual acuities were measured using LogMar recordings. Visual acuity of counting fingers (CF), hand movements (HM), light perception (LP) and no light perception (NLP) were recorded as LogMar values of 1.7, 2, 4 and 5 respectively (Steinberg et al., 1994, Wong et al., 2003).

SPSS software version 16 (IBM, Chicago, IL) was used for statistical analysis in this study. The seasonal variation was analysed using one way ANOVA test and Benferroni correction. Patients were divided into two groups; bacterial keratitis and *Acanthamoeba* keratitis. Mann Whitney test was used to compare the healing period between the AK and BK groups, whereas Wilcoxon test was performed to report the change of the VA after treatment. Correlation between the prolonged

healing period in relation to age and poor presenting VA was evaluated using bivariate correlation. Cox Regression test was used to examine the effect of the predisposing factors, sex, previous steroids use, location, depth and diameter of the ulcer on the time taken to complete healing.

7.3 RESULTS

7.3.1 Demographics

A total of 143 eyes of 129 patients were studied. There were 55 left (38.4%), 60 right (41.9%), and 14 bilateral (9.7%) cases. Females and males were equally distributed; 66 Female (51.1%) and 63 males (48.8%). The average age was 52.8 years (SD= 22.1) ranging from 9 to 99 years.

7.3.2 Seasonal variations

Interestingly, there were more corneal infections during summer time (June, July and August) compared with other seasons. The number of cases during summer time was significantly higher than the number during autumn ($P= 0.041$). The detailed seasonal variation of incidence is shown in table 13.

Table 13. Seasonal distribution of the severe infectious keratitis in Nottinghamshire in Autumn (September, October and November), Winter (December, January and February), Spring (March, April and May) and Summer (June, July and August).

2007				Autumn
				6
2008	Winter	Spring	Summer	Autumn
	8	16	21	8
2009	Winter	Spring	Summer	Autumn
	7	10	19	6
2010	Winter	Spring	Summer	
	10	8	11	

The time interval between awareness of first symptoms and presentation to hospital ranged from 0 to 33 days, median= 3 days (average= 4.97, SD= 5.64).

Thirty one patients were managed as out-patients and 98 were admitted for in-patient treatment. The period of admission ranged from 2 to a total of 45 days, (median= 6 days and mean= 9±13 days). Seventy five percent of patients with longer period of hospital stay (more than 9) days were over 60 years old. The total period of treatment ranged from 5 to 875 days, median= 45 days (The longer period of treatment was among *Acanthamoeba* keratitis patients, ranged from 95 to 875 days, median= 154 days, whereas the median period of management of bacterial keratitis was 33.5 days ranging from 5 to 280 days).

7.3.3 Microbiology

Corneal scrapings were done for 127 of the 143 eyes. 53 (41.7%) eyes showed positive growth and 74 (58.26%) eyes revealed no growth. Sixteen eyes were not scraped. Twenty six eyes (49%) yielded gram positive bacteria, 18 (33.9%) had gram negative bacterial infections and 9 (16.9%) demonstrated *Acanthamoeba*. Details of the organisms isolated are elaborated in table 14.

Table 14. Isolated organisms by culture (Mixed corneal infections were seen in 5 cases; *Staphylococcus aureus* with *Moraxella* and *Diphtheroids*, *Acanthamoeba* with *Aspergillus*, *Pseudomonas aeruginosa* with *Streptococcus G*, *Pseudomonas aeruginosa* with *Staphylococcus epidermidis* and *Propionibacteria* with *Corynebacteria*) (CL: Contact lens, HSK: Herpes simplex keratitis, OCP: Ocular cicatricial pemphegoid)

Causative organism	Number of eyes (out of the total 53 eyes)	Predisposing factors
Amoeba		
<i>Acanthamoeba</i>	9 (16.9%), 3 cases of which were bilateral	4 Monthly & 3 daily disposable CL 2 None
Gram Positive Bacteria		
<i>Staphylococcus aureus</i>	10 (18.8%)	3 Suture related abscess 2 Immunosuppression 1 Severe blepharitis 1 Failed graft 1 Atopic Keratoconjunctivitis 1 Recurrent HSK 1 dry eye & monthly CL
Pneumococcus	5 (9.4%)	2 Severe dry eye 1 HSK 1 Suture related abscess 1 Pseudophakic Keratopathy
<i>Staphylococcus epidermidis</i>	4 (7.5%)	1 Recurrent HSK 1 Neurotrophic keratopathy 1 Dry eye 1 Failed PK & stem cell failure
<i>Corynebacteria diphtheroides</i>	4 (7.5%)	2 Failed PK 1 Spastic entropion, 1 OCP
<i>Propionibacteria</i>	2 (3.7%)	1 Failed PK & ectropion 1 Monthly disposable CL
<i>Streptococcus viridans</i>	1 (1.8%)	1 Recurrent HSK

Gram Negative Bacteria		
<i>Pseudomonas aeruginosa</i>	8 (15%)	3 Monthly CL wear 1 Suture related abscess 1 Pseudophakic keratopathy 1 Ramsay Hunt, corneal 1 Failed corneal graft 1 Recurrent HSK
<i>Moraxella</i>	3 (5.3%)	1 Recurrent corneal erosions 1 Suture related abscess 1 Immunosuppression
<i>Haemophilus influenza</i>	2 (3.7%)	1 Immunosuppression 1 None
<i>Coliform</i>	2 (3.7%)	1 Monthly CL wear 1 Exposure keratopathy
<i>Stenotrophomonas maltophilia</i>	1 (1.8%)	1 Failed corneal graft
<i>Kingella Kingae</i>	1 (1.8%)	1 Monthly disposable CL
<i>Klebsella</i>	1 (1.8%)	1 Pseudophakic bullous keratopathy

7.3.4 Predisposing factors:

Ocular surface disease was the most common predisposing factor (32.8%). In this respect, a background of HSK was the main risk factor (almost half of the cases with ocular surface disease). CL wear and previous ocular surgeries were also common being 26.5% and 20.2% respectively. Chronic topical steroids use was a shared risk factor in 40% of cases. The predisposing factors and their detailed distribution are shown in table 15.

Table 15. Predisposing factors of the severe corneal infections (HSK: Herpes simplex keratitis, OCP: Ocular cicatricial pemphegoid, HZO: Herpes zoster ophthalmicus)

Predisposing factor	No. (%) out of 143 eyes	Total. (%) out of 143 eyes
Ocular Disease	20 (13.9%) Recurrent HSK 8 (5.5%) Bullous keratopathy 5 (3.4%) Dry eye 6 (4.1%) Blepharitis 3 (2%) Neurotrophic keratopathy 2 (1.4%) OCP 2 (1.4%) Neovascular glaucoma 1 (0.7%) HZO	47 (32.8%)
Contact Lens Wear (7 bilateral cases)	31 (21.6%) Monthly disposable 7 (4.8%) Daily disposable	38 (26.5%)
Previous Ocular surgery	10 (6.9%) Failed corneal graft 11 (7.7%) Corneal suture related 2 (1.4%) Exposed lid sutures related 4 (2.8%) Cataract 2 (1.4%) Glaucoma	29 (20.2%)
Eyelids abnormalities	3 (2%) Ectropion 2 (1.4%) Entropion 4 (2.8%) Exposure	9 (6.3%)
Corneal trauma	1 (0.7%) Foreign body related 3 (2%) Chemical burn	4 (2.8%)
Systemic diseases	2 (1.4%) Malignancy 2 (1.4%) Rheumatoid arthritis 2 (1.4%) Graft versus host disease 1 (0.7%) Hepatitis C 1 (0.7%) Liver failure 1 (0.7) Immunosuppressive drugs 1 (0.7%) Diabetes	10 (7%)
Mixed factors	1 (0.7%) Failed graft with ectropion 1 (0.7%) Failed graft with recurrent HSK	2 (1.4%)
Unknown cause	4 (2.8%)	4 (2.8%)
Chronic topical steroids use	57 (40%)	57 (40%)

7.3.5 *Acanthamoeba* Keratitis

There were 17 cases treated as *Acanthamoeba* keratitis (12 cases with monthly disposable CL, 3 with daily disposable CL and 2 with unknown predisposing factors). Out of these, 9 cases were culture proven and 8 cases were clinically suspected and confirmed by *in vivo* confocal microscopy. In all cases of culture positive *Acanthamoeba*, it showed images with morphology of *Acanthamoeba* cysts.

7.3.6 Clinical Signs

Central location of the keratitis was noted in 51% of patients (all *Acanthamoeba* keratitis and *pneumococcal* infections and in 7/8 of *P. aeruginosa* infections. Additionally, 7/8 of *P. aeruginosa* cases, 5/10 of *S. aureus* and 3/5 of *Pneumococcus* showed deep infiltration into the stroma. Diffuse superficial punctuate keratopathy was the main sign of all *Acanthamoeba* keratitis that presented at an early stage, whereas deep central infiltration with > 6 mm diameter was the feature in *Acanthamoeba* keratitis cases that presented at a late stage. Hypopyon was seen in 37.6% of cases, (6/8 of *P. aeruginosa*, 4/4 of coagulase negative cocci, 4/5 cases of *Pneumococcus* and 6/10 of *S. aureus*). There were 9 cases with plaque hypopyon (3/10 of *S. aureus*). The relevant clinical signs of all cases with microbial keratitis are shown in table 16.

Table 16. Clinical signs of microbial keratitis. *Acanthamoeba keratitis* cases comprise all clinically and culture positive cases (17 cases) (Gram-/+ : Gram negative or positive bacteria, AK: *Acanthamoeba keratitis*, SA: *Staphylococcus aureus*, PA: *Pseudomonas aeruginosa*, SP: *Streptococcus pneumonia*, SE: *Staphylococcus epidermidis*, SPK: *Superficial punctuate keratopathy*)

Signs N (%)		Gram-	Gram+	Acanthamoeba	No growth	No scrape	Highlights
Location of the ulcer	Central 73 (51%)	15	13	17 (9 culture positive)	26	2	All AK and SP infections and 7/8 of the PA cases were central
	Peripheral 70 (49%)	11	5	0	40	14	
Depth of the ulcer	Deep 53 (37%)	9	12	7 (5 culture positive)	20	5	7/8 with PA, 5/10 with SA and 3/5 with SP showed deep corneal infiltrate
	Superficial 90 (63%)	17	6	10 (4 culture positive)	46	11	
Size	< 3mm, 56 (39%)	5	7	0	39	5	
	> 3mm< 6mm, 54 (37.7%)	10	15	2 (2 culture positive)	22	5	
	>6mm, 20 (14%)	3	4	5 (4 culture positive)	5	3	All the 5 AK cases were at late stage with stromal involvement
	No epithelial defect, 13 (9%)	0	0	10 (3 culture positive)	0	3	Diffuse SPK were the main sign in all AK cases at early stage
AC reaction	Hypopyon 54 (37.6%)	11	14	4	18	0	6/8 with PA, 4/4 with SE and, 4/5 with SP and 6/10 with SA.

7.3.7 Complications

All subjects with AK required a prolonged period of treatment (median= 154 days, ranged from 55 to 875 days). In addition, all *Pneumococcal* and most *P. aeruginosa* patients showed a refractory course. Melting and thinning were seen in 35 patients (14 had infectious keratitis on a recurrent HSK background, of which 8 developed globe perforation). Most *Pneumococcal* infections were associated with melting and thinning. Serious ocular complications due to infectious keratitis are given in table 17.

Table 17. Complication of severe microbial keratitis (AK: *Acanthamoeba keratitis*, SA: *Staphylococcus aureus*, PA: *Pseudomonas aeruginosa*, SP: *Streptococcus pneumonia*, SE: *Staphylococcus epidermidis*, HSK: *Herpes simplex keratopathy*, BK: *Bullous keratopathy*)

Complications	N out of 143 (%)	Highlights
Refractory course of treatment (more than the median= 45 days)	70 (48.9%)	17/17 AK 5/5 SP 7/8 PA [28 had ocular surface disease (10 HSK), 22 CL wearer and 16 with previous eye surgery]
High IOP	9 (6.2%)	2/9 AK
Melting and thinning	35 (24.4%)	4/17 AK 4/5 SP 4/8 PA 2/3 Moraxella (14 cases had history of recurrent HSK)
Perforation	14 (9.8%)	8 Recurrent HSK
Deep corneal neovascularization	16 (11.1%)	4 Recurrent HSK 3 BK
Bullous Keratopathy	2 (1.4%)	2/17 AK
Cataract	4 (2.8%)	2/17 AK
Recurrent infection	7 (4.9%)	
Choroidal detachment	1 (0.7%)	

7.3.8 Visual acuity change

In the *Acanthamoeba* keratitis group, there was no significant difference between the mean VA before and after the treatment (Initial

and final VA were 0.5 ± 0.6 and 0.6 ± 1.3 , respectively, $P= 0.65$). In BK group, there was statistically significant improvement in the mean VA after the treatment (initial and final VA were 1.4 ± 1.3 and 1.3 ± 1.4 , respectively, $P= 0.015$) (Wilcoxon test was used in the analysis). Six cases ended up with NPL because of total cupping of the optic nerve discs (4 cases referred from other hospitals).

7.3.9 Period of healing:

7.3.9.1 The effect of multiple factors on the period of healing

The effect of multiple variants (central location, depth, diameter of the ulcer, predisposing factors, sex and steroid use) on the healing period was studied using the Cox regression test in the *Acanthamoeba* and bacterial keratitis groups.

In the AK group, the central and deep location of the infection correlated with prolonged treatment ($P= 0.035$ and 0.022 respectively), whereas the deep location and the previous use of steroids were statistically important factors on the treatment period in the BK group ($P= 0.0001$ for both).

7.3.9.2 Correlation between the old age and the initial VA and the period of healing

There was strong positive correlation between the prolonged course of management and the old age ($R=0.3$, $P=0.001$, Spearman) and poor

initial VA ($R=0.4$, $P=0.0001$, Spearman) in the bacterial keratitis group. *Acanthamoeba* keratitis patients showed no such correlation.

7.3.9.3 Healing period in the *Acanthamoeba* keratitis and BK group

When compared with the BK patients, AK group by itself was a risk factor for refractory and prolonged period of therapy in our study ($P=0.0005$; Mann Whitney).

7.3.10 Treatment

7.3.10.1 Medical Treatment

All patients received antibiotics as the first line treatment either individually or as a combination with other eye drops. The detailed protocols of treatment are elaborated in table 18.

Table 18. Medical treatment of severe infectious keratitis (AK: Acanthamoeba keratitis, BK: bacterial keratitis, HSK: Herpes simplex keratitis)

Treatment	Medication	Number of cases (n=143) (%)	Highlights
Bacterial keratitis	Topical fortified cefuroxime (10%) & gentamicin (1.5%)	n=79 (61.2%)	
	Topical ciprofloxacin	n=24 (18.6%)	
	Topical chloramphenicol	n=3, 2 (32%),	
	Topical ofloxacin	n=3, 2 (32%)	
	Topical fortified vancomycin(25mg/ml) & gentamicin(1.5%)	n=2 (1.55%)	
	Topical levofloxacin	n=1 (0.77%)	
Acanthamoeba keratitis	Topical polyhexamethylene biguanide (PHMB) (0.002%) and Brolene (0.1%) (With or without Chlorhexidine 0.002%)	n=17 (13%)	Antibiotics was always used in addition to the disinfectants in the management of the AK
Adjunctive treatment	Systemic Acyclovir	n= 24 (16.7%)	20 with BK with HSK background, 3 AK and 1 no growth
	Topical and systemic Antifungal agents such as econazol and amphotrecin B	n= 4 (2.8%)	2 BK and 2 AK (1 mixed infection of AK & Aspergillus).
	Topical lubrication	n= 52 (36.4)	
	Topical cyclopentolate 1%	n= 109 (76.2%)	
	Topical steroid	n= 25 (17.5%)	After initial treatment with antibiotics when clinical signs of response were observed

7.3.10.2 Surgical procedures

A number of surgical procedures were required in our patients. These were related to the lids, puncta, lacrimal sac, cornea and eye pressure

control. Details of surgical procedures and their indications are given in table 19.

Table 19. Therapeutic interventions in refractory microbial keratitis. Therapeutic interventions in refractory microbial keratitis (AK: Acanthamoeba keratitis, SA: Staphylococcus aureus, PA: Pseudomonas aeruginosa, SP: Streptococcus pneumonia, SE: Staphylococcus epidermidis, HI: Haemophilus influenza, DCR: Dacryocystorhinostomy, FNDI: Fine needle diathermy, AMT: Amniotic membrane transplantation)

Procedure	Indication	N (%)	Highlights
Corneal gluing	Corneal perforation	14 (9.7%)	8 recurrent HSK
Corneal biopsy	Acanthamoeba suspicion with poor response to treatment	4 (2.8%)	2 AK
Conjunctival hooding	perforated infectious ulcer	3 (2%)	1 HI, 1 SA and 1 PA
Stromal puncture	Bullous keratopathy	1 (0.7%)	1 PS
FNDI	To treat lipid keratopathy or intra or preoperative for PK	4 (2.8%)	
Cataract extraction	To improve the vision	6 (4.2%)	3 AK
Hot grafts	Therapeutic grafts	5 (3.5%)	Out of the 12 grafts, 10 grafts remained clear
Cold grafts	To improve the vision	7 (4.9%)	
AMT	Non healing epithelial defects	8 (5.6%)	
Inferior punctual plugs	Severe dry eyes and non-healing epithelial defects	7 (4.9%)	
Tarsorrhaphy	Non healing epithelial defects	7 (4.9%)	
Botox Injections	Non healing epithelial defects	6 (4.2%)	
Ahmed valve	Uncontrolled IOP	1 (0.7%)	
Diode laser	Uncontrolled IOP with poor VA	1 (0.7%)	
DCR	Recurrent corneal infection and dacryocystitis	1 (0.7%)	
Eyelid correction	2 Entropion 2 Ectropion	4 (2.8%)	

7.4 DISCUSSION:

This prospective study recruited 129 consecutive patients (143 eyes) with sight threatening corneal infections over a period of three years in Nottinghamshire area. This is the first study of this kind for Nottinghamshire and should serve as a reference base for future such studies in time to come. There was a peak of incidence during summer time (June, July and August). One other UK based study has reported a similar peak incidence in the summer months (Ibrahim et al., 2009).

As expected, most cases were unilateral. Corneal infections constitute the major cause of unilateral blindness in the world (Whitcher et al., 2001). However, in our study we also had 14 bilateral cases, of which, 7 were contact lens wearers. In addition, 31 of the unilateral cases were contact lens wearers highlighting contact lens wear as an important risk factor for unilateral and bilateral infectious keratitis.

The average period of symptoms before presentation was 4.97 ± 5.64 days [mean \pm standard deviation (range <1 to 33 days)]. This contrasts with the reported periods in New Zealand of 8.9 ± 15.5 days (Wong et al., 2003) and India of 2-5 weeks (Panda et al., 2007). These differences could relate to cultural issues, social and financial status, awareness, distance to nearest eye care facility and other issues. Among the 98 patients who were admitted for intensive treatment the mean period of admission was 9 ± 13 days (range 2 to 45 days) which corresponds to a similar retrospective study carried out in France in

which 300 cases were recruited, where the mean stay was 9 days ranging from 3 to 60 days (Bourcier et al., 2003). In another study in New Zealand the mean in-patient stay was 5.8 days. (Wong et al., 2003) The New Zealand study was retrospective, included 103 cases presenting over 2 years with only one case of *Acanthamoeba*. Our mean stay of bacterial keratitis patients (87% of cases) (excluding *Acanthamoeba*) was 8.4 days. Saeed et al reported a lower average of 6.3 ± 4.2 days of in-patient stay in Ireland. This study too was retrospective, carried out over two years and included 90 cases. Six percent of their cases were due to *Acanthamoeba* infection (Saeed et al., 2009). *Acanthamoeba* keratitis patients and older age group patients in general tend to have a longer hospital stay and a more prolonged course of treatment.

The duration of therapy required can be quite variable depending on the time to presentation, causative organism and patient's general and ocular health. In our study the course of management extended over a median of 45 days ranging from 5 to 420 days. In one patient with *Acanthamoeba* keratitis, treatment was given off and on, extending over 875 days culminating in a corneal graft. However, when *Acanthamoeba* keratitis patients were excluded, the median period of management of bacterial keratitis was 33.5 days ranging from 5 to 280 days which corresponds with another French study (Bourcier et al., 2003).

The follow up period was much longer than another UK study (average 11.5 days, range 7-42 days) (Ibrahim et al., 2009) mainly because of the bias towards recruiting severe cases of BK in our study. The median period of *Acanthamoeba* keratitis treatment in our study was 192 days which correlates with that reported in the literature (Dart et al., 2009).

According to published reports, microbiological culture from corneal scrapes reveals positive results in only 52% to 65% of cases (Garg, 2010). In our study, only n=53 (41%) showed positive cultures, whereas n=74 (58.26%) returned with no growth. The positive culture yields in the UK have been variously reported in different studies. Rates of 19%, 39%, 60% and 63.8% have been reported (Dart et al., 1991, Saeed et al., 2009, Dart, 1988, Ibrahim et al., 2009). In the latter two studies the liquid medium of brain heart infusion (BHI) culture medium was used in conjunction with the agar plates for microbial isolation. Using agar plates instead of BHI to inoculate the corneal sample in our study could be a possible explanation for our low isolation rate. Schaefer et al have previously reported that 90% of the positive cultures were in BHI medium, whereas only 53% were positive in agar plates (Schaefer et al., 2001). However, our results correlates with another recent study form Germany which has reported a positive culture rate of 43% (148/346) although they have used both BHI and agar plates for bacterial recovery (Prokosch et al., 2011). Equally one can also make a more positive comment that despite the low culture rates, we were successful in treating the infection with our choice of antibiotics in almost all cases of bacterial keratitis. This suggests that

using two broad spectrum antibiotics with efficacy against gram positive and gram negative organisms is a sound practical approach. We also feel that besides choice of the correct medium for culture, attention to some detail could improve culture results. These include the following: removal of all discharge from the ocular surface prior to scraping; scraping from the advancing edge of the ulcer; taking an adequate amount of sample from multiple sites (in big ulcers); ensuring that culture plates and tubes cover a range of microbes (including aerobic and anaerobic bacteria, fungi and mycobacteria if suspected) and are brought to room temperature (warm) before inoculating samples and not placed back in the refrigerator; avoiding delay between inoculation and transport to appropriate incubator in the microbiology facility; liaising with the microbiologists to ensure that samples are adequately handled and having a dedicated ocular microbiologists who has experience in handling small samples as are often obtained from the cornea

Treatment with antibiotics prior to corneal scraping can affect culture positive rates. The culture negative cases in our study were 74 (58 %). Of these, 11 had topical antibiotic treatment prior to scraping. Nevertheless, all drops were stopped for 24 hours prior to scraping. Thus factors other than pre-scrape antibiotic therapy can influence culture positive/negative rates. We also did not find any difference in the various pre-disposing factors between culture positive and negative cases with regard to CL wear, HSK, previous surgery, and other predisposing factors. The clinical signs showed no difference compared

with the culture positive cases. The response to treatment too was not different. The median period to healing in cases with culture negative results was 43 days, which was not different from that of eyes with culture positive results ($P > 0.05$; Mann Whitney)."

In our culture positive group, the commonly isolated organisms were *S. aureus*, *P. aeruginosa* and *Acanthamoeba* with positive culture results in 10, 8 and 9 out of the overall 53 culture positive cases, respectively where culture samples were taken. Together, they formed 53% of the isolated microbes. The similar positive rate between the *S. aureus* (19%), *P. aeruginosa* (15%) and *Acanthamoeba* species (17%) was unexpected. In most studies *P. aeruginosa* and *S. aureus* have been shown to be the most common isolated organisms but not the *Acanthamoeba*. This could be as a result of a growing tendency towards use of soft CL but is more likely related to the tertiary referral nature of patients attending with severe keratitis thus increasing likelihood of the diagnosis of *Acanthamoeba*. *S. aureus* and *P. aeruginosa* but not the *Acanthamoeba* seem to be important organisms isolated in many other UK studies, where they formed half of the isolated organisms. (Saeed et al., 2009, Dart, 1988) However, this was not the case in another UK study where the *Acanthamoeba* and *Staphylococcus epidermidis* formed 35% (Seal et al., 1999) and 32% (Ibrahim et al., 2009) of the patients respectively.

Mixed corneal infections were seen in 5 cases. Four of these patients were over 60 years old and had a refractory course of treatment with

poor visual outcome. Such a correlation between the old age and the mixed corneal infections has not been commented upon before.

Ocular surface disease was the most common predisposing factor in our study (32.8%) as has also been reported by Pachigolla and Schaefer (Pachigolla et al., 2007, Schaefer et al., 2001). CL wear and previous ocular surgery were the second and third common predisposing factors in 26.5% and 20.2% of cases respectively. In the CL group 18.5% were daily disposable CL wearers and 81.5% were 2 to 4 weekly disposable CL users. There was association between *Acanthamoeba* keratitis and the CL wear, as 15 out of 17 cases who were treated as *Acanthamoeba* keratitis were CL users with a predominance of the monthly disposable CL (73.3%). Interestingly, CL wear was reported in only one case of the 10 with *S. aureus* keratitis and in 3 cases of the 9 with *P. aeruginosa* keratitis. This correlation between keratitis due to *P. aeruginosa* and *Acanthamoeba* and the use of CL has been well documented (Panjwani, 2010, Willcox, 2007). Schaefer et al have shown the weak correlation between the CL wear and *S. aureus* corneal infection (Schaefer et al., 2001). The most frequent risk factors for large infectious corneal ulcers (more than 6 mm) were CL wear (23.5%), bullous keratopathy (23.5%), stem cell failure (17.6%) and failed corneal grafts (11.7%). The commonest isolated organisms in this category were *Acanthamoeba* (29.4%), *S. aureus* (17.6%) and *P. aeruginosa* (11.7%). All the *Acanthamoeba* cases were at late stage of the stromal infiltration. Large epithelial defects in such a setting could be due to the compounding effect of topically applied disinfectants and

antibiotics. (Dart et al., 2009) Most corneal infections with *P. aeruginosa*, *Pneumococcus*, *S. aureus* organisms and all with *Staphylococcus epidermidis* infection showed hypopyon. Plaque hypopyon was found mainly among cases with *S. aureus* infections. Of the 5 cases of *Pneumococcus* keratitis, 4 presented with thinning and melting. This was the largest single etiological group amongst the 35 cases of melting and thinning suggesting that *pneumococcal* infection is an important risk factor for corneal melts in addition to the *P. aeruginosa* and *Acanthamoeba*. Seventy patients showed refractory course of treatment which lasted for more than 45 days (the median period for management in our study). Ocular surface disease (mainly HSK and bullous keratopathy), previous eye surgery and CL wear were the main predisposing factors in this setting. In addition, all subjects with *Acanthamoeba* keratitis and *Pneumococcal* keratitis and almost all the *P. aeruginosa* cases fell in this category. The severe nature of corneal infection with *Pneumococcus* and *P. aeruginosa* has been previously demonstrated in a similar study (Wong et al., 2003). The refractory and prolonged course of treatment in *Acanthamoeba* keratitis has also been well documented. (Dart et al., 2009, Kashiwabuchi et al., 2008) In conformity with another study (Constantinou et al., 2009), elderly people with bacterial keratitis required a prolonged course of management. Similarly, poor initial VA correlated with a refractory course and prolonged treatment in the BK group. *Acanthamoeba* keratitis patients showed no such correlation. Moreover, *Acanthamoeba* keratitis as a disease was a risk factor for refractory and prolonged

period of therapy when compared with bacterial keratitis. Deep corneal infections are known to follow a severe and refractory course of infection requiring prolonged management. (Bourcier et al., 2003) In our study, deep infiltrates were associated with a protracted healing period with more than 84% of the patients with deep infectious keratitis demonstrating a prolonged course to resolution.

Most of the predisposing factors seemed not to significantly affect the period of healing. However, previous chronic steroid use in association with ocular surface disease was a significantly important factor, Indeed, it was a shared predisposing factor in 40% of cases. Most cases associated with chronic steroid use had a refractory course of bacterial keratitis with poor visual outcome. The association of topical steroid usage and ocular surface disease in prolonging the duration of management and poor visual outcomes has previously been highlighted. (Wong et al., 2003, Bourcier et al., 2003)

Previous HSK was the main risk factor for corneal perforation (57%) and deep corneal neovascularisation (56%). Herein, the main indication for corneal gluing was infectious keratitis with previous HSK (57% of cases). The visual morbidity resulting from recurrent HSK keratitis can lead to corneal scarring, thinning and neovascularisation which may determine the outcome of any subsequent bacterial corneal infection (Kaye and Choudhary, 2006).

Topical fortified cefuroxime & gentamicin or ciprofloxacin as a monotherapy have been shown to have a positive impact on severe

infectious keratitis. (Gokhale, 2008) These drugs were the major treatment modalities for all bacterial keratitis cases in our study. There were 5 cases that were initially treated as viral infection and then switched to other regimes. The pseudo-dendritic epitheliopathy of the *Acanthamoeba* keratitis which could be misdiagnosed as viral keratitis has been previously reported. (Dart et al., 2009, Tanhehco and Colby, 2010) Anti *Acanthamoeba* agents (PHMB & brolene with or without chlorhexidine) and antibiotics were used in all *Acanthamoeba* keratitis cases.

Corneal grafting had been done for a total of 12 patients (7.7%). Five patients underwent therapeutic corneal grafting for non-healing corneal infection (2 with *Acanthamoeba* keratitis, 1 with *Pneumococcal* keratitis and 2 with no growth) and 7 had optical corneal grafting after the infection had healed. Of these, 10 corneal grafts remained clear and two failed (over 9 months follow up). Both failures were related to hot grafts done for *Acanthamoeba* keratitis. In both cases the infection did not recur. According a comprehensive literature review by Sharma et al (Sharma et al., 2010), therapeutic corneal grafting can eradicate bacterial infection in 90 – 100% of cases with a clear graft after 1 year in 69 – 100%. Worse prognosis for therapeutic corneal grafts in *Acanthamoeba* keratitis was reported in the same review, as a cure rate of 45 – 81 % and a survival rate of 45% after one year.

In addition, Kashiwabuchi et al observed that 40% of eyes with hot grafts due to refractory *Acanthamoeba* keratitis developed glaucoma

with significantly shorter graft survival ($P < 0.01$) (Kashiwabuchi et al., 2008). One of our failed *Acanthamoeba* keratitis grafts also had high post op IOP requiring an Ahmed valve.

Six cases ended up with NPL because of total cupping of the optic nerve discs. All these cases showed refractory course of resolution with high IOP readings throughout the course of disease. The initial VA was significantly poor in most of these cases (3 with HM, 2 with LP). In only one case with *Acanthamoeba* keratitis, the initial VA was 0.3 LogMar. Of this group, 3 cases showed no growth, 1 with *P. aeruginosa*, 1 with *KleibSELLA oxytoca* and 1 with *Acanthamoeba* keratitis. All of these cases were treated medically except for the *Acanthamoeba* keratitis case which ended up with hot corneal graft because of non-healing ulcer. Interestingly, the predisposing factor in 4/6 patients was the pseudophakic bullous keratopathy. This strongly emphasises the importance of measuring and controlling the IOP during any infectious keratitis. In conclusion, this study found that ocular surface disease was the most common predisposing factor for sight threatening infectious keratitis. In this respect, herpes simplex keratitis was a significant association. Refractory course of treatment was mainly documented in patients with ocular surface disease (mainly HSK and bullous keratopathy), CL wear and previous eye surgery. All subjects with *Acanthamoeba* and *Pneumococcal* keratitis and almost all the Pseudomonal infections showed prolonged course of treatment. Visual loss due to raised IOP during infectious keratitis was a main concern. Paying special attention to the IOP values during the treatment of the

infectious corneal ulcers is essential. Therapeutic corneal grafting was an effective and safe treatment for patients with refractory infectious keratitis. Using of BHI in conjunction with the agar plates could improve the positive culture yields of the corneal scrapes. However as the clinical outcome of culture positive and culture negative cases was no different one could argue that a routine culture in all cases may not be essential if treatment with two broad spectrum antibiotics is employed at the outset.

CHAPTER EIGHT

8 Profile of Sight Threatening Infectious Keratitis in Nottinghamshire: A Retrospective Study

8.1 INTRODUCTION

We conducted a retrospective study of the sight threatening infectious keratitis in Queens Medical Centre, Nottinghamshire, England over a period of 4 years. The aim of our study was to document the incidence, demography, predisposing factors, clinical and microbiological diagnosis, treatment given, follow up duration, visual outcomes and complications in patients with severe infectious corneal ulceration. Another important purpose of our study was to compare the results of this study with another prospective study (over 3 years) which we had done in a trial to define the overall profile of the infectious keratitis in Nottinghamshire over a total period of 7 years.

8.2 METHODS

Between September 2003 and September 2007, all patients with severe infectious keratitis who were admitted in the Eye ward (C25) at Queens Medical Centre (QMC), Nottingham, UK were recruited in this study.

(After September 2007, we have conducted another prospective study which is described in details in another chapter).

The following data were obtained from the clinical notes of all subjects (when possible): personal details, the predisposing factors, visual acuity (VA), corneal scraping culture results, ocular signs, medical treatment including drugs, dose and duration, any surgical intervention, complications and final visual outcome. All visual acuities were transferred into LogMar recordings. Visual acuity of counting fingers (CF), hand movements (HM), light perception (LP) and no light perception (NLP) were recorded as LogMar values of 1.7 and 2, 4 and 5 respectively (Steinberg et al., 1994, Wong et al., 2003).

SPSS 16 software was used. Patients were divided into two groups, *Acanthamoeba* keratitis and bacterial keratitis. The seasonal variation was analysed using one way ANOVA test and Benferroni correction. Mann Whitney test was used to compare the healing period between the *Acanthamoeba* keratitis and BK groups, whereas Wilcoxon test was performed to report the change of the VA after treatment. Correlation between prolonged healing period in relation to age and VA at presentation was evaluated using bivariate correlation. Cox Regression test was used to examine the effect of the predisposing factors, sex and previous steroids use on the time taken to complete healing.

8.3 RESULTS

8.3.1 Demographics

A total of 95 eyes of 92 patients were included. There were 47 left (49.4%), 45 right (47.3%), and 3 bilateral (3.1%) cases. Females and males were almost equally distributed; 47 Female (51.1%) and 45 males (48.9%). The average age was 56 years (+/- 24.4) and ranged from 7 to 95 years

8.3.2 Seasonal variations

Overall, there were 24 cases in autumn, 13 in spring, 26 in summer and 28 cases during the winter time (Autumn: September, October and November, Winter: December, January and February, Spring: March, April and May and Summer: June, July and August). The estimated number of studied cases during the summer and autumn was significantly more than the number in spring (one way ANOVA test, $P < 0.01$). The seasonal variation of incidence is shown in table 20.

Table 20. Seasonal distribution of the severe infectious keratitis in Nottinghamshire, Autumn (September, October and November), Winter (December, January and February), Spring (March, April and May) and Summer (June, July and August).

2003				Autumn
				5
2004	Winter	Spring	Summer	Autumn
	6	3	5	7
2005	Winter	Spring	Summer	Autumn
	5	4	8	10
2006	Winter	Spring	Summer	Autumn
	6	4	7	9
2007	Winter	Spring	Summer	
	7	2	7	

8.3.3 Period of treatment

The mean period of hospital admission was 8 ± 11 days (range 4 to 35 days). The number of cases in which the total period of treatment was clearly documented were 92/95 (in 3 cases, the follow up period was not documented accurately and thus excluded from this calculation). The total period of treatment ranged from two weeks to 2 years, median = 45 days (mean = 67.1 ± 90.9). When analysed separately, the longer period of treatment was among *Acanthamoeba* keratitis patients, ranged from 4 months to 2 years, median = 165 days (mean = 287 ± 267), whereas the median period of management of BK was 45 days ranged from two weeks 13 weeks except one case where it was 6 months (in a refractory case of bacterial keratitis) (mean = 54 ± 51).

8.3.4 Microbiology

Corneal scrapings were done in 93 of the 95 eyes. 36 (39%) eyes showed positive growth and 57 (61%) eyes revealed no growth. Of the culture positive samples, 17 eyes (47.2%) yielded gram negative bacteria [16 cases of *P. aeruginosa* and 1 case of coliform bacteria], 11 (31%) showed gram positive bacterial infections [5 *S. aureus*, 4 *Staphylococcus epidermidis*, 1 *pneumococcus* and 1 *Streptococcus viridians*], 5 eyes (14%) had *Acanthamoeba* keratitis (one bilateral case), 2 (5.5%) demonstrated fungal infection and 1 (2.5%) with atypical mycobacteria. Table 21 shows the isolated organisms and related predisposing factors.

Table 21. The isolated organisms and the correlated predisposing factors

Isolated organism	Number of eyes (out of 36 culture positive eyes)	Predisposing factors
Amoeba		
<i>Acanthamoeba</i>	5 (13.8%)	5 CL wear
Gram-negative Bacteria		
<i>Pseudomonas aeruginosa</i>	16 (44.4%)	12 CL wear 1 Bullous keratopathy 1 Loose suture 2 Failed conreal grafts
<i>Coliform</i>	1 (2.7%)	1 CL wear
Gram-positive Bacetria		
<i>Staphylococcus aureus</i>	5 (13.8%)	1 CL wear 2 Suture related 2 Failed corneal graft 1 Immunosuppression 1 Decompensated cornea after 1 Fuch's endothelial dystrophy
<i>Staphylococcus epidermidis</i>	4 (11.1%)	1 CL wear 1 Previous HSK infection 1 Post vitrectomy 1 Bullous keratopathy
<i>pneumococcus</i>	1 (2.7%)	1 Immunosuppression
<i>Streptococcus viridans</i>	1 (2.7%)	1 Eczema and dry eyes
Fungi		
<i>Candida albicans</i>	1 (2.7%)	1 Exposure keratopathy
<i>Candida barabsilosis</i>	1 (2.7%)	1 Failed corneal graft with steroid use
Mycoplasma		
<i>Atypical mycobacteria</i>	1 (2.7%)	1 CL wear

There were 3 bilateral cases (one case with *Acanthamoeba* keratitis in CL wearer, one case with *P. aeruginosa* in decompensated cornea related to Fuch's endothelial dystrophy and one case showed no growth after LASIK surgery)

8.3.5 Predisposing factors

Ocular surface diseases (35.8%) and Contact lens wear (31.5%) were the main predisposing factors for the corneal infections; together they formed about two thirds of cases. All cases with *Acanthamoeba* keratitis and 12/16 of the *P. aeruginosa* cases were CL wearer. There was only one CL wearer among the *S. aureus* infections (out of the 5 isolated *S. aureus* keratitis). The detailed risk factors for infectious keratitis are elaborated in table 22.

Table 22. The factors which predispose to infectious keratitis

Predisposing factor	No. (%) out of the 95 eyes	Total. (%) out of the 95 eyes
Contact Lens Wear (2 bilateral cases)	29 soft CL wear 1 Rigid gas permeable CL	30 (31.5%)
Ocular Disease	11 Previous herpes simplex keratitis (HSK) 8 Dry eyes 7 Bullous keratopathy 3 Neovascular glaucoma 2 Non healing epithelial defects 1 Fuch's endothelial dystrophy 1 ocular cicatricial pemphegoid (OCP) 1 Steven Johnson syndrome	34 (35.8%)
Previous Ocular surgery	5 Failed grafts 5 Suture related 1 Intravitreal Avastin injections 1 Vitrectomy 1 previous LASIK	13 (13.7%)
Eyelids abnormalities	4 Exposure keratopathy 2 Ectropion 1 Entropion	7 (7.4%)
Corneal trauma	1 Electrical burn 2 Corneal abrasion	3 (3.1%)
Systemic diseases	2 Diabetes 1 Rheumatoid arthritis 1 Thyroid dysfunction	4 (4.2%)
Infection of the lacrimal sac	1 Chronic dacryocystitis	1 (1%)
No predisposing factors	3 cases	3 (3.1)
Steroids use	Shared factor in ocular surface diseases	43 (45.2%)

8.3.6 Signs

Hypopyon was seen in 41/95 cases (12/16 *P. aeruginosa* 2/5 *S. aureus*, 3/4 *S. epidermidis*). All *Acanthamoeba* keratitis cases showed no hypopyon. The location of the ulcer was not well documented in 17/95 cases and thus excluded. Out of the remaining 78 cases, 39 revealed central location (all the *Acanthamoeba* keratitis showed central location). The thickness of the infiltrate was not documented in 31/95 cases, the infiltrate showed deep position (more than 50%) in 29/64 (in 4/5 cases with *Acanthamoeba* keratitis and 3/5 of *S. aureus* and 12/16 cases with *P. aeruginosa*). Additionally, out of the 60/95 documented cases, the ulcer was more than 6 mm in 9 cases (all cases with *Acanthamoeba* keratitis and 8/16 of *P. aeruginosa* cases were in this category), between 3 and 6 in 37 cases and less than 3 mm in 14 cases.

8.3.7 VA during and after

Out of the 92 cases with documented follow up period, 15 cases were excluded because of the non-documented VA either before or after the infections. In the remainder 77 cases, the median VA during the acute infections was 1 (the mean was 1.4 ± 1.3). After the complete healing, the median VA became 0.48 and the average improved to 1.2 ± 1.5 . The improvement in VA after the treatment was statistically significant ($P < 0.01$). When calculating the change in VA in the *Acanthamoeba*

keratitis and bacterial keratitis groups separately, there was no significant difference between the VA during and after the *Acanthamoeba* keratitis infection ($P>0.05$), whereas the improvement in VA in the BK group was statistically significant ($P<0.005$)

8.3.8 Complications

Out of the 92/95 cases with documented follow up period, 38/92 showed prolonged course of healing which was more than the median period of healing (median= 45 days). Eighteen cases showed no growth, 9/16 *P. aeruginosa*, 5/5 *Acanthamoeba* keratitis, 2/5 SA, 1/1 *Streptococcus viridians*, 1/1 *Pneumococcus*, 1/2 *Candida* and 1/1 case with atypical *Mycobacteria*. Melting and thinning was seen in 35 patients (6/16 of them were caused by *P. aeruginosa*). Non healing infection was documented in 3 cases which needed evisceration (2 with no growth and 1 *Pneumococcus*). Ocular complications due to infectious keratitis are given in table 23.

Table 23. Complication of microbial keratitis (AK: *Acanthamoeba keratitis*, PA: *Pseudomonas aeruginosa*, SA: *Staphylococcus aureus*, S epidermidis: *Staphylococcus epidermidis* and HSK: *herpes simplex keratitis*)

Complications	N out of 92 (%)	Highlights
Refractory course of treatment (more than the median= 45 days)	38	
High IOP	5	3 no growth, 1 AK and 1 PA
Melting and thinning	23	12 no growth, 6 PA, 1 AK, 1 SA and 1 S edpidermidis , 1 Pneumococcus and 1 atypical Mycobacteria
Perforation	14	8 no growth, 3 PA, 1 AK, 1 SA and 1 S edpidrmidis
Deep corneal neovascularization	8	6 had previous gluing and 2 cases with previous HSK
Bullous Keratopathy	1	1 AK
Cataract	2	1 AK and 1 no growth
Recurrent infection	3	2 SA and 1 no growth
Non-healing infection leading to Evisceration	3	2 no growth and 1 Pneumococcus

8.3.9 Correlation between Healing period and age and correlation between healing period and initial VA in bacterial and *Acanthamoeba* keratitis patients

Out of the 36 eyes with positive culture results, bacterial keratitis (31 cases) and *Acanthamoeba* keratitis (5 cases) were analysed as different groups. Relevant data was available for all the culture positive cases.

In both groups (bacterial and *Acanthamoeba* keratitis) there was no correlation between the initial VA and the prolonged period of treatment ($P>0.05$) However, in the bacterial keratitis group there was

correlation between the old age and the prolonged period of healing ($R=0.4$, $P<0.001$, Spearman) which was not demonstrated in the *Acanthamoeba* keratitis group. The correlation between the prolonged period of healing and the delay in presentation could not be calculated because the required information was not documented properly.

8.3.10 Period of healing

The effect of multiple variants (predisposing factors, sex and steroid use) on the healing period was studied using the Cox regression test in the *Acanthamoeba* keratitis and bacterial keratitis groups. In the former group, none of the previous factors seemed to affect the course of healing, whereas the previous use of steroids was the only statistically important factor affecting the period of treatment in the bacterial keratitis group ($P<0.001$)

8.3.10.1 Healing period in the *Acanthamoeba* and bacterial keratitis groups

When compared with the bacterial keratitis patients, *Acanthamoeba* keratitis was a risk factor for refractory and prolonged period of therapy in our study ($P<0.001$)

8.3.11 Treatment

8.3.11.1 Medical Treatment

In 3 cases, the treatment was not documented in the notes and excluded from this analysis. All the other 92 patients received

antibiotics as the first line treatment either individually or as a combination with other eye drops. The most common used antibiotics were topical fortified cefuroxime (5-10%) & gentamicin (5%) (n=71, 77.1%), topical ciprofloxacin as a monotherapy or as a combination with other topical eyedrops (n=26, 28.3%), chloramphenicol as a monotherapy or as a combination with other topical eyedrops (11, 12%) and fortified vancomycin (25mg/ml) & amikacin (25mg/ml) (n=2, 2.2%). A combination of topical anti *Acanthamoeba* agents: polyhexamethylene biguanide (PHMB 0.02%) or chlorhexidine 0.02% & Brolene 0.1% with topical antibiotics were used for *Acanthamoeba* keratitis (n=5, 2.1%). Antifungal agents such as topical amphotericin and systemic fluconazole were used in 3 cases (2 *Candida* infections and one atypical Mycobacterial keratitis). Acyclovir was used in 13 cases (all 11 cases with previous HSK and 2 cases with refractory course of healing which showed no growth). Topical corticosteroids were used in 22 cases of bacterial keratitis after the initial signs of response to treatment were documented. In addition, topical lubrication was used in 47 cases and dilating agents were used in 90 cases.

8.3.11.2 Surgical procedures

A number of surgical procedures were required in our patients. These were related to the lids, puncta, lacrimal sac and cornea.

Corneal grafting was carried out in 10 cases (3 cold corneal grafts and 7 therapeutic hot grafts). Most of the grafts remained clear except for one therapeutic graft for *Acanthamoeba* keratitis which failed shortly

after the penetrating keratopathy and needed cold grafting. In all cases, corneal grafting succeeded in eliminating the infectious keratitis with no recurrence of the original infection on the corneal grafts. Details for surgical procedures and their indications are given in table 24.

Table 24. Therapeutic interventions in refractory microbial keratitis (NG: No growth, AK: Acanthamoeba keratitis, PA: Pseudomonas aeruginosa, SA: Staphylococcus aureus, S epidermidis: Staphylococcus epidermidis, AMT: Amniotic membrane transplantation, DCR: Dacryostorhinostomy)

Procedure	Indication	N (%) out of the 95 cases	Highlights
Corneal gluing	Corneal perforation	12 (12.6%)	8 NG, 1 AK, 1 PA, 1 SA and 1 S epidermidis
Conjunctival hooding	perforated infectious ulcer	2 (2.1%)	1 NG and 1 PA
Fine Needle Diathermy of corneal vessels	To treat lipid keratopathy or intra or preoperative for PK	1 (1.1%)	1 NG
Cataract extraction	To improve the vision	2 (2.1%)	1 NG and 1 AK
Hot grafts	Therapeutic grafts	7 (7.4%)	3 NG, 1 PA, 1 AK, 1 SA and 1 S epidermidis
Cold grafts	To improve the vision	3 (3.1%)	1 PA, 1 AK and 1 NG
Replacement of corneal suture	To re-suture graft host dehiscence	1 (1.1%)	PA
AMT	Non healing epithelial defects	2 (2.1%)	2 NG
Inferior punctual plugs	Severe dry eyes and non healing epithelial defects	1 (1.1%)	NG
Tarsorrhaphy	Non healing epithelial defects	5 (5.2%)	5 NG
Botox Injections	Non healing epithelial defects	5 (5.2%)	5 NG (2 cases needed tarsorrhaphy later)
Intravitreal injection of antibiotics	Endophthalmitis	2 (2.1%)	2 NG
DCR	Recurrent corneal infection and dacryocystitis	1 (1.1%)	NG
Eyelid correction	2 Entropion 2 Ectropion	2 (2.1%)	2 NG

8.4 DISCUSSION

The main purpose of this retrospective study was to ascertain whether there were any emerging or evolving trends in microbial keratitis over the period of the prospective and retrospective studies. This could give an idea about the overall profile of the infectious keratitis in Nottinghamshire and East-midlands area over a period of 7 years. In fact, the findings of the two studies were almost identical which probably confirmed the reliability of these studies and also indicated that the profile of infection had not changed over the study period. The findings of the prospective study have already been discussed in a **chapter 7**.

In the following discussion, a comparison of the data obtained from this retrospective study with those resulted in the prospective study will be illustrated.

This retrospective study recruited 92 in-patients (95 eyes) with severe corneal infections over a period of four years in Nottinghamshire area. There was significantly higher number of patients during the summer time. The same trend was also reported in the prospective study. Another UK based study has also reported the peak incidence of infectious keratitis during the summer time (Ibrahim et al., 2009).

The average period of warning symptoms before presentation was not documented properly in most cases and thus this calculation was excluded from this study.

The mean period of hospital admission was 8 ± 11 days (range 4 to 35 days). This almost corresponds to the mean period of admission in our prospective study (mean of 9 ± 13 , range 2 to 45). It also correlates to a similar retrospective study carried out in France where the mean stay was 9 days (ranging from 3 to 60 days). (Bourcier et al., 2003) However, Saeed et al have reported a lower average of 6.3 ± 4.2 days of in-patient stay in a retrospective study in Ireland (Saeed et al., 2009). Furthermore, in another study in New Zealand the mean in-patient stay was 5.8 days (Wong et al., 2003).

The course of treatment extended over a median of 45 days in this study. This was identical to the median period of our prospective study. However, when *Acanthamoeba* keratitis cases were excluded the median remained 45 days whereas it was 33 days in the prospective study. This may be due to the difference in the patients recruited in the two studies. In the retrospective study patients admitted with severe keratitis were included, whereas in the prospective study out-patients with severe keratitis and in-patients were included. If the decision to admit for treatment is an indicator of severity then it is possible that in the latter group the response was overall quicker due to the inclusion of the out-patients. The median period of treatment in *Acanthamoeba* keratitis cases in the retrospective study was 165 days, whereas it was 154 days in the prospective study. The treatment period was longer than another UK based study in Portsmouth (average 11.5 days, range 7-42 days) (Ibrahim et al., 2009). This was mainly because of the bias

towards recruiting severe cases of infectious keratitis in QMC in our study.

Interestingly, only 39% of eyes showed positive growth from the corneal scrapings, whereas 61% of eyes revealed no growth. This was even less than the positive rate of our prospective study where 41% showed positive cultures and 58.26% returned with no growth. Worldwide, the microbiological culture from corneal scrapes reveals positive results in only 52% to 65% of cases. (Garg, 2010) The positive culture yields in the UK are variously reported as 19%, 39%, 60% and 63.8% in different studies (Dart et al., 1991, Saeed et al., 2009, Dart, 1988, Ibrahim et al., 2009). In the studies with 60 and 63.8% positive rate, a brain heart infusion liquid culture medium (BHI) has been used in conjunction with the agar plates for microbial isolation. Using agar plates (without BHI) for culturing of the corneal scrapes at the QMC could be a possible explanation of our low isolation rate. Schaefer et al have previously reported that 90% of the positive cultures were in BHI medium, whereas only 53% were positive in agar plates (Schaefer et al., 2001). However, a German study has recently reported a positive culture rate of only 43%(148/346) even though they used both BHI and agar plates for bacterial recovery (Prokosch et al., 2011).

The most common isolated organisms in our study was *P. aeruginosa* (16/36, 44%). Equally, *Acanthamoeba* and *S. aureus* were the next most common isolated organisms, (5/36, 14% each). All together, they formed about 3/4 of all culture positive cases. In the prospective study,

however, similar positive rate between the *S. aureus* (19%), *P. aeruginosa* (15%) and *Acanthamoeba* species (17%) was documented. These three organisms together were responsible of about half of the culture positive cases. According to the literature, *P. aeruginosa* and *S. aureus* have been shown to be the most common isolated organisms in many studies (Saeed et al., 2009, Dart, 1988). Though still uncommon, *Acanthamoeba* keratitis is an increasingly identified infection at our centre, probably because of the tertiary nature of our patient base and because of the growing tendency of the CL wear (Das et al., 2007).

Similar to the findings of the prospective study, ocular surface disease was the most common predisposing factor (35.8%) as has also been reported by Pachigolla and Schaefer (Pachigolla et al., 2007, Schaefer et al., 2001). CL wear was the second most common predisposing factor (in 31.5% of cases). The type of contact lens was not well documented in most cases.

Interestingly, all the 5 cases with *Acanthamoeba* and 12/16 of the *P. aeruginosa* were CL wearers. CL wear was reported in only one case out of the 5 cases with *S. aureus* keratitis. The correlation between corneal infections due to *P. aeruginosa* & *Acanthamoeba* and the CL use has been well reported (Panjwani, 2010, Willcox, 2007). Furthermore, Schaefer et al have shown the weak correlation between the CL wear and *S. aureus* corneal infection (Schaefer et al., 2001).

Also, in accordance to the findings of our prospective study, topical corticosteroid use was a shared predisposing factor in 45.2% of cases.

The wide use of topical steroids in patients with severe infectious keratitis has previously been reported. (Wong et al., 2003)

Although there was a lack of documentation in many cases, the clinical signs of the corneal infections showed similarity to those found in the prospective study. In fact, the large infectious corneal ulcers (more than 6 mm) were reported in 4/5 of the *Acanthamoeba* keratitis cases, 3/5 of *S. aureus* and 12/16 of *P. aeruginosa* infections. As documented in the prospective study, most corneal infections with *P. aeruginosa* (12/16), *S. epidermidis* (3/4), *S. aureus* (2/5) showed hypopyon. All *Acanthamoeba* keratitis cases did not show a hypopyon. Of note, 38/92 showed refractory course of treatment which lasted for more than 45 days (the median period for management in our study). Of these, all the *Acanthamoeba* keratitis cases and 9/16 of the *P. aeruginosa* were in this category. The refractory and prolonged course of treatment in *Acanthamoeba* and *P. aeruginosa* keratitis has been well documented (Dart et al., 2009, Kashiwabuchi et al., 2008, Willcox, 2007). There was no significant improvement of the visual acuity in the *Acanthamoeba* keratitis group whereas the final visual acuity was significantly better in the bacterial keratitis group. This could be explained by the fact that many patients with *Acanthamoeba* keratitis had been diagnosed and treated at the late stage of deep stromal infiltration and had devastating consequence despite treatment. This, however, was not the case in the bacterial keratitis group where most patients were diagnosed and treated at early stage with antibiotics which were effective and prevented further visual loss in most cases.

Acanthamoeba keratitis as a disease, was a risk factor for refractory and prolonged period of therapy when compared with bacterial keratitis. As found in the prospective study, a correlation between the old age and the prolonged period of healing was only found in the bacterial keratitis group. Most of the predisposing factors seemed not to significantly affect the period of healing. However, previous chronic steroid use in association with ocular surface disease was a significantly important factor. The association of topical steroid usage and ocular surface disease in prolonging the duration of management and poor visual outcomes has previously been highlighted. (Wong et al., 2003, Bourcier et al., 2003)

Topical fortified cefuroxime & gentamicin (dual therapy) or ciprofloxacin as a monotherapy have been shown to have a positive impact on severe infectious keratitis. (Gokhale, 2008) These drugs were the major treatment modalities for all bacterial keratitis cases in our study. Anti *Acanthamoeba* agents (PHMB or chlorhexidine & brolene) and antibiotics were used in all *Acanthamoeba keratitis* cases. Corneal grafting was done for a total of 10 patients (7 therapeutic hot grafts and 3 optical cold corneal grafts). In the hot grafts category, there were 2 CL wearers with refractory *Acanthamoeba keratitis*, 2 with *S. aureus* infection (1 suture related in a corneal graft, and 1 HSK), one with *P. aeruginosa* keratitis (failed graft) and 2 with no growth (1 severe blepharitis and 1 HSK). Most of the grafts remained clear except for one therapeutic graft for *Acanthamoeba keratitis* which failed shortly after the penetrating keratopathy and needed another grafting. In all

cases, corneal grafting succeeded in eliminating the infectious keratitis with no recurrence of the original infection on the corneal grafts. Therapeutic corneal grafting can eradicate bacterial infection in 90 – 100% of cases with a clear graft after 1 year in 69 – 100%. (Sharma et al., 2010). These findings mirror the findings of the prospective study with regard to the need of corneal grafts.

The main limitation of this study was the lack of sufficient clinical documentation in some cases which is an inherent issue in retrospective studies.

In conclusion, this retrospective study showed consistent findings compared with the previous prospective study. It showed that ocular surface disease and CL wear were the most common predisposing factors for sight threatening infectious keratitis. Culture yields from clinically apparent infectious keratitis cases were poor. Use of brain heart infusion culture medium in conjunction with the agar plates could improve the positive culture rates from corneal scrapes. Refractory course of treatment was mainly documented in patients with ocular surface disease, CL wear and previous eye surgery. All subjects with *Acanthamoeba* and most *P. aeruginosa* keratitis required prolonged course of treatment. Therapeutic corneal grafting was an effective and safe treatment for patients with refractory infectious keratitis.

CHAPTER NINE

9 Summary, general discussion and Conclusion

The ocular surface is permanently in contact with environmental pathogens. Commensal microbes, which inhabit the mucosal surface of the OS, have also the potential to cause opportunistic infections. This can lead to severe infectious keratitis which can cause permanent loss of vision. To combat against these harmful challenges, the innate immunity on the OS plays a vital role. AMPs are an important component of this innate response. They are natural effectors of the defence system with broad spectrum antimicrobial activity and cell signalling functions.

9.1 OVERVIEW:

In this thesis, the molecular and clinical aspects of infectious keratitis were studied. The *in vitro* gene expression of the ocular AMPs was described while stimulating OS cells with different microbes. Also, the AMPs gene profile was tested in healthy people and compared with the profile in patients with active infectious keratitis and after healing. Furthermore, the commercially available HBD3 protein was studied for its antibacterial activity. In contradiction to the published literature, no

evidence of such activity was concluded. Clinically, this study demonstrated for the first time the role of corneal densitometry, as measured by Rotating Scheimpflug Camera (Oculus Pentacam) in the follow up of patients with infectious keratitis. Comprehensive prospective and retrospective studies of the profile of sight threatening corneal infections in Nottinghamshire over a period of 7 years were also carried out.

9.2 BRIEF DESCRIPTION

In chapter two, the gene level of the ocular AMPs in OS cells stimulated with *Acanthamoeba castellanii*, a known ocular pathogen, was comprehensively studied. This was the first study to examine the profile of AMPs in relation to protozoal infections. The hBD3 gene expression was noted to be the most significantly up-regulated molecule amongst the studied AMPs. This suggested that AMPs, notably hBD3, may play a possible role in combating *Acanthamoebic* infection at the ocular surface. This was followed by a study on the examination of the mRNA levels of the AMPs during in vitro challenge of OS cells with Gram-negative and Gram-positive bacteria (in chapter three). In both groups, LL37 was found to be significantly up-regulated compared to other AMPs. This too was the first comprehensive study to show the gene profile of ocular AMPs in response to the stimulation with two different pathogens (*P. aeruginosa* and *S. aureus*). Together with the results obtained in chapter two led to the conclusion that modulation of ocular AMP gene expression was pathogen-dependent. However, one of the

drawbacks of this study was using two different types of the OS cells. HCEC were used in the bacterial stimulation study and HCLE for *Acanthamoeba* challenge. This was mainly due to a technical reason in that the *Acanthamoeba* stimulation was carried out in the laboratory of one of our collaborators (prof. Panjawani) in the USA. The treated samples were sent to our laboratory for gene analysis. The AMPs gene profile of the HCEC stimulated with bacteria was conducted entirely in our department where we have standardised our experiments with the HCLE cells.

In chapter four, the ex vivo gene profile of the ocular AMPs in patients with infectious keratitis was studied. Because the lack of the RNA yields of IC samples, an optimized method of RNA extraction was adopted and the gene profile of only hBD3 and hBD9 was studied (based on the results of our group's previous work and on the results of the in vitro studies in this thesis). IC samples were taken from healthy subjects and in patients with keratitis both during active infection and after healing of infectious keratitis (*Acanthamoeba* and bacterial keratitis). A total of 60 IC samples were taken; 24 were from healthy controls. During acute *Acanthamoeba* keratitis, and in accordance with the in vitro results, hBD3 levels were markedly increased, whereas hBD9 was significantly down-regulated. The overall pattern of gene change was similar in bacterial keratitis but with less significance. This study confirmed that not all AMPs behave similarly, some are up-regulated and some down-regulated, suggesting diverse role of AMP in infection and inflammation. This study also referred to a possible specific role of

AMP-mediated host defence in *Acanthamoeba* keratitis because of the significant increase of the hBD3

AMPs including hBD3 have been reported to have antibacterial activity. As we discovered markedly increased gene up-regulation for hBD3 during *Acanthamoeba* infection we inferred that this protein may have anti *Acanthamoeba* activity as well. To test this hypothesis it was imperative to establish and optimise the antibacterial activity of the commercially acquired samples of hBD3 such that they could be then run in parallel with experiments to evaluate anti amoebicidal activity if any. Thus and to confirm the published data on antimicrobial activity of hBD3 against *E.coli* and *S. aureus*, a study to ascertain this activity in chapter five was undertaken. The antimicrobial activity of two types of commercially available recombinant hBD3 was tested using the conventional colony counting method. Distilled water or acidic solvents used for hBD3 preparation were used as negative controls. Interestingly, the reported antibacterial activity of hBD3 could not be confirmed. In fact, the achieved bactericidal activity was attributed to the acidic solvent rather than the hBD3 protein itself. This was not consistent with other reports which confirmed the potent antibacterial activity of this protein. However, by further investigating the methodology of these studies, it was found that most of these studies did not use a proper negative control which might have affected their results. Subsequently, the anti-*Acanthamoeba* assay of hBD3 protein could not be investigated.

In another chapter (chapter six), the possible role of the corneal densitometry measured by the Pentacam machine in monitoring patients with infectious keratitis was studied. In this study the normal densitometry values of the human cornea was also established. Sixty four eyes of 40 healthy controls and 36 eyes of 35 patients with bacterial keratitis were studied. A Pentacam system was used to study corneal density. Corneal densitometries in subjects with bacterial keratitis were recorded during the active stage and 4-6 weeks after complete healing. Densitometry was recorded at the site of infection and at a point in clear cornea furthest away from the infectious infiltrate. Corneal thickness was also measured. The mean densitometry value of normal corneas was 12.3 ± 2.4 . In infectious keratitis the densitometry values were greatest at the site of the active infection and significantly more than in controls. The densitometry values at a point of clear cornea furthest away from the site of infection were also significantly higher than in controls during active disease but failed to return to normal values despite complete resolution of infection. The density of the infiltrates was much higher than that of residual scars following healing of ulcers. No correlation was found between the pachymetry and the densitometry values. Densitometry of active infectious corneal infiltrates was found to be more than that resulting from the corneal scarring after healing. Persistent increase in density of clear cornea furthest away from the focus of corneal infection suggested that the host response extends beyond the immediate area of infection and indeed may occur through the entire cornea. These

changes persisted beyond 4 weeks, which was the duration of follow up of this study. It was concluded that densitometry can be used as an objective measure of the corneal response to infection and to monitor response to therapy.

In chapter seven, cases with serious infective keratitis presenting to Queens Medical Centre in Nottingham over a 3 year period were prospectively studied. Detailed information on the aetiology, culture results, signs & symptoms, the treatment given and the patient's response was collected and statistically analysed. In total, 143 eyes of 129 patients were enrolled. The important risk factors were ocular surface disease (32%), CL wear (26%) and previous ocular surgery (20%). Old age, deep infiltration, steroid use and poor initial vision were risk factors for prolonged course of treatment in bacterial keratitis. Corneal scrapings were done in 89% of the cases but positive results were obtained only in 41.7%. *S. aureus* was the most common isolated bacteria (18.8%). *Acanthamoeba* and *P.aeruginosa* were the second and third common causative organisms (16.6% and 15%, respectively). Overall, 8.3% needed corneal grafting which survived in 83.3% and eradicated infection in 100%.

Finally, in chapter eight, the profile of sight threatening infectious keratitis in Nottingham over a 4 year period was studied retrospectively. The results obtained were very similar to the prospective study. A total of 95 eyes of 92 patients were examined. Corneal scrapings were done in 93 of the 95 eyes (98%). In total, 36

eyes (39%) showed positive growth and 57 eyes (61%) revealed no growth. Of the culture positive samples, 16 eyes (44.4%) yielded *P. aeruginosa*. Ocular surface diseases (35.8%) and CL wear (31.5%) were the main predisposing factors for the corneal infections; together they formed about two thirds of cases. Corneal grafting was carried out in 10.5% of cases. Most of the grafts remained clear except for one therapeutic graft for *Acanthamoeba* keratitis. In all cases, corneal grafting succeeded in eliminating the infectious keratitis with no recurrence of the original infection in the corneal grafts. The main limitation of this study was its retrospective nature which could not provide proper documentation of clinical details in some cases.

Based on chapters seven and eight, we made certain recommendation for increasing the culture positive yield of microbial culture results depending on culturing the samples on BHIB media in addition to the agar plates.

9.3 GENERAL DISCUSSION AND CONCLUSION

In this thesis, the main focus was on the infectious keratitis as a disease which could cause blindness if not diagnosed and treated properly. An attempt to cover some important clinical and molecular aspects of the corneal infections has been achieved. The main aim was to improve the understanding of the infectious keratitis which can lead to better approach, diagnosis and management in the future.

The clinical findings of this study described the specific aspects of the microbial keratitis in Nottinghamshire. It involved 2 separate studies about the profile of sight threatening in Nottinghamshire: retrospective and prospective. Interestingly, both studies almost showed identical findings. In fact, they showed that ocular surface disease and CL wear were the main predisposing factors of corneal infections in Nottinghamshire. Also, consistent with other European studies, *Pseudomonas aeruginosa* and *Staphylococcus aureus* were the main causative organisms. Importantly, *Acanthamoeba* keratitis showed growing tendency especially among CL wearers. Furthermore, these studies concluded that using BHIP in addition to the agar plates may be necessary to improve the positive isolation rate of the corneal scrapes. The current practice in QMC depends only on using agar plates for growing microbes from corneal samples. A recommendation about adding BHIB to agar plates has been passed to Microbiology Department in QMC to improve the isolation rate of the corneal samples in the future.

Depending on the results of the clinical studies and based on previous work in the Ophthalmology Department in QMC, the *in vitro* and *in vivo* gene expression of the AMPs in ocular surface cells infected with *Gram negative* and *Gram positive* bacteria and *Pseudomonas* was studied. Interestingly, in the *in vitro* study, while stimulating the OS cells with the *Acanthamoeba* the hBD3 gene expression was the most significantly up-regulated molecule amongst the studied AMPs. Moreover, while challenging the OS cells with *Pseudomonas aeruginosa*

and *Staphylococcus aureus*, LL37 was found to be more significantly up-regulated compared to other AMPs. This *in vitro* study was the first comprehensive study to show the gene profile of ocular AMPs in response to the stimulation with different pathogens (Gram negative and Gram positive and *Acanthamoeba*). This suggested that AMPs hBD3 and LL37 may play a possible role in combating ocular surface infections. Also, it concluded that modulation of ocular AMP gene expression was pathogen-dependent.

The next step in this thesis was to further investigate the results of our *in vitro* study and confirm its novel findings. The *ex vivo* gene profile of all the ocular AMPs in patients with infectious keratitis was intended to be studied. Because the lack of the RNA yields of IC samples, and also the difficulty in taking multiple samples from patients with painful and infected eyes, it was not possible to study the gene profile of all the ocular AMPs. Indeed, over a period of about 14 months, 123 IC samples showed poor yields of RNA. Thereafter an optimized method to get reasonable yield of RNA sufficient for RT-PCR processing of each sample was developed. Despite the improved and optimized method of RNA extraction, the yield of RNA in the majority of IC samples was only sufficient to study the mRNA level of 2 AMPs. The main focus of this study was on the *Acanthamoeba* keratitis because of its growing tendency and because the AMPs profile has never been tested in such infection before. Thus, hBD3 and hBD9 were chosen for this study. Indeed, hBD3 showed very significant expression in OS cells challenged with *Acanthamoeba* SP in the *in vitro* study, whereas hBD9 was

previously shown to be down-regulated in different types of corneal infections according to our group's previous work

The gene expression of the hBD3 and hBD9 was studied in samples taken from patients with infectious keratitis resulted from Gram negative and Gram positive bacteria in addition to *Acanthamoeba*. These samples were taken using the impression cytology technique during the acute infection and after complete healing and the gene expression of the studied AMPs was compared with the level in healthy subjects. As mentioned previously, the main goal of this study was to focus on the studied AMPs profile in *Acanthamoeba* keratitis and compare it with that in Gram negative and positive bacterial keratitis and in healthy subjects. During acute *Acanthamoeba* keratitis, and in accordance with the *in vitro* results, hBD3 levels were markedly increased, whereas hBD9 was significantly down-regulated. The overall pattern of gene change was similar in bacterial keratitis but with less significance. The changes in the AMPs expression persisted even 4-6 weeks after total healing of the infectious keratitis. This study confirmed that not all AMPs behave similarly, some are up-regulated and some down-regulated, suggesting diverse role of AMP in infection and inflammation. This study also referred to a possible specific role of AMP-mediated host defense in *Acanthamoebal* keratitis because of the significant increase of the hBD3. Also, it suggested possible role of the AMPs in future diagnosis as they can be used as markers for diagnosis along with the results of the corneal scraping.

One limitation of this study was that the gene expression of the AMPs was studied without testing the levels of the proteins encoded. This was because the cell yield from IC was barely sufficient to allow examination of two AMPs. Studying the protein expression depends on obtaining a reasonable amount of cells. It was extremely difficult to repeat the IC sampling for multiple times in patients with corneal infections because of the soreness and lacrimation. Furthermore, the protein hBD9 and its antibody were not available at the time of our study, so it was not possible to perform immunostaining study of the IC samples.

After confirming the significant and consistent increase of the hBD3 in OS cells during the *Acanthamoeba* infection in the *in vitro* and the *ex vivo* studies, the anti-amoebic of the HBD3 protein was further investigated. To test this hypothesis it was imperative to establish and optimise the antibacterial activity of the commercially acquired samples of hBD3 such that they could be then run in parallel with experiments to evaluate anti amoebicidal activity if any. Thus and to confirm the published data on antimicrobial activity of hBD3 against *E. coli* and *S. aureus*, a study to ascertain this activity in was undertaken. The antimicrobial activity of two types of commercially available recombinant hBD3 was tested. Distilled water or acidic solvents used for hBD3 preparation were used as negative controls. Interestingly, the reported antibacterial activity of hBD3 could not be confirmed. Indeed, all the achieved bactericidal activity was attributed to the acidic solvent rather than the hBD3 protein itself. This contradicted with other reports which confirmed the potent antibacterial activity of this protein.

However, by further investigating the methodology of these studies, it was found that most of these studies did not use a proper negative control. The conclusion of this study was: Technical errors and non-adherence to basic principles, such as use of proper controls, might affect the reliability of the experimental studies. On account of this unexpected result, the anti-*Acanthamoeba* assay of hBD3 protein could not be pursued.

The final study in this thesis involved investigating the possible role of the corneal densitometry measured by the Pentacam machine in monitoring patients with infectious keratitis. In this novel study, the corneal densitometry in patients with bacterial keratitis was measured during the active stage and 4-6 weeks after complete healing. The densitometry values at the point of the active infection and at a point of clear cornea furthest away from the site of infection were significantly higher than those in healthy corneas. These readings failed to return to normal values after complete resolution of infection. The corneal density of the infiltrates was much higher than that of residual scars following healing of ulcers. Persistent increase in density of clear cornea furthest away from the focus of corneal infection suggested that the host response extends beyond the immediate area of infection and indeed may occur through the entire cornea. These changes persisted beyond 4 weeks, which was the duration of follow up of this study. This may correlate with the findings of our *ex vivo* study which showed persistent changes in the AMPs expression even 4-6 weeks after complete healing. That could possibly lead to the conclusion that sub-

clinical changes may persist after the total clinical resolution of the infectious keratitis. Further studies with longer follow up period may be warranted to confirm this hypothesis.

In this thesis, one step forward towards better understanding of the infectious keratitis was achieved. Indeed, the novel findings of the clinical studies included: recognizing the most common predisposing factors of the corneal infections in Nottinghamshire area, the most common causative organisms (including the surprisingly growing tendency of the *Acanthamoeba*) in addition the importance of using the BHIB in addition to the agar plates to improve the isolation rate of the corneal scraping. Furthermore, the novel use of the Pentacam machine in the follow up of the patients with infectious keratitis was investigated.

On the other hand, the molecular studies described the comprehensive *in vitro* and *ex vivo* gene profile of the AMPs in OS cells infected with Gram positive, Gram negative bacteria and *Acanthamoeba*. In fact, this thesis suggested that there may be potential of using the AMPs either in the diagnosis or in the treatment of the microbial keratitis in the future. Finally, the previously reported antimicrobial activity of the HBD3 protein could not be demonstrated in this study and that was attributed to the lack of using proper controls in previous studies mentioned in the literature.

The suggested future work could include the following:

- 1- Further study to investigate the *ex vivo* profile of all the AMPs on the OS in patients with infectious keratitis with longer follow up period.
- 2- Further study to demonstrate the protein expression of the AMPs in patients with infectious keratitis compared with healthy people.
- 4- The potential antimicrobial use of the AMPs proteins will need to be investigated
- 5- The potential use of the AMPs gene expression (as markers) in the diagnosis of the infectious keratitis will need to be investigated
- 3- Further study to confirm the corneal densitometry changes in patients with infectious keratitis with longer follow up period. This is mainly to define the period when the corneal densitometry values returned to normal levels after the resolution of the infection; this could be correlated with the molecular changes in the AMPs gene levels in those patients.

BIBLIOGRAPHY

- ABEDIN, A., MOHAMMED, I., HOPKINSON, A., *et al.* (2008) A novel antimicrobial peptide on the ocular surface shows decreased expression in inflammation and infection. *Invest Ophthalmol Vis Sci*, 49, 28-33.
- AGERBERTH, B., CHARO, J., WERR, J., *et al.* (2000) The human antimicrobial and chemotactic peptides LL-37 and alpha-defensins are expressed by specific lymphocyte and monocyte populations. *Blood*, 96, 3086-93.
- AGERBERTH, B., GUNNE, H., ODEBERG, J., *et al.* (1995) FALL-39, a putative human peptide antibiotic, is cysteine-free and expressed in bone marrow and testis. *Proc Natl Acad Sci U S A*, 92, 195-9.
- ALEXANDRAKIS, G., HAIMOVICI, R., MILLER, D., *et al.* (2000) Corneal biopsy in the management of progressive microbial keratitis. *Am J Ophthalmol*, 129, 571-6.
- ALOMAR, T., MATTHEW, M., DONALD, F., *et al.* (2009) In vivo confocal microscopy in the diagnosis and management of acanthamoeba keratitis showing new cystic forms. *Clin Experiment Ophthalmol*, 37, 737-9.
- ANDERSON, J. A., BINDER, P. S., ROCK, M. E., *et al.* (1996) Human excimer laser keratectomy. Immunohistochemical analysis of healing. *Arch Ophthalmol*, 114, 54-60.
- BRON, A., Tripathi, R., & TRIPATHI, B. (1997) The cornea and sclera. *Wolff's Anatomy of the Eye and Orbit*. Eighth edition ed. Essex, Chapman and Hall.
- ARAKI-SASAKI, K., OHASHI, Y., SASABE, T., *et al.* (1995) An SV40-immortalized human corneal epithelial cell line and its characterization. *Invest Ophthalmol Vis Sci*, 36, 614-21.
- AZUARA-BLANCO, A., SADIQ, A. S., HUSSAIN, M., *et al.* (1997) Successful medical treatment of Acanthamoeba keratitis. *Int Ophthalmol*, 21, 223-7.
- BACON, A. S., FRAZER, D. G., DART, J. K., *et al.* (1993) A review of 72 consecutive cases of Acanthamoeba keratitis, 1984-1992. *Eye*, 7 (Pt 6), 719-25.
- BAREQUET, I. S., HABOT-WILNER, Z., KELLER, N., *et al.* (2008) Effect of amniotic membrane transplantation on the healing of bacterial keratitis. *Invest Ophthalmol Vis Sci*, 49, 163-7.

- BATONI, G., MAISETTA, G., ESIN, S., *et al.* (2006) Human beta-defensin-3: a promising antimicrobial peptide. *Mini Rev Med Chem*, 6, 1063-73.
- BEFUS, A. D., MOWAT, C., GILCHRIST, M., *et al.* (1999) Neutrophil defensins induce histamine secretion from mast cells: mechanisms of action. *J Immunol*, 163, 947-53.
- BENSON, W. H. & LANIER, J. D. (1992) Comparison of techniques for culturing corneal ulcers. *Ophthalmology*, 99, 800-4.
- BHARATHI, M. J., RAMAKRISHNAN, R., MEENAKSHI, R., *et al.* (2007) Ulcerative keratitis associated with contact lens wear. *Indian J Ophthalmol*, 55, 64-7.
- BIOSYSTEMS, A. (2009) Real-Time PCR Vs. Traditional PCR.
- BOURCIER, T., PATTEAU, F., BORDERIE, V., *et al.* (2004) [Amniotic membrane transplantation for the treatment severe acanthamoeba keratitis]. *Can J Ophthalmol*, 39, 621-31.
- BOURCIER, T., THOMAS, F., BORDERIE, V., *et al.* (2003) Bacterial keratitis: predisposing factors, clinical and microbiological review of 300 cases. *Br J Ophthalmol*, 87, 834-8.
- BOWDISH, D. M., DAVIDSON, D. J. & HANCOCK, R. E. (2005) A re-evaluation of the role of host defence peptides in mammalian immunity. *Curr Protein Pept Sci*, 6, 35-51.
- BRANDT, C. R., AKKARAWONGSA, R., ALTMANN, S., *et al.* (2007) Evaluation of a theta-defensin in a Murine model of herpes simplex virus type 1 keratitis. *Invest Ophthalmol Vis Sci*, 48, 5118-24.
- BROWN, K. L. & HANCOCK, R. E. (2006) Cationic host defense (antimicrobial) peptides. *Curr Opin Immunol*, 18, 24-30.
- BUCK, C. B., DAY, P. M., THOMPSON, C. D., *et al.* (2006) Human alpha-defensins block papillomavirus infection. *Proc Natl Acad Sci U S A*, 103, 1516-21.
- BUEHL, W., STOJANAC, D., SACU, S., *et al.* (2006) Comparison of three methods of measuring corneal thickness and anterior chamber depth. *Am J Ophthalmol*, 141, 7-12.
- BURG, N. D. & PILLINGER, M. H. (2001) The neutrophil: function and regulation in innate and humoral immunity. *Clin Immunol*, 99, 7-17.
- BUSTIN, S. A. (2000) Absolute quantification of mRNA using real-time reverse transcription polymerase chain reaction assays. *J Mol Endocrinol*, 25, 169-93.
- CAO, Z., JEFFERSON, D. M. & PANJWANI, N. (1998) Role of carbohydrate-mediated adherence in cytopathogenic mechanisms of Acanthamoeba. *J Biol Chem*, 273, 15838-45.

- CASSONE, M. & OTVOS, L., JR. (2010) Synergy among antibacterial peptides and between peptides and small-molecule antibiotics. *Expert Rev Anti Infect Ther*, 8, 703-16.
- CHEN, H. C., TAN, H. Y., HSIAO, C. H., *et al.* (2006) Amniotic membrane transplantation for persistent corneal ulcers and perforations in acute fungal keratitis. *Cornea*, 25, 564-72.
- CHEN, X., NIYONSABA, F., USHIO, H., *et al.* (2005) Synergistic effect of antibacterial agents human beta-defensins, cathelicidin LL-37 and lysozyme against *Staphylococcus aureus* and *Escherichia coli*. *J Dermatol Sci*, 40, 123-32.
- CHO, Y. K., CHANG, H. S., LA, T. Y., *et al.* (2010) Anterior segment parameters using Pentacam and prediction of corneal endothelial cell loss after cataract surgery. *Korean J Ophthalmol*, 24, 284-90.
- CHODOSH, J. & KENNEDY, R. C. (2002) The conjunctival lymphoid follicle in mucosal immunology. *DNA Cell Biol*, 21, 421-33.
- CLARKE, D. W., ALIZADEH, H. & NIEDERKORN, J. Y. (2006) Intracorneal instillation of latex beads induces macrophage-dependent protection against *Acanthamoeba* keratitis. *Invest Ophthalmol Vis Sci*, 47, 4917-25.
- CLARKE, D. W. & NIEDERKORN, J. Y. (2006) The immunobiology of *Acanthamoeba* keratitis. *Microbes Infect*, 8, 1400-5.
- CONNOR, C. G., CAMPBELL, J. B., TIREY, W. W., *et al.* (1991) Modification of impression cytology for in-office use. *J Am Optom Assoc*, 62, 898-901.
- CONSTANTINOU, M., JHANJI, V., TAO, L. W., *et al.* (2009) Clinical review of corneal ulcers resulting in evisceration and enucleation in elderly population. *Graefes Arch Clin Exp Ophthalmol*, 247, 1389-93.
- CORDINGLEY, J. S., WILLS, R. A. & VILLEMEZ, C. L. (1996) Osmolarity is an independent trigger of *Acanthamoeba castellanii* differentiation. *J Cell Biochem*, 61, 167-71.
- COWLAND, J. B., JOHNSEN, A. H. & BORREGAARD, N. (1995) hCAP-18, a cathelin/pro-bactenecin-like protein of human neutrophil specific granules. *FEBS Lett*, 368, 173-6.
- DART, J. (1997) Impression cytology of the ocular surface--research tool or routine clinical investigation? *Br J Ophthalmol*, 81, 930.
- DART, J. K. (1988) Predisposing factors in microbial keratitis: the significance of contact lens wear. *Br J Ophthalmol*, 72, 926-30.
- DART, J. K., RADFORD, C. F., MINASSIAN, D., *et al.* (2008) Risk factors for microbial keratitis with contemporary contact lenses: a case-control study. *Ophthalmology*, 115, 1647-54, 1654 e1-3.

- DART, J. K., SAW, V. P. & KILVINGTON, S. (2009) Acanthamoeba keratitis: diagnosis and treatment update 2009. *Am J Ophthalmol*, 148, 487-499 e2.
- DART, J. K., STAPLETON, F. & MINASSIAN, D. (1991) Contact lenses and other risk factors in microbial keratitis. *Lancet*, 338, 650-3.
- DAS, S., CONSTANTINOU, M., DANIELL, M., *et al.* (2006) Moraxella keratitis: predisposing factors and clinical review of 95 cases. *Br J Ophthalmol*, 90, 1236-8.
- DAS, S., SHEOREY, H., TAYLOR, H. R., *et al.* (2007) Association between cultures of contact lens and corneal scraping in contact lens related microbial keratitis. *Arch Ophthalmol*, 125, 1182-5.
- DAXER, A., MISOF, K., GRABNER, B., *et al.* (1998) Collagen fibrils in the human corneal stroma: structure and aging. *Invest Ophthalmol Vis Sci*, 39, 644-8.
- DEPARTMENT OF BIOLOGY, D. C., DAVIDSON (2003) Real-Time PCR: The TaqMan® Method.
- DHOPLE, V., KRUKEMEYER, A. & RAMAMOORTHY, A. (2006) The human beta-defensin-3, an antibacterial peptide with multiple biological functions. *Biochim Biophys Acta*, 1758, 1499-512.
- DI NARDO, A., VITIELLO, A. & GALLO, R. L. (2003) Cutting edge: mast cell antimicrobial activity is mediated by expression of cathelicidin antimicrobial peptide. *J Immunol*, 170, 2274-8.
- DORSCHNER, R. A., LOPEZ-GARCIA, B., PESCHEL, A., *et al.* (2006) The mammalian ionic environment dictates microbial susceptibility to antimicrobial defense peptides. *FASEB J*, 20, 35-42.
- DUIJS, L. A., RAVENSBERGEN, B., RADEMAKER, M., *et al.* (2002) Expression of beta-defensin 1 and 2 mRNA by human monocytes, macrophages and dendritic cells. *Immunology*, 106, 517-25.
- EGBERT, P. R., LAUBER, S. & MAURICE, D. M. (1977) A simple conjunctival biopsy. *Am J Ophthalmol*, 84, 798-801.
- ELDER, M. J. & DART, J. K. (1995) Chemotherapy for acanthamoeba keratitis. *Lancet*, 345, 791-2; author reply 792-3.
- ERIE, J. C. (2003) Corneal wound healing after photorefractive keratectomy: a 3-year confocal microscopy study. *Trans Am Ophthalmol Soc*, 101, 293-333.
- ERIE, J. C., NEVITT, M. P., HODGE, D. O., *et al.* (1993) Incidence of ulcerative keratitis in a defined population from 1950 through 1988. *Arch Ophthalmol*, 111, 1665-71.
- ERIE, J. C., PATEL, S. V., MCLAREN, J. W., *et al.* (2003) Keratocyte density in the human cornea after photorefractive keratectomy. *Arch Ophthalmol*, 121, 770-6.

- FAZAKERLEY, J., CROSSLEY, J., MCEWAN, N., *et al.* (2010) In vitro antimicrobial efficacy of beta-defensin 3 against *Staphylococcus pseudintermedius* isolates from healthy and atopic canine skin. *Vet Dermatol*, 21, 463-8.
- FELDMAN, S. T., SPEAKER, M. & CLEVELAND, P. (1991) Effect of magainins on *Acanthamoeba castellanii*. *Rev Infect Dis*, 13 Suppl 5, S439.
- FERNANDO H MURILLO-LOPEZ, M. (2010) E-medicine Ophthalmology. WebMD.
- FICKER, L., SEAL, D., WARHURST, D., *et al.* (1990) *Acanthamoeba* keratitis--resistance to medical therapy. *Eye*, 4 (Pt 6), 835-8.
- FINI, M. E. (1999) Keratocyte and fibroblast phenotypes in the repairing cornea. *Prog Retin Eye Res*, 18, 529-51.
- FINLAY, B. B. & HANCOCK, R. E. (2004) Can innate immunity be enhanced to treat microbial infections? *Nat Rev Microbiol*, 2, 497-504.
- FLANAGAN, J. L. & WILLCOX, M. D. (2009) Role of lactoferrin in the tear film. *Biochimie*, 91, 35-43.
- FLEIGE, S. & PFAFFL, M. W. (2006) RNA integrity and the effect on the real-time qRT-PCR performance. *Mol Aspects Med*, 27, 126-39.
- FREIDIN, M. B., BHUDIA, N., LIM, E., *et al.* Impact of collection and storage of lung tumor tissue on whole genome expression profiling. *J Mol Diagn*, 14, 140-8.
- GALARRETA, D. J., TUFT, S. J., RAMSAY, A., *et al.* (2007) Fungal keratitis in London: microbiological and clinical evaluation. *Cornea*, 26, 1082-6.
- GANZ, T. (1987) Extracellular release of antimicrobial defensins by human polymorphonuclear leukocytes. *Infect Immun*, 55, 568-71.
- GANZ, T. (2003) Defensins: antimicrobial peptides of innate immunity. *Nat Rev Immunol*, 3, 710-20.
- GANZ, T. (2006) Hepcidin--a peptide hormone at the interface of innate immunity and iron metabolism. *Curr Top Microbiol Immunol*, 306, 183-98.
- GANZ, T., SELSTED, M. E., SZKLAREK, D., *et al.* (1985) Defensins. Natural peptide antibiotics of human neutrophils. *J Clin Invest*, 76, 1427-35.
- GANZ, T. & WEISS, J. (1997) Antimicrobial peptides of phagocytes and epithelia. *Semin Hematol*, 34, 343-54.
- GARCIA, J. R., JAUMANN, F., SCHULZ, S., *et al.* (2001a) Identification of a novel, multifunctional beta-defensin (human beta-defensin 3) with specific antimicrobial activity. Its interaction with plasma

membranes of *Xenopus* oocytes and the induction of macrophage chemoattraction. *Cell Tissue Res*, 306, 257-64.

- GARCIA, J. R., KRAUSE, A., SCHULZ, S., *et al.* (2001b) Human beta-defensin 4: a novel inducible peptide with a specific salt-sensitive spectrum of antimicrobial activity. *FASEB J*, 15, 1819-21.
- GARG, P. (2010) Diagnosis of microbial keratitis. *Br J Ophthalmol*, 94, 961-2.
- GARREIS, F., GOTTSCHALT, M. & PAULSEN, F. P. (2010a) Antimicrobial peptides as a major part of the innate immune defense at the ocular surface. *Dev Ophthalmol*, 45, 16-22.
- GARREIS, F., SCHLORF, T., WORLITZSCH, D., *et al.* (2010b) Roles of human beta-defensins in innate immune defense at the ocular surface: arming and alarming corneal and conjunctival epithelial cells. *Histochem Cell Biol*, 134, 59-73.
- GATTI, S., CEVINI, C., BRUNO, A., *et al.* (1998) In vitro effectiveness of povidone-iodine on *Acanthamoeba* isolates from human cornea. *Antimicrob Agents Chemother*, 42, 2232-4.
- GICQUEL, J. J., BEJJANI, R. A., ELLIES, P., *et al.* (2007) Amniotic membrane transplantation in severe bacterial keratitis. *Cornea*, 26, 27-33.
- GIPSON, I. K., SPURR-MICHAUD, S., ARGUESO, P., *et al.* (2003) Mucin gene expression in immortalized human corneal-limbal and conjunctival epithelial cell lines. *Invest Ophthalmol Vis Sci*, 44, 2496-506.
- GOKHALE, N. S. (2008) Medical management approach to infectious keratitis. *Indian J Ophthalmol*, 56, 215-20.
- GORDON, Y. J., HUANG, L. C., ROMANOWSKI, E. G., *et al.* (2005a) Human cathelicidin (LL-37), a multifunctional peptide, is expressed by ocular surface epithelia and has potent antibacterial and antiviral activity. *Curr Eye Res*, 30, 385-94.
- GORDON, Y. J., ROMANOWSKI, E. G. & MCDERMOTT, A. M. (2005b) A review of antimicrobial peptides and their therapeutic potential as anti-infective drugs. *Curr Eye Res*, 30, 505-15.
- GORLIN, A. I., GABRIEL, M. M., WILSON, L. A., *et al.* (1996) Effect of adhered bacteria on the binding of *Acanthamoeba* to hydrogel lenses. *Arch Ophthalmol*, 114, 576-80.
- GOTTSCH, J. D., LI, Q., ASHRAF, M. F., *et al.* (1998) Defensin gene expression in the cornea. *Curr Eye Res*, 17, 1082-6.
- GREGORI, N. Z., SCHIFFMAN, J. C., MILLER, D. M., *et al.* (2006) Clinical trial of povidone-iodine (Betadine) versus placebo in the pretreatment of corneal ulcers. *Cornea*, 25, 558-63.

- GROPP, R., FRYE, M., WAGNER, T. O., *et al.* (1999) Epithelial defensins impair adenoviral infection: implication for adenovirus-mediated gene therapy. *Hum Gene Ther*, 10, 957-64.
- HANCOCK, R. E. & SAHL, H. G. (2006) Antimicrobial and host-defense peptides as new anti-infective therapeutic strategies. *Nat Biotechnol*, 24, 1551-7.
- HANNA, C., BICKNELL, D. S. & O'BRIEN, J. E. (1961) Cell turnover in the adult human eye. *Arch Ophthalmol*, 65, 695-8.
- HARDER, J., BARTELS, J., CHRISTOPHERS, E., *et al.* (1997) A peptide antibiotic from human skin. *Nature*, 387, 861.
- HARDER, J., BARTELS, J., CHRISTOPHERS, E., *et al.* (2001) Isolation and characterization of human beta -defensin-3, a novel human inducible peptide antibiotic. *J Biol Chem*, 276, 5707-13.
- HARDER, J. & SCHRODER, J. M. (2002) RNase 7, a novel innate immune defense antimicrobial protein of healthy human skin. *J Biol Chem*, 277, 46779-84.
- HARWIG, S. S., GANZ, T. & LEHRER, R. I. (1994) Neutrophil defensins: purification, characterization, and antimicrobial testing. *Methods Enzymol*, 236, 160-72.
- HAYNES, R. J., TIGHE, P. J. & DUA, H. S. (1998) Innate defence of the eye by antimicrobial defensin peptides. *Lancet*, 352, 451-2.
- HAYNES, R. J., TIGHE, P. J. & DUA, H. S. (1999) Antimicrobial defensin peptides of the human ocular surface. *Br J Ophthalmol*, 83, 737-41.
- HAZLETT, L. D. (2004) Corneal response to *Pseudomonas aeruginosa* infection. *Prog Retin Eye Res*, 23, 1-30.
- HEILIGENHAUS, A., LI, H., HERNANDEZ GALINDO, E. E., *et al.* (2003) Management of acute ulcerative and necrotising herpes simplex and zoster keratitis with amniotic membrane transplantation. *Br J Ophthalmol*, 87, 1215-9.
- HELWA, R. & HOHEISEL, J. D. (2010) Analysis of DNA-protein interactions: from nitrocellulose filter binding assays to microarray studies. *Anal Bioanal Chem*, 398, 2551-61.
- HILL, J. C. (1986) Use of penetrating keratoplasty in acute bacterial keratitis. *Br J Ophthalmol*, 70, 502-6.
- HITI, K., WALOCHNIK, J., MARIA HALLER-SCHOBBER, E., *et al.* (2006) Efficacy of contact lens storage solutions against different acanthamoeba strains. *Cornea*, 25, 423-7.
- HOCQUELLET, A., ODAERT, B., CABANNE, C., *et al.* (2009) Structure-activity relationship of human liver-expressed antimicrobial peptide 2. *Peptides*.

- HOOI, S. H. & HOOI, S. T. (2005) Culture-proven bacterial keratitis in a Malaysian general hospital. *Med J Malaysia*, 60, 614-23.
- HOOVER, D. M., RAJASHANKAR, K. R., BLUMENTHAL, R., *et al.* (2000) The structure of human beta-defensin-2 shows evidence of higher order oligomerization. *J Biol Chem*, 275, 32911-8.
- HUANG, L. C., JEAN, D., PROSKE, R. J., *et al.* (2007a) Ocular surface expression and in vitro activity of antimicrobial peptides. *Curr Eye Res*, 32, 595-609.
- HUANG, L. C., PETKOVA, T. D., REINS, R. Y., *et al.* (2006) Multifunctional roles of human cathelicidin (LL-37) at the ocular surface. *Invest Ophthalmol Vis Sci*, 47, 2369-80.
- HUANG, L. C., REDFERN, R. L., NARAYANAN, S., *et al.* (2007b) In vitro activity of human beta-defensin 2 against *Pseudomonas aeruginosa* in the presence of tear fluid. *Antimicrob Agents Chemother*, 51, 3853-60.
- HUANG, Y. C., LIN, Y. M., CHANG, T. W., *et al.* (2007c) The flexible and clustered lysine residues of human ribonuclease 7 are critical for membrane permeability and antimicrobial activity. *J Biol Chem*, 282, 4626-33.
- HURT, M., NIEDERKORN, J. & ALIZADEH, H. (2003) Effects of mannose on *Acanthamoeba castellanii* proliferation and cytolytic ability to corneal epithelial cells. *Invest Ophthalmol Vis Sci*, 44, 3424-31.
- IBRAHIM, Y. W., BOASE, D. L. & CREE, I. A. (2009) Epidemiological characteristics, predisposing factors and microbiological profiles of infectious corneal ulcers: the Portsmouth corneal ulcer study. *Br J Ophthalmol*, 93, 1319-24.
- IKEDA, A., NAKANISHI, Y., SAKIMOTO, T., *et al.* (2006) Expression of beta defensins in ocular surface tissue of experimentally developed allergic conjunctivitis mouse model. *Jpn J Ophthalmol*, 50, 1-6.
- ILLINGWORTH, C. D. & COOK, S. D. (1998) *Acanthamoeba* keratitis. *Surv Ophthalmol*, 42, 493-508.
- KANSKI, J. J. (2011) Cornea. *Clinical Ophthalmology A Systematic Approach*. Seventh ed., Elsevier.
- JAISON, P. L., CAO, Z. & PANJWANI, N. (1998) Binding of *Acanthamoeba* to [corrected] mannose-glycoproteins of corneal epithelium: effect of injury. *Curr Eye Res*, 17, 770-6.
- JANEWAY, C. A., JR. & MEDZHITOV, R. (2002) Innate immune recognition. *Annu Rev Immunol*, 20, 197-216.
- JENSEN, T., BARNES, W. G. & MEYERS, D. (1970) Axenic cultivation of large populations of *Acanthamoeba castellanii* (JBM). *J Parasitol*, 56, 904-6.

- JIA, H. P., STARNER, T., ACKERMANN, M., *et al.* (2001) Abundant human beta-defensin-1 expression in milk and mammary gland epithelium. *J Pediatr*, 138, 109-12.
- JOLY, S., MAZE, C., MCCRAY, P. B., JR., *et al.* (2004) Human beta-defensins 2 and 3 demonstrate strain-selective activity against oral microorganisms. *J Clin Microbiol*, 42, 1024-9.
- JONES, D. E. & BEVINS, C. L. (1992) Paneth cells of the human small intestine express an antimicrobial peptide gene. *J Biol Chem*, 267, 23216-25.
- JOSEPH, J., SRIDHAR, M. S., MURTHY, S., *et al.* (2006) Clinical and microbiological profile of microsporidial keratoconjunctivitis in southern India. *Ophthalmology*, 113, 531-7.
- JOSLIN, C. E., TU, E. Y., MCMAHON, T. T., *et al.* (2006) Epidemiological characteristics of a Chicago-area Acanthamoeba keratitis outbreak. *Am J Ophthalmol*, 142, 212-7.
- KAGAN, B. L., GANZ, T. & LEHRER, R. I. (1994) Defensins: a family of antimicrobial and cytotoxic peptides. *Toxicology*, 87, 131-49.
- KALKANCI, A. & OZDEK, S. (2010) Ocular fungal infections. *Curr Eye Res*, 36, 179-89.
- KASHIWABUCHI, R. T., DE FREITAS, D., ALVARENGA, L. S., *et al.* (2008) Corneal graft survival after therapeutic keratoplasty for Acanthamoeba keratitis. *Acta Ophthalmol*, 86, 666-9.
- KAVANAGH, K. & DOWD, S. (2004) Histatins: antimicrobial peptides with therapeutic potential. *J Pharm Pharmacol*, 56, 285-9.
- KAYE, D. B. (1980) Epithelial response in penetrating keratoplasty. *Am J Ophthalmol*, 89, 381-7.
- KAYE, S. & CHOUDHARY, A. (2006) Herpes simplex keratitis. *Prog Retin Eye Res*, 25, 355-80.
- KEAY, L., EDWARDS, K., DART, J., *et al.* (2008) Grading contact lens-related microbial keratitis: relevance to disease burden. *Optom Vis Sci*, 85, 531-7.
- KEAY, L., EDWARDS, K., NADUVILATH, T., *et al.* (2006) Factors affecting the morbidity of contact lens-related microbial keratitis: a population study. *Invest Ophthalmol Vis Sci*, 47, 4302-8.
- KEAY, L., STAPLETON, F. & SCHEIN, O. (2007) Epidemiology of contact lens-related inflammation and microbial keratitis: a 20-year perspective. *Eye Contact Lens*, 33, 346-53, discussion 362-3.
- KIM, J. S., KIM, J. C., HAHN, T. W., *et al.* (2001) Amniotic membrane transplantation in infectious corneal ulcer. *Cornea*, 20, 720-6.
- KNOP, E. & KNOP, N. (2007) Anatomy and immunology of the ocular surface. *Chem Immunol Allergy*, 92, 36-49.

- KONSTANTOPOULOS, A., HOSSAIN, P. & ANDERSON, D. F. (2007) Recent advances in ophthalmic anterior segment imaging: a new era for ophthalmic diagnosis? *Br J Ophthalmol*, 91, 551-7.
- KONSTANTOPOULOS, A., KUO, J., ANDERSON, D., *et al.* (2008) Assessment of the use of anterior segment optical coherence tomography in microbial keratitis. *Am J Ophthalmol*, 146, 534-542.
- KRAUSE, A., NEITZ, S., MAGERT, H. J., *et al.* (2000) LEAP-1, a novel highly disulfide-bonded human peptide, exhibits antimicrobial activity. *FEBS Lett*, 480, 147-50.
- KRAUSE, M. S., DE CEUSTER, T. J., TIQUIA, S. M., *et al.* (2003) Isolation and characterization of rhizobacteria from composts that suppress the severity of bacterial leaf spot of radish. *Phytopathology*, 93, 1292-300.
- KUMAR, A., HAZLETT, L. D. & YU, F. S. (2008) Flagellin suppresses the inflammatory response and enhances bacterial clearance in a murine model of *Pseudomonas aeruginosa* keratitis. *Infect Immun*, 76, 89-96.
- KUMAR, A., TASSOPOULOS, A. M., LI, Q., *et al.* (2007a) Staphylococcus aureus protein A induced inflammatory response in human corneal epithelial cells. *Biochem Biophys Res Commun*, 354, 955-61.
- KUMAR, A., YIN, J., ZHANG, J., *et al.* (2007b) Modulation of corneal epithelial innate immune response to pseudomonas infection by flagellin pretreatment. *Invest Ophthalmol Vis Sci*, 48, 4664-70.
- KUMAR, A., ZHANG, J. & YU, F. S. (2004) Innate immune response of corneal epithelial cells to Staphylococcus aureus infection: role of peptidoglycan in stimulating proinflammatory cytokine secretion. *Invest Ophthalmol Vis Sci*, 45, 3513-22.
- KUMAR, A., ZHANG, J. & YU, F. S. (2006) Toll-like receptor 2-mediated expression of beta-defensin-2 in human corneal epithelial cells. *Microbes Infect*, 8, 380-9.
- KUMAR, M., MISHRA, N. K. & SHUKLA, P. K. (2005) Sensitive and rapid polymerase chain reaction based diagnosis of mycotic keratitis through single stranded conformation polymorphism. *Am J Ophthalmol*, 140, 851-857.
- KUO, I. C., MARGOLIS, T. P., CEVALLOS, V., *et al.* (2001) Aspergillus fumigatus keratitis after laser in situ keratomileusis. *Cornea*, 20, 342-4.
- LABBE, A., DUPAS, B., BENSOUSSAN, L., *et al.* (2006) Bilateral infectious ulcers associated with atopic keratoconjunctivitis. *Cornea*, 25, 248-50.

- LAM, D. S., HOUANG, E., FAN, D. S., *et al.* (2002) Incidence and risk factors for microbial keratitis in Hong Kong: comparison with Europe and North America. *Eye*, 16, 608-18.
- LARSEN, L. N., MALCHAU, E., KRISTENSEN, B., *et al.* (2011) Hydrochloric acid treatment of tunneled central venous catheter infections in children with cancer. *J Pediatr Hematol Oncol*, 33, e64-8.
- LAW SKA, R. K. (1995) Complement. IN RICKWOOD D, M. D. (Ed.) *Focus Series, 2nd ed*, Oxford, Oxford University Press.
- LEONOVA, L., KOKRYAKOV, V. N., ALESHINA, G., *et al.* (2001) Circular minidefensins and posttranslational generation of molecular diversity. *J Leukoc Biol*, 70, 461-4.
- LIBERATORE, M., PALA, A., SCACCIANOCE, S., *et al.* (2009) Microbial targeting of 99mTc-labeled recombinant human beta-defensin-3 in an animal model of infection: a feasibility pilot study. *J Nucl Med*, 50, 823-6.
- LINNARSSON, S. (2010) Recent advances in DNA sequencing methods - general principles of sample preparation. *Exp Cell Res*, 316, 1339-43.
- LOUIS, S. (1997) *Ocular Infection and Immunity*. Mosby.
- LY, C. N., PHAM, J. N., BADENOCH, P. R., *et al.* (2006) Bacteria commonly isolated from keratitis specimens retain antibiotic susceptibility to fluoroquinolones and gentamicin plus cephalothin. *Clin Experiment Ophthalmol*, 34, 44-50.
- MAISETTA, G., BRANCATISANO, F. L., ESIN, S., *et al.* (2011) Gingipains produced by *Porphyromonas gingivalis* ATCC49417 degrade human-beta-defensin 3 and affect peptide's antibacterial activity in vitro. *Peptides*, 32, 1073-7.
- MALTSEVA, I. A., FLEISZIG, S. M., EVANS, D. J., *et al.* (2007) Exposure of human corneal epithelial cells to contact lenses in vitro suppresses the upregulation of human beta-defensin-2 in response to antigens of *Pseudomonas aeruginosa*. *Exp Eye Res*, 85, 142-53.
- MANNIS, M. J. (2002) The use of antimicrobial peptides in ophthalmology: an experimental study in corneal preservation and the management of bacterial keratitis. *Trans Am Ophthalmol Soc*, 100, 243-71.
- MARANGON, F. B., MILLER, D. & ALFONSO, E. C. (2004a) Impact of prior therapy on the recovery and frequency of corneal pathogens. *Cornea*, 23, 158-64.
- MARANGON, F. B., MILLER, D., MUALLEM, M. S., *et al.* (2004b) Ciprofloxacin and levofloxacin resistance among methicillin-sensitive *Staphylococcus aureus* isolates from keratitis and conjunctivitis. *Am J Ophthalmol*, 137, 453-8.

- MARR, A. K., GOODERHAM, W. J. & HANCOCK, R. E. (2006) Antibacterial peptides for therapeutic use: obstacles and realistic outlook. *Curr Opin Pharmacol*, 6, 468-72.
- MATHERS, W. D., NELSON, S. E., LANE, J. L., *et al.* (2000) Confirmation of confocal microscopy diagnosis of Acanthamoeba keratitis using polymerase chain reaction analysis. *Arch Ophthalmol*, 118, 178-83.
- MATSUDA, J., HIEDA, O. & KINOSHITA, S. (2007) [Quantification of corneal opacity after refractive corneal surgery using the anterior segment analyzer]. *Nippon Ganka Gakkai Zasshi*, 111, 447-53.
- MATSUZAKI, K., SUGISHITA, K., FUJII, N., *et al.* (1995) Molecular basis for membrane selectivity of an antimicrobial peptide, magainin 2. *Biochemistry*, 34, 3423-9.
- MAURICE, D. M. (1957) The structure and transparency of the cornea. *J Physiol*, 136, 263-86.
- MCNAMARA, N. N., VAN, R., TUCHIN, O. S., *et al.* (1999) Ocular surface epithelia express mRNA for human beta defensin-2. *Exp Eye Res*, 69, 483-90.
- MCCRAY, P. B., JR. & BENTLEY, L. (1997) Human airway epithelia express a beta-defensin. *Am J Respir Cell Mol Biol*, 16, 343-9.
- MCCULLEY, J. P., ALIZADEH, H. & NIEDERKORN, J. Y. (2000) The diagnosis and management of Acanthamoeba keratitis. *CLAO J*, 26, 47-51.
- MCDERMOTT, A. M. (2004) Defensins and other antimicrobial peptides at the ocular surface. *Ocul Surf*, 2, 229-47.
- MCDERMOTT, A. M. (2009) The role of antimicrobial peptides at the ocular surface. *Ophthalmic Res*, 41, 60-75.
- MCDERMOTT, A. M., REDFERN, R. L. & ZHANG, B. (2001) Human beta-defensin 2 is up-regulated during re-epithelialization of the cornea. *Curr Eye Res*, 22, 64-7.
- MCDERMOTT, A. M., REDFERN, R. L., ZHANG, B., *et al.* (2003) Defensin expression by the cornea: multiple signalling pathways mediate IL-1beta stimulation of hBD-2 expression by human corneal epithelial cells. *Invest Ophthalmol Vis Sci*, 44, 1859-65.
- MCDERMOTT, A. M., RICH, D., CULLOR, J., *et al.* (2006) The in vitro activity of selected defensins against an isolate of Pseudomonas in the presence of human tears. *Br J Ophthalmol*, 90, 609-11.
- MCINTOSH, R. S., CADE, J. E., AL-ABED, M., *et al.* (2005) The spectrum of antimicrobial peptide expression at the ocular surface. *Invest Ophthalmol Vis Sci*, 46, 1379-85.
- MCLEOD, S. D., KOLAHDOUZ-ISFAHANI, A., ROSTAMIAN, K., *et al.* (1996) The role of smears, cultures, and antibiotic sensitivity

- testing in the management of suspected infectious keratitis. *Ophthalmology*, 103, 23-8.
- MENDEZ-SAMPERIO, P. (2010) The human cathelicidin hCAP18/LL-37: a multifunctional peptide involved in mycobacterial infections. *Peptides*, 31, 1791-8.
- MERKLINGER, H. M. (1992) The Scheimpflug Principle - Part I. 1 November 1992 ed., Shutterbug.
- MITRA, M. M., ALIZADEH, H., GERARD, R. D., *et al.* (1995) Characterization of a plasminogen activator produced by *Acanthamoeba castellanii*. *Mol Biochem Parasitol*, 73, 157-64.
- MITRO, K., BHAGAVATHIAMMAI, A., ZHOU, O. M., *et al.* (1994) Partial characterization of the proteolytic secretions of *Acanthamoeba polyphaga*. *Exp Parasitol*, 78, 377-85.
- MOGENSEN, T. H. (2009) Pathogen recognition and inflammatory signaling in innate immune defenses. *Clin Microbiol Rev*, 22, 240-73, Table of Contents.
- MOHAMMED, I., ABEDIN, A., TSINTZAS, K., *et al.* (2011) Increased expression of hepcidin and toll-like receptors 8 and 10 in viral keratitis. *Cornea*, 30, 899-904.
- MOHAMMED, I., SULEMAN, H., OTRI, A. M., *et al.* (2010a) Localization and gene expression of human beta-defensin 9 at the human ocular surface epithelium. *Invest Ophthalmol Vis Sci*, 51, 4677-82.
- MOHAMMED, I., YEUNG, A., ABEDIN, A., *et al.* (2010b) Signalling pathways involved in ribonuclease-7 expression. *Cell Mol Life Sci*.
- MOILANEN, J. A., VESALUOMA, M. H., MULLER, L. J., *et al.* (2003) Long-term corneal morphology after PRK by in vivo confocal microscopy. *Invest Ophthalmol Vis Sci*, 44, 1064-9.
- MOLLEE, T., KELLY, P. & TILSE, M. (1992) Isolation of *Kingella kingae* from a corneal ulcer. *J Clin Microbiol*, 30, 2516-7.
- MONDINO, B. J. & BRADY, K. J. (1981) Distribution of hemolytic complement in the normal cornea. *Arch Ophthalmol*, 99, 1430-3.
- MOSHIRFAR, M., MIRZAIAN, G., FEIZ, V., *et al.* (2006) Fourth-generation fluoroquinolone-resistant bacterial keratitis after refractive surgery. *J Cataract Refract Surg*, 32, 515-8.
- MOUSSA, S., IBRAHIM, A., OKBA, A., *et al.* (2009) Antibacterial action of acetic acid soluble material isolated from *Mucor rouxii* and its application onto textile. *Int J Biol Macromol*, 48, 736-41.
- MULHOLLAND, B., TUFT, S. J. & KHAW, P. T. (2005) Matrix metalloproteinase distribution during early corneal wound healing. *Eye*, 19, 584-8.

- MULLER, L. J., PELS, L. & VRENSSEN, G. F. (1996) Ultrastructural organization of human corneal nerves. *Invest Ophthalmol Vis Sci*, 37, 476-88.
- MURAKAMI, M., OHTAKE, T., DORSCHNER, R. A., *et al.* (2002) Cathelicidin anti-microbial peptide expression in sweat, an innate defense system for the skin. *J Invest Dermatol*, 119, 1090-5.
- Yanoff, M., Duker, J. (2004) Infectious keratitis. *Ophthalmology*. Second ed., Mosby.
- NA, B. K., CHO, J. H., SONG, C. Y., *et al.* (2002) Degradation of immunoglobulins, protease inhibitors and interleukin-1 by a secretory proteinase of *Acanthamoeba castellanii*. *Korean J Parasitol*, 40, 93-9.
- NAGAOKA, I., HIROTA, S., YOMOGIDA, S., *et al.* (2000) Synergistic actions of antibacterial neutrophil defensins and cathelicidins. *Inflamm Res*, 49, 73-9.
- NAGOBA, B. S., DESHMUKH, S. R., WADHER, B. J., *et al.* (1997) Acetic acid treatment of pseudomonal postoperative wound infection. *J Hosp Infect*, 36, 243-4.
- NARAYANAN, S., MILLER, W. L. & MCDERMOTT, A. M. (2003) Expression of human beta-defensins in conjunctival epithelium: relevance to dry eye disease. *Invest Ophthalmol Vis Sci*, 44, 3795-801.
- NIYONSABA, F., SOMEYA, A., HIRATA, M., *et al.* (2001) Evaluation of the effects of peptide antibiotics human beta-defensins-1/-2 and LL-37 on histamine release and prostaglandin D(2) production from mast cells. *Eur J Immunol*, 31, 1066-75.
- NUDING, S., ZABEL, L. T., ENDERS, C., *et al.* (2009) Antibacterial activity of human defensins on anaerobic intestinal bacterial species: a major role of HBD-3. *Microbes Infect*, 11, 384-93.
- O'BRIEN, T. P., MAGUIRE, M. G., FINK, N. E., *et al.* (1995) Efficacy of ofloxacin vs cefazolin and tobramycin in the therapy for bacterial keratitis. Report from the Bacterial Keratitis Study Research Group. *Arch Ophthalmol*, 113, 1257-65.
- O'DONNELL, C. & WOLFFSOHN, J. S. (2004) Grading of corneal transparency. *Cont Lens Anterior Eye*, 27, 161-70.
- OCULUS (2003) *Pentacam Instruction Manual*, Wetzlar, Germany.
- OMANA-MOLINA, M., GONZALEZ-ROBLES, A., SALAZAR-VILLATORO, L. I., *et al.* (2010) *Acanthamoeba castellanii*: morphological analysis of the interaction with human cornea. *Exp Parasitol*, 126, 73-8.
- OOI, E. H., WORMALD, P. J., CARNEY, A. S., *et al.* (2007) Fungal allergens induce cathelicidin LL-37 expression in chronic

- rhinosinusitis patients in a nasal explant model. *Am J Rhinol*, 21, 367-72.
- OPPENHEIM, J. J. & YANG, D. (2005) Alarmins: chemotactic activators of immune responses. *Curr Opin Immunol*, 17, 359-65.
- ORMEROD, L. D. & SMITH, R. E. (1986) Contact lens-associated microbial keratitis. *Arch Ophthalmol*, 104, 79-83.
- OSTLER HB, O. M. (1993) Diseases of the cornea. *Diseases of the external eye and adnexa: a text and atlas*. Baltimore, Williams & Wilkins.
- OTRI, A. M., MOHAMMED, I., ABEDIN, A., *et al.* (2010) Antimicrobial peptides expression by ocular surface cells in response to *Acanthamoeba castellanii*: an in vitro study. *Br J Ophthalmol*, 94, 1523-7.
- OTRI, A. M., MOHAMMED, I., AL-AQABA, M. A., *et al.* (2012) Variable expression of human beta defensins 3 and 9 at the human ocular surface in Infectious Keratitis. *Invest Ophthalmol Vis Sci*.
- OZBEK, Z., KANG, S., SIVALINGAM, J., *et al.* (2006) Voriconazole in the management of *Alternaria* keratitis. *Cornea*, 25, 242-4.
- PACHIGOLLA, G., BLOMQUIST, P. & CAVANAGH, H. D. (2007) Microbial keratitis pathogens and antibiotic susceptibilities: a 5-year review of cases at an urban county hospital in north Texas. *Eye Contact Lens*, 33, 45-9.
- PANDA, A., SATPATHY, G., NAYAK, N., *et al.* (2007) Demographic pattern, predisposing factors and management of ulcerative keratitis: evaluation of one thousand unilateral cases at a tertiary care centre. *Clin Experiment Ophthalmol*, 35, 44-50.
- PANJWANI, N. (2010) Pathogenesis of *acanthamoeba* keratitis. *Ocul Surf*, 8, 70-9.
- PARMAR, D. N., AWWAD, S. T., PETROLL, W. M., *et al.* (2006a) Tandem scanning confocal corneal microscopy in the diagnosis of suspected *acanthamoeba* keratitis. *Ophthalmology*, 113, 538-47.
- PARMAR, P., SALMAN, A., KALAVATHY, C. M., *et al.* (2006b) Microbial keratitis at extremes of age. *Cornea*, 25, 153-8.
- PATEL, N. R., REIDY, J. J. & GONZALEZ-FERNANDEZ, F. (2005) *Nocardia* keratitis after laser in situ keratomileusis: clinicopathologic correlation. *J Cataract Refract Surg*, 31, 2012-5.
- PAULSEN, F. P., PUFE, T., SCHAUDIG, U., *et al.* (2001) Detection of natural peptide antibiotics in human nasolacrimal ducts. *Invest Ophthalmol Vis Sci*, 42, 2157-63.
- PFISTER, D. R., CAMERON, J. D., KRACHMER, J. H., *et al.* (1996) Confocal microscopy findings of *Acanthamoeba* keratitis. *Am J Ophthalmol*, 121, 119-28.

- PIGEON, C., ILYIN, G., COURSELAUD, B., *et al.* (2001) A new mouse liver-specific gene, encoding a protein homologous to human antimicrobial peptide hepcidin, is overexpressed during iron overload. *J Biol Chem*, 276, 7811-9.
- PILLAI, C. T., DUA, H. S. & HOSSAIN, P. (2000) Fine needle diathermy occlusion of corneal vessels. *Invest Ophthalmol Vis Sci*, 41, 2148-53.
- POR, Y. M., MEHTA, J. S., CHUA, J. L., *et al.* (2009) Acanthamoeba keratitis associated with contact lens wear in Singapore. *Am J Ophthalmol*, 148, 7-12 e2.
- PREMRATANACHAI, P., JOLY, S., JOHNSON, G. K., *et al.* (2004) Expression and regulation of novel human beta-defensins in gingival keratinocytes. *Oral Microbiol Immunol*, 19, 111-7.
- PROCHAZKOVA, S., NETUKOVA, M., KLECKA, D., *et al.* [Lasik after corneal ulcer]. *Cesk Slov Oftalmol*, 67, 86-9.
- PROKOSCH, V., GATZIOUFAS, Z., THANOS, S., *et al.* (2011) Microbiological findings and predisposing risk factors in corneal ulcers. *Graefes Arch Clin Exp Ophthalmol*.
- QUAYLE, A. J., PORTER, E. M., NUSSBAUM, A. A., *et al.* (1998) Gene expression, immunolocalization, and secretion of human defensin-5 in human female reproductive tract. *Am J Pathol*, 152, 1247-58.
- REDFERN, R. L., REINS, R. Y. & MCDERMOTT, A. M. (2011) Toll-like receptor activation modulates antimicrobial peptide expression by ocular surface cells. *Exp Eye Res*.
- REITHMAYER, K., MEYER, K. C., KLEDITZSCH, P., *et al.* (2009) Human hair follicle epithelium has an antimicrobial defence system that includes the inducible antimicrobial peptide psoriasin (S100A7) and RNase 7. *Br J Dermatol*, 161, 78-89.
- RHEE, M. S., LEE, S. Y., DOUGHERTY, R. H., *et al.* (2003) Antimicrobial effects of mustard flour and acetic acid against Escherichia coli O157:H7, Listeria monocytogenes, and Salmonella enterica serovar Typhimurium. *Appl Environ Microbiol*, 69, 2959-63.
- RIEG, S., MEIER, B., FAHRNICH, E., *et al.* (2010) Differential activity of innate defense antimicrobial peptides against Nocardia species. *BMC Microbiol*, 10, 61.
- ROBERTSON, D. M., PETROLL, W. M., JESTER, J. V., *et al.* (2007) Current concepts: contact lens related Pseudomonas keratitis. *Cont Lens Anterior Eye*, 30, 94-107.
- SACRAMENTO, R. S., MARTINS, R. M., MIRANDA, A., *et al.* (2009) Differential effects of alpha-helical and beta-hairpin antimicrobial peptides against Acanthamoeba castellanii. *Parasitology*, 136, 813-21.

- SAEED, A., D'ARCY, F., STACK, J., *et al.* (2009) Risk factors, microbiological findings, and clinical outcomes in cases of microbial keratitis admitted to a tertiary referral center in Ireland. *Cornea*, 28, 285-92.
- SAHLY, H., SCHUBERT, S., HARDER, J., *et al.* (2003) Burkholderia is highly resistant to human Beta-defensin 3. *Antimicrob Agents Chemother*, 47, 1739-41.
- SAID, D. G., OTRI, M., MIRI, A., *et al.* (2011) The challenge of fungal keratitis. *Br J Ophthalmol*, 95, 1623-4.
- SANG, Y. & BLECHA, F. (2008) Antimicrobial peptides and bacteriocins: alternatives to traditional antibiotics. *Anim Health Res Rev*, 9, 227-35.
- SAWADA, Y., YUAN, C. & HUANG, A. J. (2004) Impression cytology in the diagnosis of acanthamoeba keratitis with surface involvement. *Am J Ophthalmol*, 137, 323-8.
- SCHAEFER, F., BRUTTIN, O., ZOGRAFOS, L., *et al.* (2001) Bacterial keratitis: a prospective clinical and microbiological study. *Br J Ophthalmol*, 85, 842-7.
- SCHIBLI, D. J., HUNTER, H. N., ASEYEV, V., *et al.* (2002) The solution structures of the human beta-defensins lead to a better understanding of the potent bactericidal activity of HBD3 against Staphylococcus aureus. *J Biol Chem*, 277, 8279-89.
- SCHUSTER, F. L. & JACOB, L. S. (1992) Effects of magainins on ameba and cyst stages of Acanthamoeba polyphaga. *Antimicrob Agents Chemother*, 36, 1263-71.
- SCHWAB, I. R., DRIES, D., CULLOR, J., *et al.* (1992) Corneal storage medium preservation with defensins. *Cornea*, 11, 370-5.
- SCUDIERO, O., GALDIERO, S., CANTISANI, M., *et al.* (2010) Novel synthetic, salt-resistant analogs of human beta-defensins 1 and 3 endowed with enhanced antimicrobial activity. *Antimicrob Agents Chemother*, 54, 2312-22.
- SEAL, D., HAY, J., KIRKNESS, C., *et al.* (1996) Successful medical therapy of Acanthamoeba keratitis with topical chlorhexidine and propamidine. *Eye*, 10 (Pt 4), 413-21.
- SEAL, D. V., KIRKNESS, C. M., BENNETT, H. G., *et al.* (1999) Population-based cohort study of microbial keratitis in Scotland: incidence and features. *Cont Lens Anterior Eye*, 22, 49-57.
- SEITZMAN, G. D., CEVALLOS, V. & MARGOLIS, T. P. (2006) Rose bengal and lissamine green inhibit detection of herpes simplex virus by PCR. *Am J Ophthalmol*, 141, 756-8.
- SHANKAR, H., TARANATH, D., SANTHIRATHELAGAN, C. T., *et al.* (2008a) Anterior segment biometry with the Pentacam:

comprehensive assessment of repeatability of automated measurements. *J Cataract Refract Surg*, 34, 103-13.

- SHANKAR, H., TARANATH, D., SANTHIRATHELAGAN, C. T., *et al.* (2008b) Repeatability of corneal first-surface wavefront aberrations measured with Pentacam corneal topography. *J Cataract Refract Surg*, 34, 727-34.
- SHARMA, N., SACHDEV, R., JHANJI, V., *et al.* (2010) Therapeutic keratoplasty for microbial keratitis. *Curr Opin Ophthalmol*, 21, 293-300.
- SHARMA, N., SINHA, R., SINGHVI, A., *et al.* (2006) Pseudomonas keratitis after laser in situ keratomileusis. *J Cataract Refract Surg*, 32, 519-21.
- SIKULU, M., DOWELL, K. M., HUGO, L. E., *et al.* (2011) Evaluating RNAlater(R) as a preservative for using near-infrared spectroscopy to predict *Anopheles gambiae* age and species. *Malar J*, 10, 186.
- SINGH, R., JOSEPH, A., UMAPATHY, T., *et al.* (2005) Impression cytology of the ocular surface. *Br J Ophthalmol*, 89, 1655-9.
- SNELL, R., LEMP, M.. (1998) Clinical anatomy of the eye. Blackwell Science Inc.
- SONG, W., SHI, Y., XIAO, M., *et al.* (2009) In vitro bactericidal activity of recombinant human beta-defensin-3 against pathogenic bacterial strains in human tooth root canal. *Int J Antimicrob Agents*, 33, 237-43.
- SOUSA, L. B., MANNIS, M. J., SCHWAB, I. R., *et al.* (1996) The use of synthetic Cecropin (D5C) in disinfecting contact lens solutions. *CLAO J*, 22, 114-7.
- SRIDHAR, M. S., GARG, P., BANSAL, A. K., *et al.* (2000) Fungal keratitis after laser in situ keratomileusis. *J Cataract Refract Surg*, 26, 613-5.
- SRIDHAR, M. S., SHARMA, S., GOPINATHAN, U., *et al.* (2002) Anterior chamber tap: diagnostic and therapeutic indications in the management of ocular infections. *Cornea*, 21, 718-22.
- SRINIVASAN, M., MASCARENHAS, J., RAJARAMAN, R., *et al.* Corticosteroids for Bacterial Keratitis: The Steroids for Corneal Ulcers Trial (SCUT). *Arch Ophthalmol*.
- STARNER, T. D., AGERBERTH, B., GUDMUNDSSON, G. H., *et al.* (2005) Expression and activity of beta-defensins and LL-37 in the developing human lung. *J Immunol*, 174, 1608-15.
- STARNER, T. D., SWORDS, W. E., APICELLA, M. A., *et al.* (2002) Susceptibility of nontypeable *Haemophilus influenzae* to human beta-defensins is influenced by lipooligosaccharide acylation. *Infect Immun*, 70, 5287-9.

- STEFAN, C. & NENCIU, A. (2006) Post-traumatic bacterial keratitis--a microbiological prospective clinical study. *Oftalmologia*, 50, 118-22.
- STEINBERG, E. P., TIELSCH, J. M., SCHEIN, O. D., *et al.* (1994) The VF-14. An index of functional impairment in patients with cataract. *Arch Ophthalmol*, 112, 630-8.
- SUN, X., ZHANG, Y., LI, R., *et al.* (2006a) Acanthamoeba keratitis: clinical characteristics and management. *Ophthalmology*, 113, 412-6.
- SUN, X., ZHAO, H., DENG, S., *et al.* (2006b) Infectious keratitis related to orthokeratology. *Ophthalmic Physiol Opt*, 26, 133-6.
- SUNDARRAJ, N., GEISS, M. J., 3RD, FANTES, F., *et al.* (1990) Healing of excimer laser ablated monkey corneas. An immunohistochemical evaluation. *Arch Ophthalmol*, 108, 1604-10.
- TAKACS, A. I., MIHALTZ, K. & NAGY, Z. Z. (1995) Corneal Density with the Pentacam After Photorefractive Keratectomy. *J Refract Surg*, 1-9.
- TANG, Y. Q., YEAMAN, M. R. & SELSTED, M. E. (2002) Antimicrobial peptides from human platelets. *Infect Immun*, 70, 6524-33.
- TANHEHCO, T. & COLBY, K. (2010) The clinical experience of Acanthamoeba keratitis at a tertiary care eye hospital. *Cornea*, 29, 1005-10.
- THACORE, H. R., MOUNT, D. T. & CHADHA, K. C. (1982) Interferon system of human cornea cells: interferon production, characterization, and development of antiviral state. *J Interferon Res*, 2, 401-8.
- THIEL, M. A., BOSSART, W. & BERNAUER, W. (1998) [Clinical evaluation of impression cytology in diagnosis of superficial viral infections]. *Klin Monbl Augenheilkd*, 212, 388-91.
- THOMAS, P. A. (2003) Fungal infections of the cornea. *Eye*, 17, 852-62.
- THOMAS, P. A. & GERALDINE, P. (2007) Infectious keratitis. *Curr Opin Infect Dis*, 20, 129-41.
- THORP, M. A., KRUGER, J., OLIVER, S., *et al.* (1998) The antibacterial activity of acetic acid and Burow's solution as topical otological preparations. *J Laryngol Otol*, 112, 925-8.
- TITIYAL, J. S., NEGI, S., ANAND, A., *et al.* (2006) Risk factors for perforation in microbial corneal ulcers in north India. *Br J Ophthalmol*, 90, 686-9.
- TORRENT, M., BADIA, M., MOUSSAOUI, M., *et al.* (2010) Comparison of human RNase 3 and RNase 7 bactericidal action at the Gram-negative and Gram-positive bacterial cell wall. *FEBS J*, 277, 1713-25.

- TOWNES, C. L., MICHAELIDIS, G. & HALL, J. (2009) The interaction of the antimicrobial peptide cLEAP-2 and the bacterial membrane. *Biochem Biophys Res Commun*, 387, 500-3.
- TRAN, M. T., LAUSCH, R. N. & OAKES, J. E. (2000) Substance P differentially stimulates IL-8 synthesis in human corneal epithelial cells. *Invest Ophthalmol Vis Sci*, 41, 3871-7.
- TROCME, S. D. & ALDAVE, A. J. (1994) The eye and the eosinophil. *Surv Ophthalmol*, 39, 241-52.
- TSENG, S. C. (1985) Staging of conjunctival squamous metaplasia by impression cytology. *Ophthalmology*, 92, 728-33.
- TULI, S. S., SCHULTZ, G. S. & DOWNER, D. M. (2007) Science and strategy for preventing and managing corneal ulceration. *Ocul Surf*, 5, 23-39.
- TYTLER, E. M., ANANTHARAMAIAH, G. M., WALKER, D. E., *et al.* (1995) Molecular basis for prokaryotic specificity of magainin-induced lysis. *Biochemistry*, 34, 4393-401.
- UETA, M. & KINOSHITA, S. (2009) Innate immunity of the ocular surface. *Brain Res Bull*.
- UMAPATHY, T., SINGH, R., DUA, H. S., *et al.* (2005) Non-tuberculous mycobacteria related infectious crystalline keratopathy. *Br J Ophthalmol*, 89, 1374-5.
- UNDERHILL, D. M. & OZINSKY, A. (2002) Phagocytosis of microbes: complexity in action. *Annu Rev Immunol*, 20, 825-52.
- VADDAVALLI, P. K., GARG, P., SHARMA, S., *et al.* (2006) Confocal microscopy for Nocardia keratitis. *Ophthalmology*, 113, 1645-50.
- VAJPAYEE, R. B., SHARMA, N., SINHA, R., *et al.* (2007) Infectious keratitis following keratoplasty. *Surv Ophthalmol*, 52, 1-12.
- VAJPAYEE, R. B., SINGHVI, A., SHARMA, N., *et al.* (2006) Penetrating keratoplasty for perforated corneal ulcers: preservation of iris by corneal debulking. *Cornea*, 25, 44-6.
- VALORE, E. V. & GANZ, T. (1992) Posttranslational processing of defensins in immature human myeloid cells. *Blood*, 79, 1538-44.
- VALORE, E. V., PARK, C. H., QUAYLE, A. J., *et al.* (1998) Human beta-defensin-1: an antimicrobial peptide of urogenital tissues. *J Clin Invest*, 101, 1633-42.
- VAN DE POL, C., SOYA, K. & HWANG, D. G. (2001) Objective assessment of transient corneal haze and its relation to visual performance after photorefractive keratectomy. *Am J Ophthalmol*, 132, 204-10.
- VEMUGANTI, G. K., REDDY, K., IFTEKHAR, G., *et al.* (2004) Keratocyte loss in corneal infection through apoptosis: a histologic study of 59 cases. *BMC Ophthalmol*, 4, 16.

- VESALUOMA, M., PEREZ-SANTONJA, J., PETROLL, W. M., *et al.* (2000) Corneal stromal changes induced by myopic LASIK. *Invest Ophthalmol Vis Sci*, 41, 369-76.
- WANG, T. T., NESTEL, F. P., BOURDEAU, V., *et al.* (2004) Cutting edge: 1,25-dihydroxyvitamin D3 is a direct inducer of antimicrobial peptide gene expression. *J Immunol*, 173, 2909-12.
- WANG, X., ZHANG, Z., LOUBOUTIN, J. P., *et al.* (2003) Airway epithelia regulate expression of human beta-defensin 2 through Toll-like receptor 2. *FASEB J*, 17, 1727-9.
- WATT, K. & SWARBRICK, H. A. (2005) Microbial keratitis in overnight orthokeratology: review of the first 50 cases. *Eye Contact Lens*, 31, 201-8.
- WEGENER, A. & LASER-JUNGA, H. (2009) Photography of the anterior eye segment according to Scheimpflug's principle: options and limitations - a review. *Clin Experiment Ophthalmol*, 37, 144-54.
- WEST-MAYS, J. A. & DWIVEDI, D. J. (2006) The keratocyte: corneal stromal cell with variable repair phenotypes. *Int J Biochem Cell Biol*, 38, 1625-31.
- WHITCHER, J. P. (1990) Corneal ulceration. *Int Ophthalmol Clin*, 30, 30-2.
- WHITCHER, J. P., SRINIVASAN, M. & UPADHYAY, M. P. (2001) Corneal blindness: a global perspective. *Bull World Health Organ*, 79, 214-21.
- WIESNER, J. & VILCINSKAS, A. (2010) Antimicrobial peptides: the ancient arm of the human immune system. *Virulence*, 1, 440-64.
- WILLCOX, M. D. (2007) Pseudomonas aeruginosa infection and inflammation during contact lens wear: a review. *Optom Vis Sci*, 84, 273-8.
- WILLCOX, M. D. (2010) Review of resistance of ocular isolates of Pseudomonas aeruginosa and staphylococci from keratitis to ciprofloxacin, gentamicin and cephalosporins. *Clin Exp Optom*, 94, 161-8.
- WILLCOX, M. D. & HOLDEN, B. A. (2001) Contact lens related corneal infections. *Biosci Rep*, 21, 445-61.
- WINCHESTER, K., MATHERS, W. D. & SUTPHIN, J. E. (1997) Diagnosis of Aspergillus keratitis in vivo with confocal microscopy. *Cornea*, 16, 27-31.
- WONG, T., ORMONDE, S., GAMBLE, G., *et al.* (2003) Severe infective keratitis leading to hospital admission in New Zealand. *Br J Ophthalmol*, 87, 1103-8.
- YAMAGUCHI, Y., NAGASE, T., MAKITA, R., *et al.* (2002) Identification of multiple novel epididymis-specific beta-defensin isoforms in humans and mice. *J Immunol*, 169, 2516-23.

- YANG, K. S., LIN, H. C., MA, D. H., *et al.* (2006) Ulcerative keratitis caused by *Haemophilus influenzae*. *Cornea*, 25, 701-4.
- YANG, Z., CAO, Z. & PANJWANI, N. (1997) Pathogenesis of *Acanthamoeba* keratitis: carbohydrate-mediated host-parasite interactions. *Infect Immun*, 65, 439-45.
- YUAN, X., HUA, X. & WILHELMUS, K. R. (2010) The corneal expression of antimicrobial peptides during experimental fungal keratitis. *Curr Eye Res*, 35, 872-9.
- ZAIDMAN, G. W. (1992) *Propionibacterium acnes* keratitis. *Am J Ophthalmol*, 113, 596-8.
- ZHOU, L., HUANG, L. Q., BEUERMAN, R. W., *et al.* (2004) Proteomic analysis of human tears: defensin expression after ocular surface surgery. *J Proteome Res*, 3, 410-6.

