

**Evaluation of the Median Nerve within the
Wrist during Functional Hand Activity Using
Ultrasonography**

Alyson Langley BSc. MA.

**Thesis submitted to the University of Nottingham for the
degree of Doctor of Philosophy**

November 2010

Abstract

Over the last 20 years, an increasing number of research studies have shown that ultrasonography can provide a valid and accurate assessment of the median nerve and the pathological changes associated with median nerve disorders. More recently ultrasonographic technology has advanced and it now allows for dynamic imaging of the nerve during physical movement of the hand. However dynamic ultrasonographic imaging is still a relatively new application as is yet to be explored to its full potential in the study of median nerve dynamics and the associated pathological changes.

The primary aim of this research is to study median nerve activity during physical hand movement using ultrasonography with 8-16MHz linear array transducer. The objectives are to establish an ultrasonographic technique for the dynamic imaging of the median nerve, along with an analytical method that can quantify its changing size, shape and location during four hand movements. The data obtained from participants with normal median nerve function is compared to values from participants who are either moderately symptomatic or fully symptomatic of a median nerve disorder, to investigate whether the novel method and technique could distinguish between the groups.

Three studies were designed to investigate median nerve activity during physical movement using ultrasonography. The aim of the first study was to investigate if the novel quantification method and ultrasonographic technique could measure the changing parameters of the median nerve between the start and end positions of a finger grip, power grip, pinch grip and thumb opposition movement, in non-symptomatic participants who have normal median nerve function.

The second study investigated whether the novel quantification method and ultrasonographic technique could distinguish between the non-symptomatic participants and participants who are either moderately symptomatic or fully symptomatic of a median nerve disorder, during each movement. The third study examined the change in size, shape and location of the median nerve at five intervals during the four movements and compared the data obtained from the non-symptomatic group with the values obtained from the moderate and fully symptomatic groups.

The findings from the studies show that the dynamic ultrasonographic technique can be used to image the median nerve during physical activity of the hand and that the novel quantification method can be used to measure the change in the parameters of the median nerve during physical hand activity and distinguish significant differences between the non-symptomatic median nerve and those symptomatic of an median nerve disorder.

Acknowledgements

I feel exceptionally privileged to have been a PhD student at the University of Nottingham and I would like to thank all those that have made it possible.

Thanks to my supervisors Dr Christine Haslegrave and Dr Donal McNally for their guidance and support throughout the study.

Thank you to all in the Human Factors Research Group for the information and the laughter shared around the coffee table. Special thanks to Paula Waddingham, Anne Floyde, Kirstie Dane and Iman Dianat.

Thank you to all in the biomechanics group especially Mandy Roshier, Mark Parry and Gillian Campbell for their patience in training of the ultrasonographic technology and relevant software and for making it fun and interesting. I hope we keep in touch.

Thanks to Trudy Farrington-Derby for her expertise in physiotherapy and her contribution to my knowledge on the upper limb tension test.

Most of all thanks to my children Charlie and Ben who allowed me to 'go for it'.

Contents

Abstract.....	2
Acknowledgements.....	4
Table of Figures	9
Abbreviations.....	11
Glossary of terms	12
1. Introduction.....	16
1.1. Background	17
1.2. Definition of the Problem.....	19
1.3. Overview of Research Topic.....	21
1.4. Aims and Objectives	23
2. Literature Review.....	24
2.1. Movement of the Upper Limb.....	27
2.1.1. Terminology of position and movement.....	27
2.1.2. Structure and function of the hand and wrist.....	35
2.1.3. The peripheral nerves and movement	43
2.1.4. Range of Motion in the Hand and Wrist.....	49
2.1.5. Classification of Hand Actions	53
2.2. Work Related Upper Limb Disorders	56
2.2.1. Incidence and Prevalence of WRULDs	56
2.2.2. Risk Factors in the Development of WRULDs	60
2.2.3. Etiology and Pathology of WRULDs	65
2.2.4. Entrapment neuropathies and the median nerve	78
2.3. Assessment of Hand and Wrist Injury	84
2.3.1. Physical Examination.....	84
2.3.2. Electrodiagnostic Testing (EDT)	86
2.3.3. Computed Tomography (CT)	89
2.3.4. Magnetic Resonance Imaging (MRI).....	91
2.4. High Resolution Ultrasonographic Imaging	95
2.4.1. Ultrasonographic Equipment	97
2.4.2. Physics of Ultrasonography	99
2.4.3. Strengths and weaknesses of ultrasonographic imaging.....	104
2.2.4. Peripheral nerve ultrasonography	106
2.5. Studies on Ultrasonography and the Median Nerve.....	111
2.6. Overview of the Literature	121
3. Aims and Objectives	128
4. Development of the Methodology	134
4.1 The Ultrasound Equipment	136
4.2 Gaining Practical Experience	139
4.3 Defining Measuring Procedures and Data Analysis	140
4.3.1 The Measurements	140
4.3.2 On-line and off-line analytical software.....	142
4.4 Pilot Experiment.....	148
4.4.1 Scanning process.....	148
4.4.2 Results of the Pilot Experiment	151
4.5 Repeatability of Measurements.....	155
4.6 Discussion on the Measuring Procedures and Data Analysis for the Experimental Studies	157

5.	Experimental Studies	161
5.1	Experimental Procedures.....	163
5.1.1	Choice of Simple Hand Movements for Study	163
5.1.2	Choice of Body Posture for the Trials	166
5.1.3	Procedures in Running the Experiment	166
5.2	Participant Characteristics and Selection Criteria.....	169
5.2.1	Characteristics of Participants.....	169
5.2.2	Selection procedures for participants with/without symptoms of median nerve disorder.....	170
5.2.3	Sample Size and Recruitment	173
5.2.4	Details of Participants in the Pool.....	174
5.3	Study 1: Exploring the Normal Dynamics of the Median Nerve.....	177
5.3.1	Results of Study 1	178
5.3.2	Study 1: Discussion.....	183
5.3.3	Study 1: Conclusions	185
5.4	Study 2: Comparing Normal Nerve Dynamics with Participants Symptomatic of a Median Nerve Disorder	185
5.4.1	Study 2: Results	186
5.4.2	Study 2: Discussion.....	191
5.4.3	Discussion	202
5.4.4	Study 2: Conclusions	205
5.5	Quantifying the Changes in the Dynamics of the Median Nerve throughout the Hand Movements	206
5.5.1	Study 3: Results	207
5.5.2	Study 3: Discussion.....	228
5.5.3	Study 3: Conclusion	233
5.6	Conclusions of Experimental Chapter	233
6.	Discussion	234
6.1	Imaging technologies and the median nerve	236
6.2	Recommended Procedures	239
6.2.1	Recommended scanning technique and quantification method.....	240
6.2.2	Recommended measurements.....	241
6.2.3	The participants and selection process.....	243
6.2.4	Recommended position and movement.....	243
6.3	Summary of Experimental Studies.....	246
6.4	Key findings	248
6.4.1	Influence of hand movements on median nerve behaviour	248
6.4.2	Influence of the change in movemnt on median nerve behaviour	249
6.4.3	Influence of a disorder on median nerve behaviour.....	249
6.4.4	Proposed mechanism of median nerve behaviour	253
6.5	Limitations of Research	254
6.6	Recommendations for Future Research	256
7.	Conclusions.....	258
	Appendices.....	261
	Appendix A: Anatomy of the Upper Limb	262
	A.1 The Bones and Joints of the Hand and Wrist	262
	A.2 Muscles, Tendons and Ligaments	266
	A.3 Median Nerve.....	271
	Appendix B (i):Ethical Review Committee Form	276

Appendix B (ii):Investigation Protocol for the Ethical Review Committee.....	279
Appendix C:Participant Consent Form.....	282
Appendix D:Participant Questionnaire.....	284
Appendix E (i):Individual values from non-symptomatic participants during the finger grip movement.....	286
Appendix E (ii):Individual values from non-symptomatic participants during the power grip movement.....	287
Appendix E (iii): Individual values from non-symptomatic participants during the pinch grip movement.....	288
Appendix E (iv): Individual values from non-symptomatic participants during the thumb opposition movement.....	289
Appendix F (i): Individual values from moderate and symptomatic participants during the finger grip movement.....	290
Appendix F (ii): Individual values from moderate and symptomatic participants during the power grip movement.....	291
Appendix F (iii): Individual values from moderate and symptomatic participants during the pinch grip movement.....	292
Appendix F (iv): Individual values from moderate and symptomatic participants during the thumb opposition movement.....	293
Appendix G (i): The change in the individual values for cross sectional area during the finger grip movement at 5 points.....	294
Appendix G (ii): The change in the individual values for flattening ratio during the finger grip movement at 5 points.....	295
Appendix G (iii): The change in the individual values for X co-ordinate during the finger grip movement at 5 points.....	296
Appendix G (iv): The change in the individual values for Y co-ordinate during the finger grip movement at 5 points.....	297
Appendix H (i): The change in the individual values for cross sectional area during the power grip movement at 5 points.....	298
Appendix H (ii):The change in the individual values for flattening ratio during the power grip movement at 5 points.....	299
Appendix H (iii): The change in the individual values for X co-ordinate during the power grip movement at 5 points.....	300
Appendix H (iv): The change in the individual values for Y co-ordinate during the power grip movement at 5 points.....	301
Appendix I (i): The change in the individual values for cross sectional area during the pinch grip movement at 5 points.....	302
Appendix I (ii): The change in the individual values for flattening ratio during the pinch grip movement at 5 points.....	303
Appendix I (iii): The change in the individual values for X co-ordinate during the pinch grip movement at 5 points.....	304
Appendix I (iv): The change in the individual values for Y co-ordinate during the pinch grip movement at 5 points.....	305
Appendix J (i): The change in the individual values for cross sectional area during the thumb opposition movement at 5 points.....	306
Appendix J (ii): The change in the individual values for flattening ratio during the thumb opposition movement at 5 points.....	307
Appendix J (iii): The change in the individual values for X co-ordinate during the thumb opposition movement at 5 points.....	308

Appendix J (iv): The change in the individual values for Y co-ordinate during the thumb opposition movement at 5 points.....309
References.....310
Web Sites332

Table of Figures

Figure 1: The structure of the thesis	22
Figure 2-1 Planes cut through the body	28
Figure 2-2: Abduction and adduction of the arm.....	29
Figure 2-3: Proximal and distal points of the upper limb	30
Figure 2-4: Radial and ulnar side of the forearm.....	31
Figure 2-5: Dorsal and palmar side of the hand.....	32
Figure 2-6: Flexion and extension of the fingers	33
Figure 2-7: Ulnar and radial deviation of the wrist.....	33
Figure 2-8: Opposition and rotation of the thumb	34
Figure 2-9: Bones of the hand and fingers.....	35
Figure 2-10 illustrates the joints of the hand and fingers.....	35
Figure 2-11: The bones and joints of the wrist	37
Figure 2-12: Anatomical arches of the hand.....	38
Figure 2-13: Synovial joint of the finger	39
Figure 2-14: Joints of the wrist and hand.....	40
Figure 2-15: Nerves of the upper limb.....	47
Figure 2-16: The brachial plexus	48
Figure 2-17: Articulations of the wrist.....	51
Figure 2-18: Estimated values for the rate of work related musculoskeletal disorder per 100 people employed	58
Figure 2-20: The estimated prevalence of musculoskeletal disorders	59
Figure 2-21: Conceptual model for WRULDs.....	66
Figure 2-22: Anatomy of the wrist showing the flexor tendons involved in tendonitis	69
Figure 2-23: Tenosynovitis of the wrist.....	71
Figure 2-24: de Quervain syndrome	72
Figure 2-25: The area affected by lateral epicondylitis	73
Figure 2-26: Thoracic outlet – area of compression	77
Figure 2-28: Median nerve compression in CTS.....	81
Figure 2-29: Tinel’s test.....	85
Figure 2-30: Phalen's sign.....	85
Figure 2-31: NCS of the arm	87
Figure 2-32: Insertion of the needle EMG into a muscle.....	88
Figure 2-33: CT scan of the hand	90
Figure 2-34: MRI scan of the carpal tunnel	93
Figure 2-35: Foetal ultrasound scan.....	96
Figure 2-36: Linear array transducer probe	98
Figure 2--37: Reflection and refraction of an ultrasound wave	102
Figure 2-38: Scattering of ultrasound wave.....	104
Figure 2-39: Longitudinal sonogram of the radial nerve	107
Figure 2-40: Transverse sonogram of the median nerve	108
Figure 3-1: Overview of research programme.....	131
Figure 4-1: Overview of the development of the research	135
Figure 4-2: DIASUS ultrasound machine.....	137
Figure 4-3: The major and minor axis measured with the straight line tool.....	143
Figure 4-4: outline of the circumference of the median nerve.....	144
Figure 4-5: The ellipsoid shape tool overlaying the median nerve.....	145

Figure 4-6: The planes of the median nerve	147
Figure 4-7: Position of the participant during scanning.....	149
Figure 4-8: Position of the scanning area	150
Figure 4-9: Ultrasonographic image proximal to the carpal tunnel	152
Figure 4-10: Ultrasonographic image at the middle of the carpal tunnel	153
Figure 4-11: Ultrasonographic image distal to the carpal tunnel.....	154
Figure 5-1: Overview of the experimental studies.....	162
Figure 5-2: The hand movements	165
Figure 5-3: The mean changes in the median nerve parameters over each movement	180
Figure 3-4: Comparison between participant groups - change in the median nerve during the finger grip movement	194
Figure 5-5: Comparison between participant groups - Parameters of the median.....	197
nerve during the power grip movement	197
Figure 5-6: Comparison between participant groups - Parameters of the median nerve during the pinch grip movement	199
Figure 5-7: Comparison between participant groups - Parameters of the median nerve during the thumb opposition movement	202
Figure 5-8: Change in the cross-sectional area throughout the finger grip movement	208
Figure 5-9: Change in the flattening ratio throughout the finger grip	210
Figure 5-10: Change in the X co-ordinate throughout the finger grip.....	211
Figure 11: Change in the Y co-ordinate throughout the finger grip	212
Figure 5-12: Change in the cross-sectional area throughout the power grip	214
Figure 5-13: Change in the flattening ratio throughout the power grip	215
Figure 5-14: Change in the X co-ordinate throughout the power grip	216
Figure 5-15: Change in the Y co-ordinate throughout the power grip	218
Figure 5-16: Change in cross-sectional area throughout the pinch grip	219
Figure 5-17: Change in the flattening ratio during the pinch grip	220
Figure 5-18: Change in the X co-ordinate throughout the pinch grip.....	221
Figure 5-19: Change in the Y co-ordinate throughout the pinch grip.....	222
Figure 5-20: Change in the cross-sectional area throughout the thumb opposition ..	224
Figure 5-21: Change in flattening ration throughout the thumb opposition	225
Figure 5-22: Change in X co-ordinate during thumb opposition.....	226
Figure 5-23: Change in Y co-ordinate throughout the thumb opposition.....	227
Figure 5-24: The typical movement of the median nerve during hand movement a) non-symptomatic participant b) fully-symptomatic participant	231
Figure A1.1: The bones and joints of the wrist and hand	263
Figure A1.3: Detailed illustration of the joints and bones in the wrist	265
Figure A1.3: The carpal tunnel	266
Figure A2.1: Skeletal muscle showing its attachment by the tendon to the bone	267
Figure 2.2: Finger joint showing the attachment of the ligaments to the bone.....	271
Figure A3.1: Cross section of the median nerve showing its elementary structures ..	273
Figure A3.2: The peripheral nerves of the upper limb from the brachial plexus to the hand.....	274

Abbreviations

CMC	Carpometacarpal joint
CT	Computed tomography
CTS	Carpal tunnel syndrome
CuTS	Cubital tunnel syndrome
DIP	Distal interphalangeal joints
ECRB	Extensor carpi radialis brevis muscle
EDM	Extensor digiti minimi muscle
EDT	Electrodiagnostic testing
EMG	Electromyography
HSC	Health and Safety Commission
HSE	Health and Safety Executive
IP	Interphalangeal joint
MPC	Metacarpophalangeal joint
MRI	Magnetic resonance imaging
NCS	Nerve conduction studies
PIP	Proximal interphalangeal joint
ROM	Range of motion
WRULD	Work related upper limb disorder

Glossary of terms

Anterior: (Latin; *ante* English; *before*). The front of the body, synonymous with ventral.

Anteroposterior: Axis that connects the anterior and posterior points of the body.

Brachial plexus: Large and complex network of nerves that originate from the lower cervical and the first thoracic spinal cord segments (C5-C8 and T1) and supply nerves to the chest, shoulder, and arm.

Carpal tunnel: An anatomical tunnel at the wrist that allow nerves and tendons to enter the hand from the forearm

Contractile forces: Forces produced by a reduction in size or length of the muscle in response to stimulus

Cross-sectional: A plane made by cutting across something at right angles to its length

Deep: (Latin; *profundus* English; *due to depth*). When used anatomically the point furthest away from the surface of an individual.

Degrees of freedom: Independent components of motion that specify the orientation of the body or system.

Distal: (Latin; *distare* English; *to stand away from*). The point furthest away from the point of attachment of a limb to the body.

Dorsal: The back of the individual or a part of the body. Synonymous with posterior.

Dorsopalmar axis: An imaginary axis that connects the front and back of the hand.

Extension: The act of moving (extending) a limb away from the body.

Echogenic: Structures that reflect high-frequency sound waves produced by ultrasound techniques.

Echotexture: The appearance of an anatomical structure visualized using the echoes from ultrasound technology.

Fascicles: A bundle of nerve fibres.

Flexion: The act of bending a joint or limb towards the main trunk of the body.

Flexor retinaculum: A band of tendons that hold the contents of the carpal tunnel in place.

Frontal plane: An imaginary axis that is perpendicular to the ground and divides the body into front and back portions (separates anterior from posterior or ventral from dorsal).

Hyperechoic: Light areas surrounded by darker areas produced from an increasing amplitude of ultrasound waves returned from the structures being scanned.

Hypoechoic: Dark areas surrounded by light patches produced by tissue and structures that reflect relatively few ultrasound waves.

Inferior: Away from the head or the lower part of a structure.

Lateral: Further away from the midline.

Left lateral: Left hand side of an individual.

Medial: Situated in, or extending toward the middle.

Mediolateral axis: The axis that connects the left and right lateral points.

Opposition: A movement of the thumb where the pad of the thumb is placed on the pads of the fingers on the same hand.

Palmer: (Latin; *palma* English; *palm of the hand*) Directional term used to describe the anterior (palm) of the hand.

Peripheral: Structures that are at a distant from the body.

Peripheral nerves: Nerves that carry information to and from the central nervous system.

Posterior: (Latin; *post* English; *after*). The back of the body or hand. Synonymous with dorsal.

Prehension: The act of grasping and seizing.

Proximal: (Latin; *proximus* English; *nearest*). The nearest point to the body.

Radial: Structures nearer to the radius.

Radial-ulnar axis: Connection of the sides of the forearm between the radius and ulna bones radius.

Range of Motion: Distance and direction a joint can move to its full potential between the flexed position and the extended position of a particular [joint](#).

Reaction forces: Action of a force exerted in the opposite direction.

Right lateral: The right side of an individual.

Sagittal plane: A plane of direction that runs perpendicular to the ground and refers to the position of the spine which divides the body into left and right sides.

Superficial: (Latin; *superfacies* English; *at the surface of* or *face*). The outer surface of the individual.

Supine: Lying on the back facing upwards.

Synergistic Muscles: Muscles that have a similar and mutually co-operative function or action.

Thenar: The fleshy part of the hand at the base of the thumb.

Transverse plane: A plane of direction that runs parallel to the ground and divides the body into head and feet portions. Synonymous with axial or horizontal plane.

Ulnar: Relating to the long medial bone in the forearm.

Ultrasonography: Imaging technique of structures within the body by the recording of reflected echoes.

Ventral: The front of the individual. Synonymous with anterior.

Volar: Relating to the palms of the hand.

1. Introduction

Recent advances in the technology of high resolution ultrasonography now allows for real-time dynamic imaging of median nerve activity during physical movement of the hand. This includes the normal functioning of the median nerve and the pathological changes found in work-related upper limb disorder (WRULD). WRULD is a term used to describe a broad range of musculoskeletal injury that effect many people in the industrial world. The most common WRULD associated with a median nerve disorders is carpal tunnel syndrome (CTS) which occurs when the median nerve gets compressed at the wrist and ceases to function properly. This chapter aims to introduce the thesis as a whole by briefly describing the background information and research in this area, defining the research problem and stating the overall aims and objectives.

1.1. Background

WRULDs consist of a number of inflammatory and degenerate diseases and disorders whose pathology involve the soft tissue of the musculoskeletal system in the upper limb and can result in pain and impairment of the neck, shoulders, arms, wrist or hands. The most commonly reported WRULDs is median nerve disorder called carpal tunnel syndrome (CTS) and involves the compression of the median nerve within the carpal tunnel (an anatomical structure that allows for the passage of the soft tissue structures across the joints at the wrist).

Disorders of the upper limb are defined as work related when the workplace activities and conditions contribute to the development of a disorder without being the exclusive cause of the injury (World Health Organization, 1985). Work- related

activities cited as being contributory risk factors for the development of WRULDs are repetitive tasks, forceful exertions, vibrations, mechanical compression, or sustained or awkward positions (Hagberg, *et al* 1995; NIOSH, 1997; Malchaire, *et al* 1997; Punnett, Wegman, 2004).

High resolution ultrasonography is used as an imaging technique that can penetrate the body and measure the reflection of high-frequency sound waves (called ultrasound waves), to construct an image of internal structures (called a sonogram) and can provide high quality images of superficial structures such as the median nerve at the wrist. It is particularly useful for defining the boundaries of small superficial structures and can identify the pathological changes in the soft tissue associated with WRULDs including those found in median nerve disorders at the wrist.

In recent years, ultrasonographic technology has advanced and it now allows for the dynamic imaging of peripheral nerves and other soft tissue structures in real time, during physical movement of the body. This includes the visualising of the anatomical activity of the median nerve within the carpal tunnel during physical movement of the hand throughout physical movement, allowing the examiner to observe and record nerve activity as it happens or for future analysis.

Ultrasonography is non-invasive, having no known side effects rarely causing discomfort to the subject being scanned. In addition, the equipment is widely available and relatively inexpensive when compared to other technologies, such as computed tomography or magnetic resonance imaging.

1.2. Definition of the Problem

Work related upper limb disorders (WRULDs) are widespread in many industrialised countries and result in high individual, social and economic cost due to such expenses as work absence and compensation claims (Punnett, Wegman, 2004). In 2004, the Health and Safety Commission (HSC, 2003) in the UK, estimated that 2, 233, 000 people were suffering from an illness that was caused or made worse by their current or past work. However, the total expenditure for WRULDs is believed to be higher than that actually reported by medical experts and the legal system (Hagberg, *et al* 1995; Buckle, Devereux, 2002).

Studies have produced evidence that demonstrates the contributory relationship between work related activity and upper limb disorders. The work-related risk factors cited include rapid work pace, repetitive motion patterns, insufficient rest and physiological recovery time, forceful manual exertions, non-neutral body postures, vibration, and exposure to cold temperatures (Hagberg, *et al* 1995; NIOSH, 1997; Malchaire, *et al* 1997; Punnett, Wegman, 2004). However, the association between specific patterns of manual activity and WRULDs varies in different studies.

The biological mechanism of each type of WRULD is still not known but the greatest amount of information comes from investigations into a median nerve disorder called CTS. CTS concerns compression of the median nerve within the carpal tunnel (Tanaka, McGlothlin, 1993) and is characterized by pain and numbness in the distribution area of the median nerve (Yassi, 1997) which results in difficulties in

performing daily hand activities (Tanaka, McGlothlin, 1993). However, the full etiology and pathology of CTS and its relation to physical work-related movement and risk factors is still not completely understood.

Median nerve disorders including CTS have been studied for a number of years using high resolution ultrasonography. The first reports included anatomical information describing the anatomy of the carpal tunnel and the median nerve (Fornage 1988). Since then, it has been used in a number of studies to quantify certain parameters of the median nerve from static sonograms (individual images) while the participant remained motionless (Buchberger, *et al* 1992; Nakamichi, Tachibana, 2002; Leonard, *et al* 2003; Altinok, *et al* 2004; Kotevoglou, *et al* 2004; Yesildag, *et al* 2004). This technique was a common research element for comparing stationary parameters of the nerve between the normal functioning nerve and the symptomatic nerve for the diagnosis of CTS.

However, the differences in the methodological approach (such as the position of the participant), data collection (such as how the data was obtained) and analysis (such as what calculations were used to obtain the data) during each study produced varying values for the normal and the injured nerve. This inconsistency in data makes it difficult to compare values between individual studies and results in no standardized criteria for assessing a normal functioning nerve and those obtained from a nerve symptomatic of CTS using ultrasonography.

A very small number of studies have reported on median nerve movement within the wrist using the dynamic scanning processes during simple non-functional movements of the hand and wrist (Greening *et al* 2001; Erel *et al* 2003) but there appears to be no

published research that reports on median nerve behaviour during functional work-related hand activity.

The development of the dynamic imaging capabilities of ultrasonography for the purpose of studying median nerve activity during physical movement of the hand, along with the establishment of quantification method for collecting and analyzing the dynamic data could contribute to the understanding of normal median nerve activity during purposeful hand movements and the pathological differences seen in the symptomatic nerve.

1.3. Overview of Research Topic

This research was performed with the aim of establishing the dynamic capabilities of ultrasonography and a novel quantification method for the evaluation of the median nerve activity during physical hand movement. The goal was to establish an experimental approach that could obtain and analyze data obtained during median nerve activity that can distinguish between normal nerve function and that of the symptomatic nerve.

The research programme started with a literature review that established the background material on the associated subjects and current literature of studies into the use of ultrasonography in the assessment of the median nerve. Development techniques and procedures were established for imaging the median nerve during natural hand movements and analyzing the data, since this required extending the available knowledge and capability of ultrasound scanners for the monitoring of

dynamic activities. The development of a methodological protocol was undertaken involving a pilot experiment to fine tune the processes and to establish what was to be taken forward to be used in the main experimental studies. Following this, simple hand movements that could be monitored and easily co-ordinated were studied so that the data obtained from each individual could be compared across a number of subjects.

Figure 1 is diagrammatic flow chart showing the overall structure of the thesis.

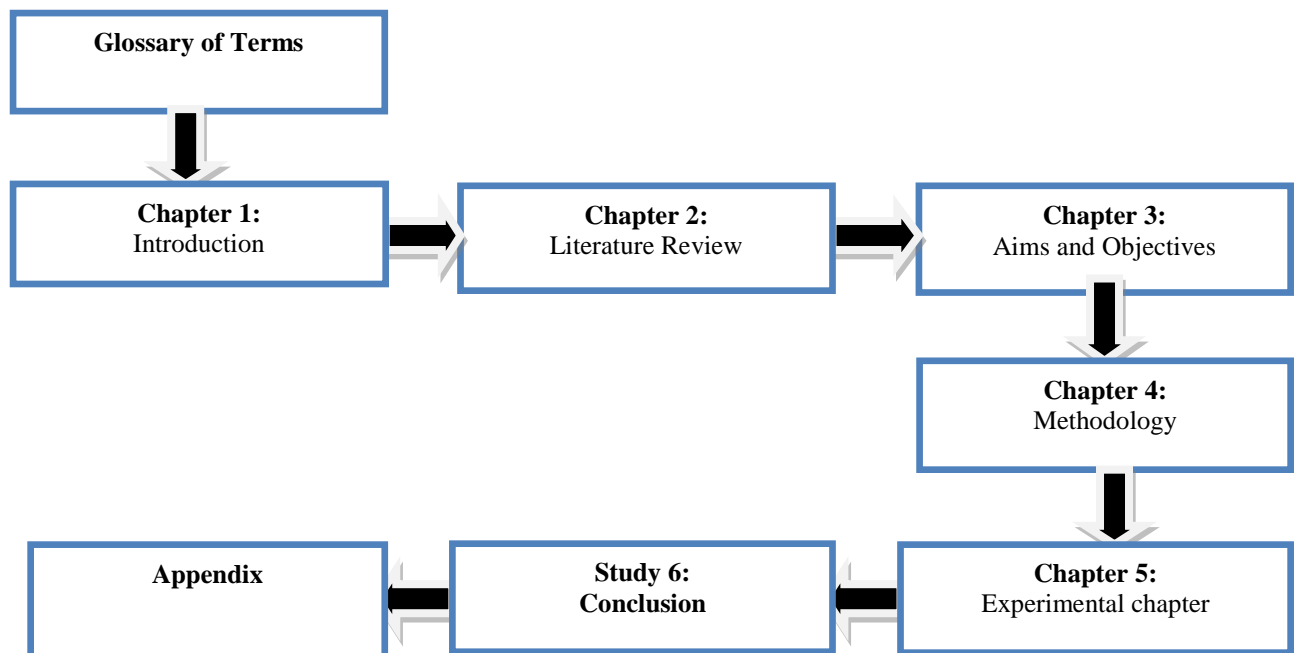


Figure 1: The structure of the thesis

1.4. Aims and Objectives

There has been very little research that has used the dynamic imaging capabilities of ultrasonography to study median nerve dynamics and its associated work-related pathology and to the knowledge of the author, there is no study that examines these issues throughout physical movement of the hand. Therefore, the primary aim of this study was to study the behaviour of the median nerve during simple but functional hand movement using ultrasonography. The objectives used to achieve the aims were to;

- Establish ultrasonographic techniques for the dynamic imaging of the median nerve during physical hand movement
- Establish an analytical method to quantify the changing parameters of the normal functioning median nerve during physical movement
- Use the technique to quantify the changing parameters of the symptomatic median nerve
- Use the quantification method and the ultrasonographic technique to distinguish between a normal functioning median nerve and that of a symptomatic nerve.

2. Literature Review

The upper limb is complex but versatile and includes the shoulder, upper arm, forearm, wrist and hand. The shoulder is the foundation support of the arm and along with the upper arm and forearm, allows the hand and wrist to be placed in the position needed to permit interaction of the individual with their environment (Kumar, 1999). The upper limb is capable of a wide variety of movement with the wrist making adjustments to the hand so that it can conform to the shape of an object or surface (Kumar, 1999). The complexity of movement that the upper limb can attain corresponds equally to the complexity seen at an anatomical level during movement, with nerves, tendons and ligaments sliding and changing position, muscles changing length, surfaces of bones at the joints rolling over each other, and fluid flow increasing in soft tissue (Tortora, Grabowski, 2003).

Most work activities involve employment of the upper limb and movement of the hands and wrist and this makes it susceptible to occupational hazards that pose a major risk of injury. Work related upper limb disorders (WRULDs) are a wide ranging group of inflammatory and degenerative diseases that can result in pain and functional impairment to the shoulder, arm, wrist and hand and can be roughly classified into pathological groups affecting tendons, muscle, joints, and nerves (Hagberg, *et al* 1995). The World Health Organization has defined upper limb disorders as work related when the work activities and conditions contribute to the development of the disorder without necessarily being the sole cause (World Health Organization, 1985).

Imaging of the median nerve and other soft tissue in the upper limb, along with some of the pathological changes found in WRULDs can now be achieved using high resolution ultrasonography. Ultrasonography uses sound waves with a frequency greater than the upper limits of human hearing (above 20KHz) and has been employed in many different fields to penetrate structures and measure the returning echoes. It is ideal for imaging superficial biological structures that are located near the surface of the skin including muscles, tendon and peripheral nerves such as the median nerve at the wrist.

Ultrasonographic evaluation of the median nerve and its associated WRULDs has most commonly investigated the nerve from individual static scans, involving no physical movement of the upper limb. However, recent advances in ultrasonographic technology now allow for continuous dynamic imaging of the nerve during physical movement. Nevertheless, this is still a relatively new application and as yet is still an unexplored tool for the study of the median nerve and WRULDs.

This chapter aims to review the literature covering the above topics and the previous research on the subject of ultrasonographic evaluation and the median nerve. In addition, some basic anatomy is described in *Appendix A*, including the anatomy of the wrist and hand, the muscles, tendons and ligaments and the median nerve, and this can be consulted for detailed information.

2.1. Movement of the Upper Limb

Humans are capable of highly skilled upper limb movement during which the muscles change length, surfaces of bones at the joints roll over each other, tendons, ligaments and nerves slide and change position and fluid flow increases in the soft tissue. The hand is the part of the upper limb that allows tactile contact between the individual and the environment and is capable of a wide variety of movement that can conform to the shape of an object. The wrist along with the fingers is the key feature in hand function, while the rest of the upper limb enables the hand to reach all parts of the body and a large area of the individual's immediate environment (Kumar, 1999).

2.1.1. Terminology of position and movement

The large variety of positions that an individual can attain can cause difficulties when attempting to apply terms to the location and the direction of movement of either the entire body or parts of it. Scientists and health care professionals use standard anatomical terminology to define the location and movements of any part or region of the human body (Tortora, Grabowski, 2003). Therefore it is important to define a description of the terms concerning standard anatomical position of the body and specifically of the upper limb.

In standard anatomical position, descriptions of any region or part of the body are based on the assumption that the subject is standing upright and facing forward, the feet flat on the floor, the arms at the side and the palms turned forward. When

describing a reclining body, the word supine is used to describe lying on the back, facing upward and the word prone is used for lying on the front, facing downward.

Humans are bilaterally symmetrical having an approximate mirror image on their left and right hand sides when divided down the middle, with distinct opposite points (e.g. head and feet). In humans, there are six opposite points giving three orthogonal axes that intersect the body at right angles (Marieb, 1995).

Descriptions of the movement of the body or parts of the body can be given by using planes which are imaginary surfaces that cut through the body at right angles to each other (Tortora, Grabowski, 2003) and are shown in Figure 2-1.

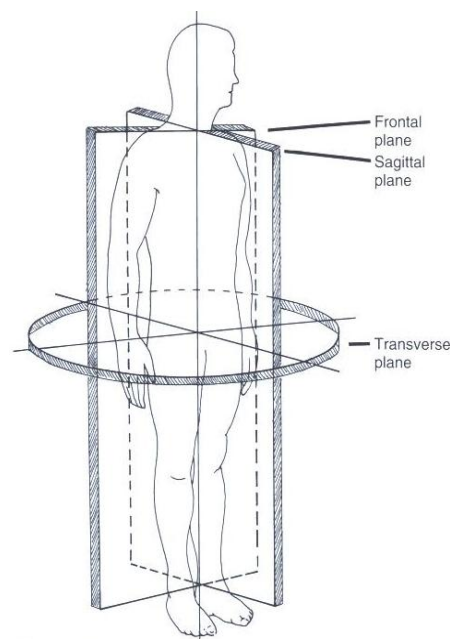


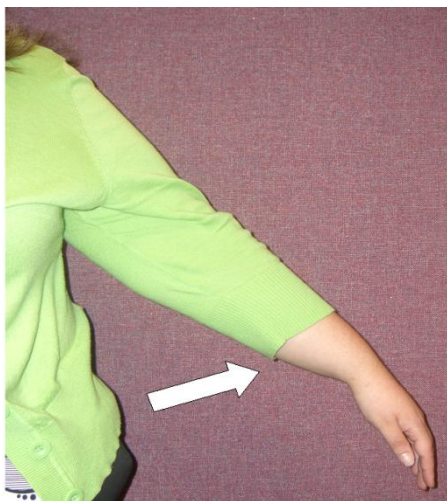
Figure 2-1: Planes cut through the body

The frontal plane (also known as the coronal plane) is perpendicular to the ground and divides the body into front and back portions (separating ventral from dorsal, anterior

from posterior). The sagittal plane is also perpendicular to the ground and passes through the spine to divide the body into left and right sides. The transverse plane (also known as the cross-sectional or horizontal plane) runs parallel to the ground and divides the body into head and feet portions. The midline of the body refers to an imaginary horizontal line that divides the body into right and left halves through all or a part of the body (Tortora, Grabowski, 2003).

Abduction is a term that refers to an anatomical direction and involves moving a body part away from the midline, for example moving your arm out and away from your body. Adduction is the total opposite of abduction and means to move toward the midline, for example bringing your arm back down to the side of the body or across the body's midline. Figure 2-2 illustrates abduction and adduction of the arm.

Abduction



Adduction

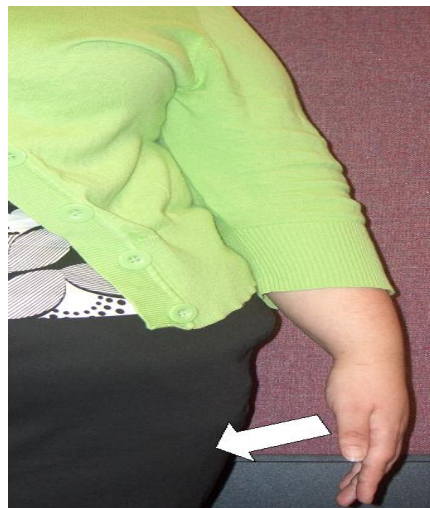

Figure 2-2: Abduction and adduction of the arm

The term superficial (Latin; *superficies* English; *at the surface of* or *face*) refers to the outer surface of the individual and for example can be used to describe structures within the body that are close to the surface of the skin. The word deep (Latin; *profundus* English; *due to depth*) refers to the point furthest away from the surface of an individual (Tortora, Grabowski, 2003).

There are a number of standard anatomical terms used to describe locations of structures and limbs in the human body. The term proximal (Latin; *proximus* English; *nearest*) describes a point nearest to the trunk of the body whereas the term distal (Latin; *distare* English; *to stand away from*) describes a point that is further away from the body (Tortora, Grabowski, 2003). Therefore, structures such as the wrist are proximal to the hand but distal to the elbow. However when referring to the nervous system peripheral describes nerves that are part of the peripheral nervous system at the distal points in the body, and are not part of the central nervous system (Marieb, 1995). Figure 2-3 illustrates proximal and distal points on the upper limb.

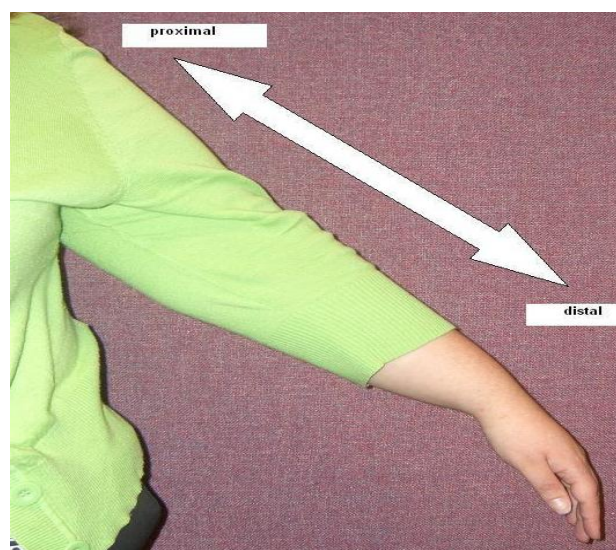


Figure 2-3: Proximal and distal points of the upper limb

The upper limbs move independently and change position with respect to the main body and therefore have specific positional and directional terms. The sides of the forearm are named after the two bones within the arm: the radius which is on the thumb side of the arm and ulna which is on the side of the little finger. Structures nearer to the radius are known as radial while those closer to the ulna bone are known as ulnar. Figure 2-4 shows the radial and ulnar sides of the forearm.

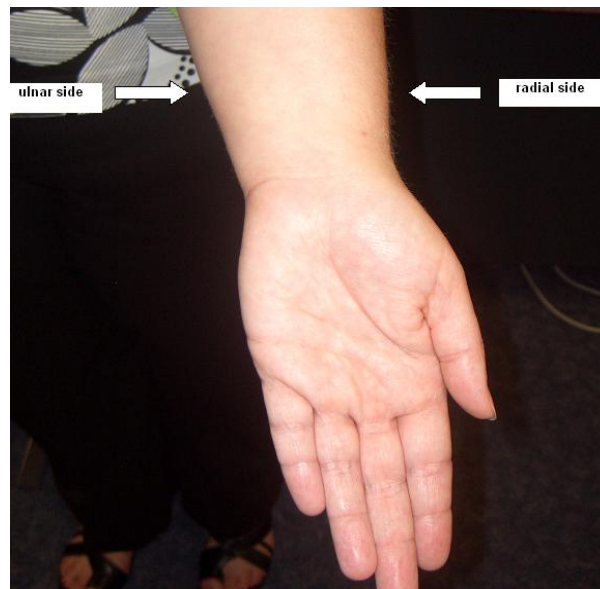
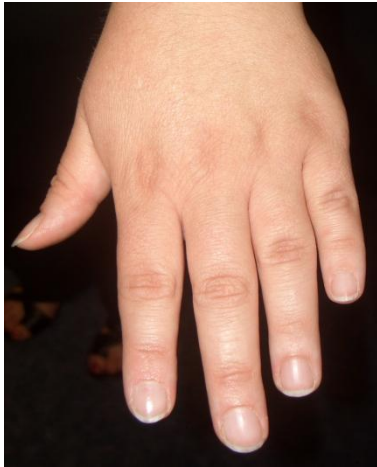

Figure 2-4: Radial and ulnar side of the forearm

The term palmar (Latin; *palma* English; *palm of the hand*) is used to describe the anterior (palm) of the hand and posterior can be used to describe the back of the hand but dorsal is the term usually used and therefore by connecting the front and back of the hand the dorsopalmar axis is formed (Tortora, Grabowski, 2003). Figure 2-5 shows the dorsal and palmar sides of the hand.

Dorsal side



Palmar side

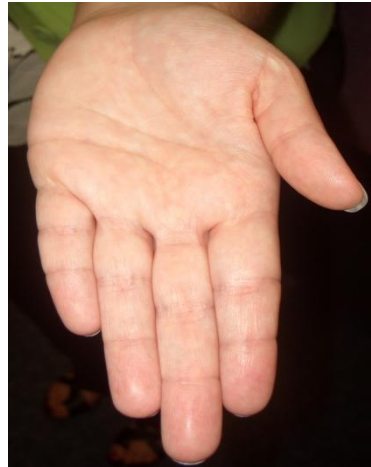
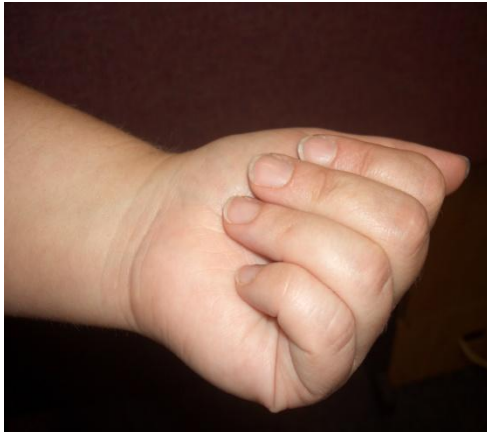
Figure 2-5: Dorsal and palmar side of the hand

Movements are sometimes classified by the direction in which the structure or limb is moved, such as the movements of flexion and extension of the fingers and radial and ulnar deviation of the wrist (Tortora, Grabowski, 2003). Flexion involves a bending movement that reduces the angle between the two parts of the body involved in the movement such as flexing the fingers into the hand to produce a fist. Extension movements are the opposite of flexion and involve movement that increases the angle between the body parts. Figure 2-6 illustrates flexion and extension of the fingers.

Flexion of the fingers



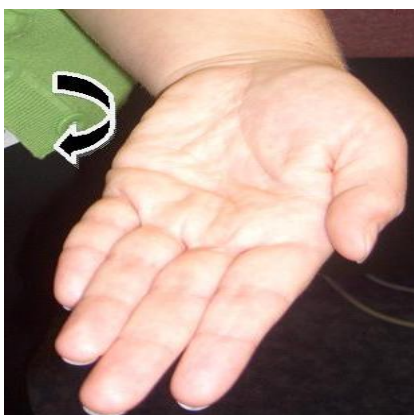
Extension of the fingers

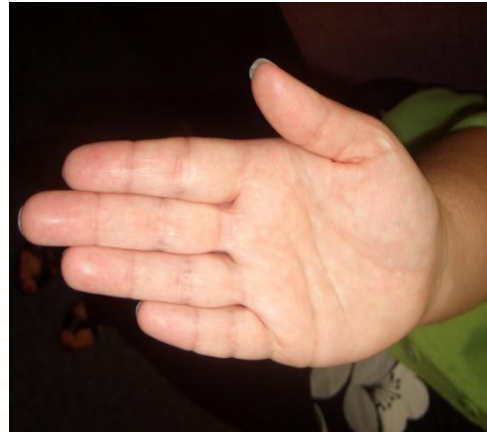

Figure 2-6: Flexion and extension of the fingers

At the wrist, ulnar deviation is also known as adduction of the wrist. It involves movement using the wrist that pulls the hand towards the ulnar side of the arm (the side of the small finger). Radial deviation is also known as abduction of the wrist and it is the opposite of ulnar deviation. It involves movement of the wrist that pulls the hand towards the radial side of the arm (the thumb side) (Marieb, 1995). Figure 2-7 illustrates radial and ulnar deviation of the wrist.

Ulnar deviation



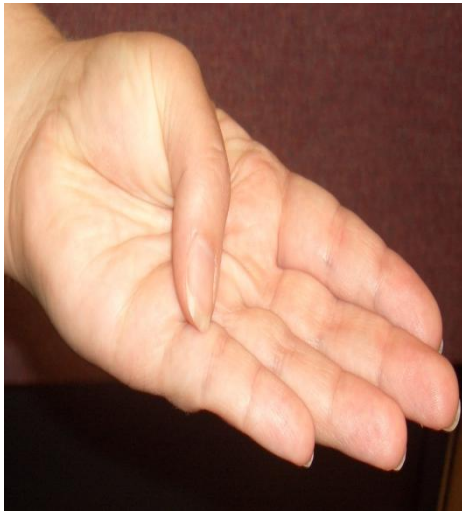
Radial deviation

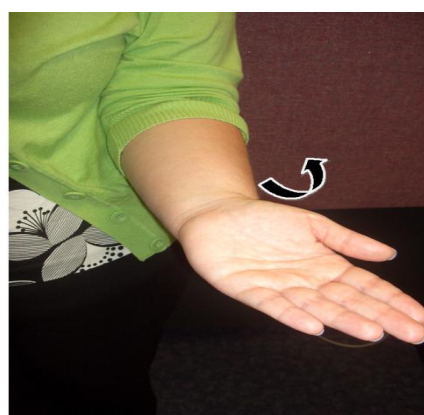

Figure 2-7: Ulnar and radial deviation of the wrist

Thumb opposition movements involve movement of the joint at the base of the thumb that brings the thumb across the palm to touch the tips of the fingers. Rotation of the thumb also occurs at the same joint and involves a circular movement of the thumb through its axis. Figure 2-8 illustrates opposition and rotation movements of the thumb.

Opposition



Rotation

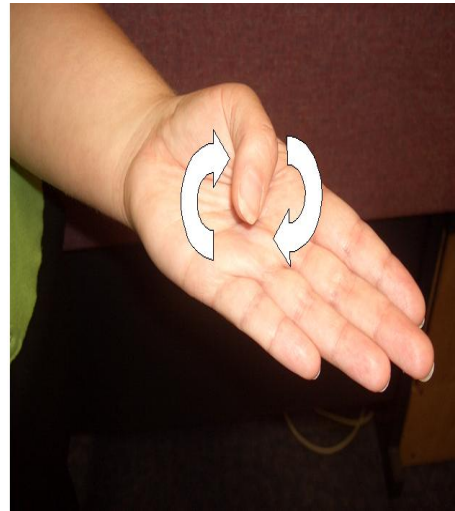


Figure 2-8: Opposition and rotation of the thumb

In anatomical terms intrinsic relates to a structure that is situated within or belongs solely to the organ or body part on which it acts. Extrinsic relates to not forming an essential or inherent element of an organ or body part or originating from the outside of anatomical structure. Concerning the wrist and hands the terms refer to the muscles, tendons or ligaments and relate to where they originate. For example extrinsic muscles of the hand originate outside the hand and intrinsic muscles originate inside the hand.

2.1.2. Structure and function of the hand and wrist

The hand and the five digits on each hand (one thumb and four fingers) consist of 5 metacarpal bones of the hand and 14 phalange bones of the fingers. Figure 2-9 shows the structure of the bones of the wrist, hand and fingers.

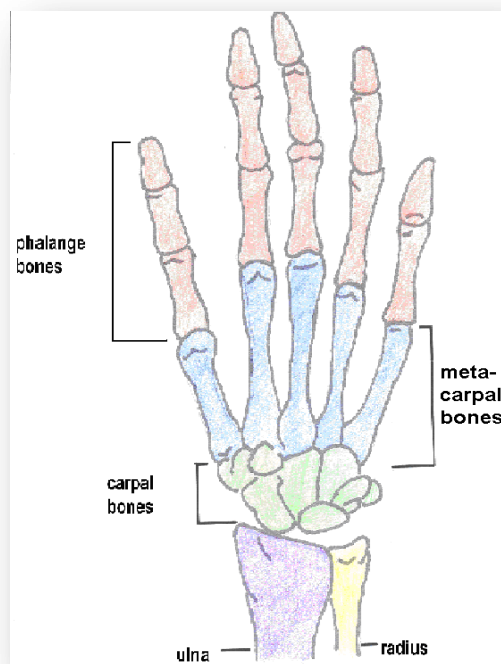


Figure 2-9: Bones of the hand and fingers. (Adapted from Tortora, Grabowski, 2003).

The joints of the fingers include the distal interphalangeal joints (DIP) which are between the phalange bones and furthest away from the main trunk of the body and the proximal interphalangeal joints (PIP) which are between the phalange bones and

nearest to the trunk of the body. The end of the proximal phalange bones articulate with the distal ends of the metacarpal bones to form the knuckles at the metacarpophalangeal joints (MP) and the proximal ends of the metacarpal bones articulate with the carpal bones of the wrist and form the carpometacarpal joints (CMC) (Tortora, Grabowski, 2003). Figure 2-10 illustrates the joints of the hand and fingers.

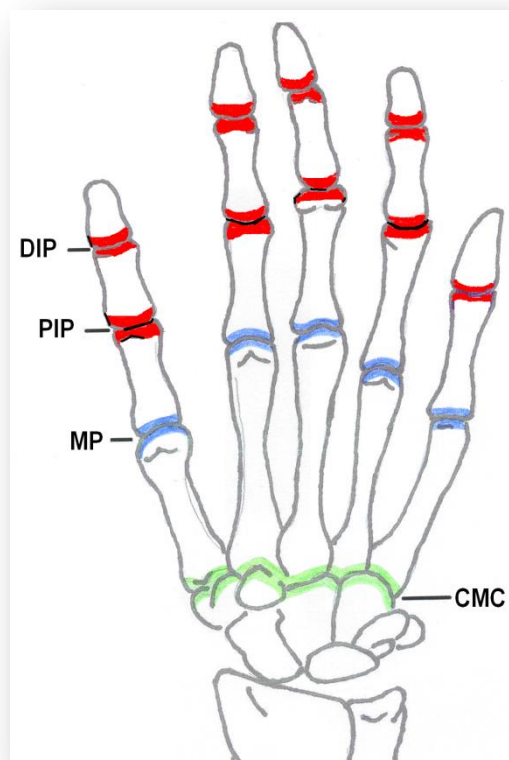


Figure 2-10: Joints of the hand (Adapted from Tortora, Grabowski, 2003)

The wrist is composed of 8 carpal bones that form a joint complex which includes the radiocarpal, midcarpal and intercarpal joints. The carpal bones are arranged in two rows at the distal end of the radius and ulna bones in the forearm and form a concave

transverse arch that shapes the floors and walls of an anatomical structure called the carpal tunnel (Nordin, Frankel, 2001). Figure 2-11 shows the bones and joints of the wrist.

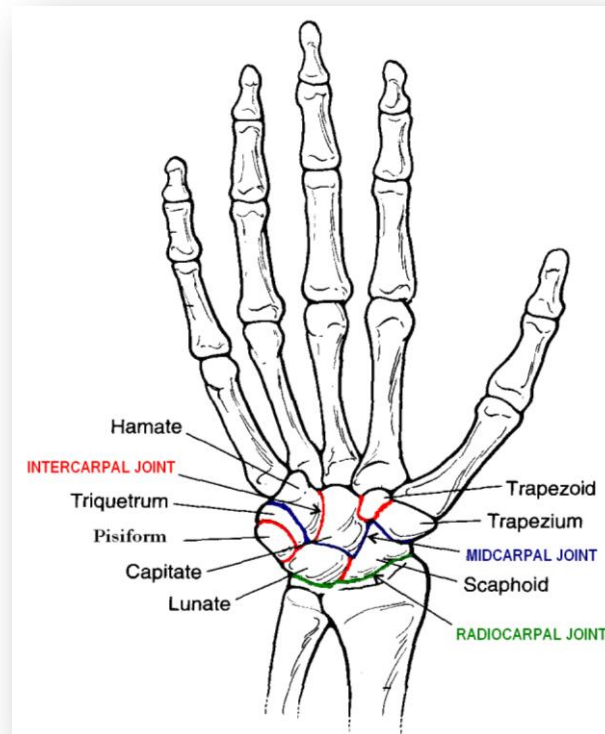


Figure 2-11: The bones and joints of the wrist. (Image of hand taken from Nordin, Frankel, 2001 with adaption to the text)

A more detailed description of the structure and anatomy of the hand and wrist are given in *Appendix A*, while the following text describes the aspects of structure and function of the wrist and hand that are specific to movement.

Movement of the body relies on an integrated functioning of bones, joints and skeletal muscles. Prehension of the hand is defined as a grasping movement and includes grips

such as the power grip and the precision grip (Nordin, Frankel, 2001). The ability of the hand to perform these movements comes from three anatomical arches which are held in place by the intrinsic muscles of the hand (Nordin, Frankel, 2001). The three anatomical arches of the hand are shown in Figure 2-12.

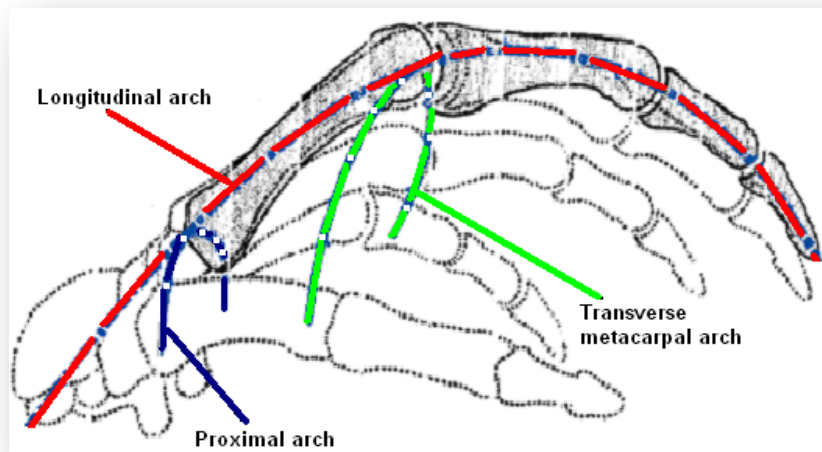


Figure 2-12: Anatomical arches of the hand. (adapted from <http://www2.siba.fi/harjoittelu/index>. Last viewed 15/06/10)

The proximal arch is formed by the distal part of the wrist and has its peak at the capitate bone and the longitudinal arch follows the underside of the fingers. However the most important for the versatility of the hand is the transverse metacarpal arch which is the most distal transverse arch. It follows the dorsal surface of the metacarpal heads and peaks at the third metacarpal head. The transverse metacarpal arch allows the finger tips to meet on flexion of the metacarpophalangeal and interphalangeal joints allowing for a precision grip to occur, and also permits each finger to contact the base of the thumb individually allowing for a very effective power grip (Nordin, Frankel, 2001).

The varying shapes and movement that the hand and wrist can attain are coordinated by the joints. There are three types of joints in the human body distinguished by their structural and functional differences: fibrous, cartilaginous and synovial joints.

Synovial joints are the most common and most moveable type of joint found in the wrist and hand (Tortora, Grabowski, 2003). The joint is surrounded by the synovial cavity which is composed of two layers, the outer fibrous capsule and the inner synovial membrane. The fibrous capsule consists of connective tissue that unites the articulating bones of the joint and prevents the bones from dislocating. The synovial membrane is composed of connective tissues with elastic fibers which secrete synovial fluid that lubricates the joint and reduces friction. The synovial cavity along with its connective tissues and accessory ligaments work together, to permit movement of the joint (Hamill, Knutzen, 1995). Figure 2-13 shows a synovial joint in the finger.

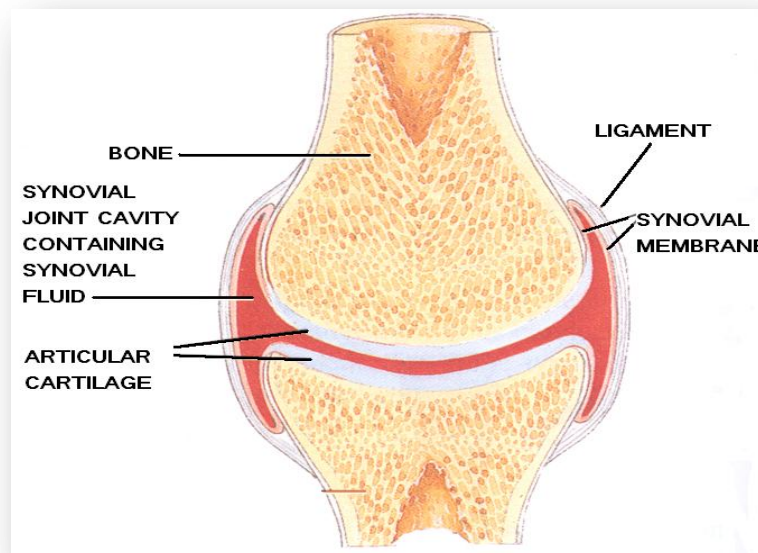


Figure 2-13: Synovial joint of the finger (taken from Tortora, Grabowski, 2003 with adaptation to the text)

The joints of the hand and wrist are the carpometacarpal (CMC), metacarpophalangeal (MCP) and the interphalangeal (IP) joints of the hand and the radiocarpal and midcarpal joints of the wrist and shown in Figure 2-14. A further description of these joints is given in *Appendix A*.

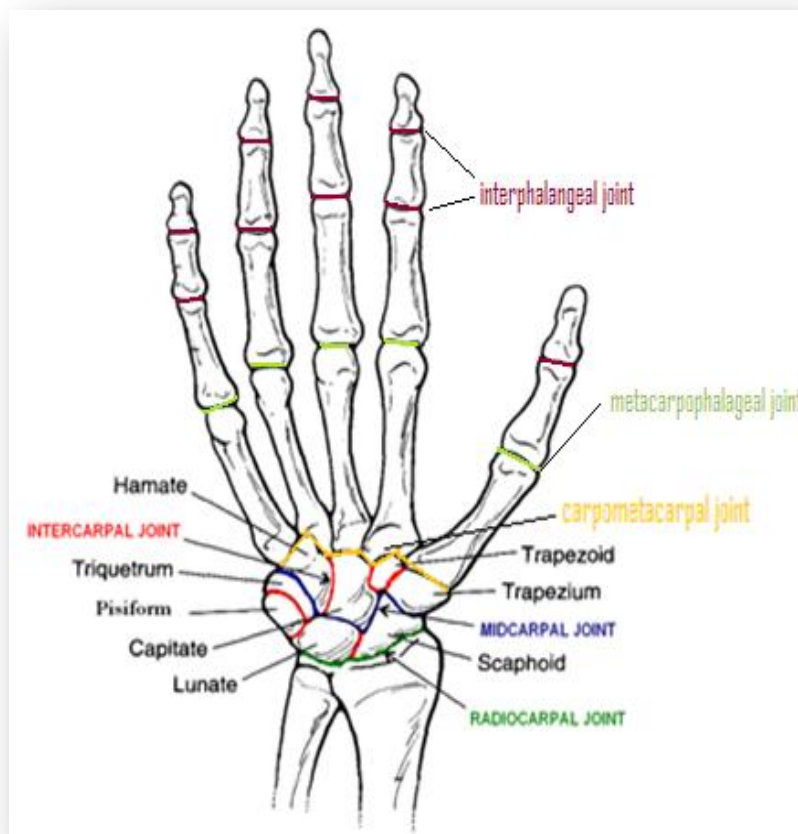


Figure 2-14: Joints of the wrist and hand. (Image of hand taken from Nordin, Frankel, 2001 with adaption to the text)

The function of the hand is extensively improved by the ability of the thumb to provide opposition and rotation movements through its carpometacarpal joint. Additionally, its capability to perform movements of radial and ulnar deviation along

with flexion and extension allows for the precision grip and increased power grip by its placement on the dorsal side of the 2nd and 3rd fingers after they have been flexed (Kumar, 1999).

Although the bones form the framework of the body and the joints and muscles provide leverage, movement cannot be attained without the alternating contraction and relaxation of the muscles by changing chemical energy into mechanical energy to generate force to produce movement, maintain body posture and generate heat (Kumar, 1999). A description of the form and function of the muscles along with a comprehensive account of the muscles that control the hand are given in *Appendix A*.

Wrist extension and flexion movements are derived from the extrinsic muscles that originate in the forearm and cross the wrist by way of sheathed tendons (Hazelton, *et al* 1975). The extrinsic muscles of the hand also originate from the forearm and allow flexion and extension movements in the fingers with wrist extension increasing the power of flexion in the finger. Extrinsic muscles provide both fine adjustment, and a stable working platform for the hand and fingers (Hazelton, *et al* 1975). Intrinsic muscles originate within the hand to create movement at the MCP and IP joints and function to modify the basic finger movements while providing stability within the hand (Hamill, Knutzen, 1995). It is the interaction of extrinsic and intrinsic muscles that produces an immediate and well co-ordinated response that results in a purposeful and useful hand function.

Tendons connect muscle to bone and allow stability and movement around the joints. They are made up of closely packed, parallel collagen fibres whose longitudinal

arrangement gives the tendon its tensile strength. Although, nineteen kinds of collagen have been identified but tendons are mainly made up of Type I collagen (Hulmes, 2002).

Hydroxyproline and proline are amino acids which are usually a major component of collagen and produce the triple helix structure which increase the stability of the fibre (Brinckmann, *et al* 2005). The flexibility of tendons is mainly due to the absence of hydroxyproline and proline in type I collagen fibres. This allows the collagen fibres within the tendon to form of other conformations such as bends or internal loops in the triple helix. (Silver, *et al* 2003).

Also important to the mechanical properties of the tendons are proteoglycans which are protein/polysaccharide complexes that form the extracellular matrix of the tendon (Puxkandl, *et al* 2002). Proteoglycans have viscous and elastic properties and are very hydrophilic (they can absorb a large amount of water) and therefore have a high swelling ratio allowing them to resist compressive stress. In addition, they are non-covalently bound to the fibrils, so they can reversibly associate-to and disassociate-from the fibres which allows the fibre to elongate and decrease in diameter under tension. (Cribb, Scott, 1995).

For prehension of the hand to occur, there must be stability of the longitudinal arches, movement of the joints and synergy between the contraction and relaxation movements of the extrinsic and intrinsic muscles and their accessory tendons and ligaments.

2.1.3. The peripheral nerves and movement

Along with all the complex mechanical activities involved in movement, adequate sensory input by the nerves must be maintained to all points of the upper limb (Kumar, 1999). The hands must perform the activities of daily life, along with the ability to differentiate between most environmental surfaces and temperatures instantaneously, allowing for immediate motor response to the sensations being felt.

Skeletal muscles are well supplied with nerves. Some nerve endings are responsive to the degree of movement and stretch at a joint while others convey information on pain. All information from the nerves is relayed to the brain via the spinal cord which may respond by sending signals to the muscles via different nerves to adjust body movement (Tortora, Grabowski, 2003).

As an individual assumes a posture or movement, the structural and biomechanical properties of peripheral nerves in the upper limb including the median nerve are modified as the nerve responds to the physical stresses placed upon it (Dilley, *et al* 2003). The peripheral nerves employ axons to conduct impulses that facilitate the bodies interactions with the world and tolerate and adapt to the everyday movements and postures (Topp, Boyd, 2006). Axons are the lengthy extensions of cell bodies and are insulated from each other, bundled together, and protected by layers of connective tissue known as the endoneurium, the perineurium, and the epineurium. Figure 1 illustrates the components of a peripheral nerve.

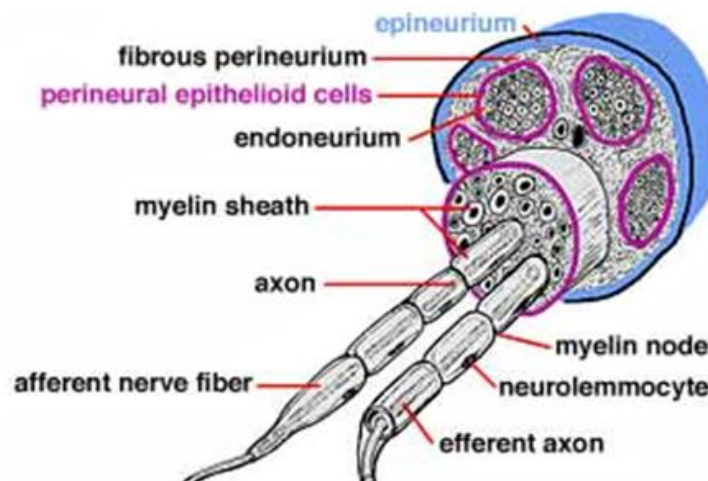


Figure 2-15: The components of a peripheral nerve. (www.vanat.cvm.umn.edu. Last imaged 01-10-10).

The endoneurium is the layer where the myelin of each myelinated axon is formed from the plasma membrane of a Schwann cell, with a single Schwann cell enveloping a myelinated axon to form an internode. The points of separation between myelinating Schwann cells are called nodes of Ranvier. Unmyelinated axons do not have a Schwann cell plasma membrane. The myelinated axon or group of unmyelinated axons is surrounded by type IV collagen (Thomas, 1963), which is similar to the collagen found in tendons and discussed in the previous sub-section.

A number of axons are grouped into nerve fascicles in the perineurium. These layers of type I and type II collagen fibres (and also include fibroblasts, a few mast cells and macrophages, and endoneurial fluid) and perineurial cells provide mechanical strength, resulting in the perineurium being the primary load-bearing portion of the nerve (Rydevik, *et al* 1990). Nerve fascicles are held together and surrounded by a connective tissue layer, termed the epineurium. The epineurial layer includes bundles of type I and type III collagen fibrils and elastic fibres (as well as fibroblasts, mast

cells, and fat cells) (Rydevik, *et al* 1990). The epineurium is loosely attached to the perineurium which allows for sliding of one fascicle independently of an adjacent fascicle (Millesi, *et al* 1995). The outermost tissue of the epineurium is attached to the surrounding connective tissue, which contains a significant amount of adipose tissue to protect the nerve at sites of recurring compression and facilitate the transverse and longitudinal sliding of the nerve (Millesi, *et al* 1995).

Under normal physiological conditions imposed by posture and movement, nerves are exposed to various mechanical stresses such as tensile or compressive stress (Driscoll, *et al* 2002).

Tensile stress on a nerve occurs during movement of a joint, with the nerve accommodating the stress by both elongating and sliding (Millesi, *et al* 1995). The displacement or sliding of a nerve relative to the surrounding structures is called excursion with the direction and magnitude of nerve excursion is dependent on the anatomical position between the nerve and the axis of rotation in the moving joint (Erel, *et al* 2003). During limb movement, excursion of the nerve occurs first in the nerve segment immediately adjacent to the moving joint and develops progressively in a more distal direction (Dilley *et al* 2003).

When a load is first applied, the nerve lengthens relative to the applied load and results in straightening of the connective tissue and axons in the endoneurial compartment. This causes a reduction in the cross-sectional area, a property termed transverse contraction (Millesi, *et al* 1995). Increased pressure in the endoneurial compartment contributes significantly to the biomechanical properties of a nerve by

resisting the transverse contraction (Millesi, *et al* 1995). When the tensile stress is removed, it is likely that a combination of elasticity of the connective tissues and pressure within the neural core will allow recoiling of the nerve to the original cross-sectional area and length (Millesi, *et al* 1995).

In addition to tensile stress, nerves are exposed statically and dynamically to compressive stresses. Nerves may be compressed externally by approximation to adjacent tissues, such as muscle, tendon, or bone, or by pressure increases in the extraneural environment. Compression of a nerve segment causes displacement of its internal contents in transverse and longitudinal directions (Millesi, *et al* 1995).

Low compressive stress for a short duration may result in reversible physiological and minor structural changes, however low compressive stress applied over a long period of time may cause significant structural changes in the nerve due to impairment of blood flow and ischemia. High compressive stress may result in structural alterations in myelin sheaths and disruption of axons (Millesi, *et al* 1995).

Common functional positions may result in compression pressures that approach or exceed the 20 to 30 mm Hg demonstrated to impair nerve blood flow (Rydevik, *et al* 1981). Carpal tunnel pressure in subjects who have normal median nerve function measured at 3 to 5 mm Hg with the wrist in a neutral position (Rojviroj, *et al* 1990). Placing the hand on a computer mouse was shown to increase the tunnel pressure from the resting 5 mm Hg to 16 to 21 mm Hg, (Rojviroj, *et al* 1990) and actively using the mouse to point and click increased the tunnel pressure to between 28 and 33 mm Hg, a pressure high enough to reduce nerve blood flow (Rojviroj, *et al* 1990).

In addition, carpal tunnel pressure was shown to increase to 63 mm Hg with 40 degrees of wrist extension and 0 degrees of metacarpophalangeal flexion,⁸⁰ and the anatomy of adjacent structures is thought to play a large role in these increases in carpal tunnel pressure (Rojviroj, *et al* 1990).

The wrist and hand are innervated for motor and sensory function by three peripheral nerves; the radial, ulnar and median nerve which are illustrated in Figure 2-16. The radial nerve innervates muscles that facilitate extensions of the wrist and fingers, and the ulnar nerve innervates the muscles that power grip actions of the hand (Omer, *et al* 1998). The median nerve is the only one of the three nerves that travels through the carpal tunnel and is critical for fine motor hand function concerning both motor and sensory supply (Omer, *et al* 1998).

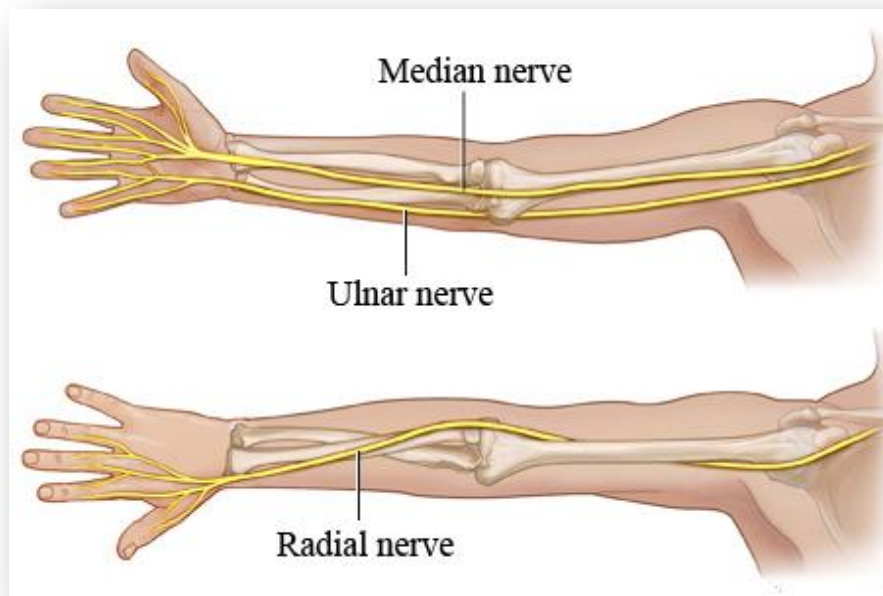


Figure 2-16: Nerves of the upper limb (www.health.com: Last viewed 04/05/10)

All the nerves in the upper arm originate from the brachial plexus. The brachial plexus is an arrangement of nerve fibers, running from the spine, through the neck and into the arm and is responsible for most of the skin surface and muscular innervations of the upper limb. The median nerve is formed by the lateral and medial cords of the brachial plexus and also carries fibres originating from the 6th, 7th and 8th cervical and the 1st thoracic spinal segments. The origins of the three nerves of the upper limb from the brachial plexus are illustrated in Figure 2-17.

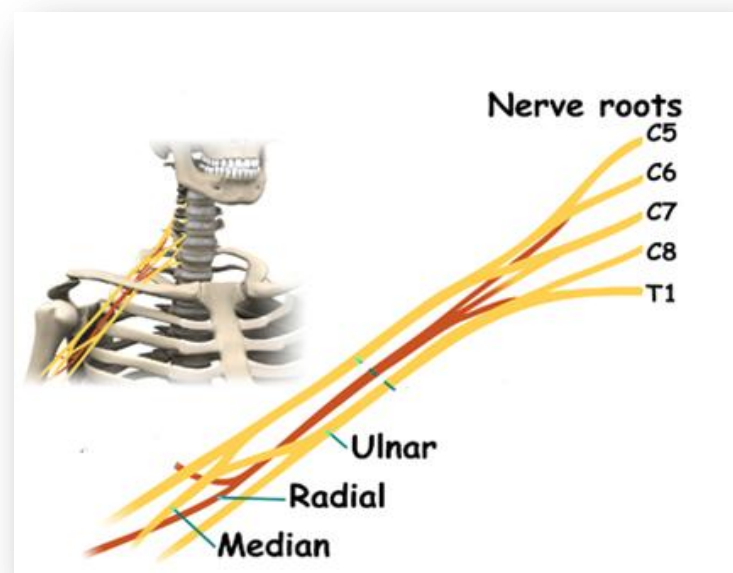


Figure 2-17: The brachial plexus (www.eorthopod.com/content/quadrilateral-space.

Last viewed 04/05/10)

The median nerve carries both motor and sensory fibres. The motor fibres supply most of the muscles on the front of the forearm along with four small muscles in the hand. The sensory function of the median nerve includes the palmar aspect of the

thumb, the index and middle finger and one half of the ring finger (Omer, *et al* 1998). *Appendix A* details median nerve innervation in the hand and arm.

During movement, the peripheral nerves of the upper limb not only have to conduct sensory and mechanical information to and from the central nervous system but also have to adapt mechanically. This adaptation of the median nerve has been reported as increasing in length by as much as 20% between movements (Butler, 1991).

2.1.4. Range of Motion in the Hand and Wrist

Range of motion (ROM) is a measurement of the achievable distance between the flexed position and the extended position of a particular joint. It is usually expressed in degrees relating to the maximum angle that the joint can attain and is measured with a goniometer (i.e., an instrument that measures angles from axis of the joint). Each joint has a normal ROM determined by the architecture of the bones and the soft tissue that keep the joint together and is measured in degrees of a circle through which the joint can be moved (Tortora, Grabowski, 2003).

Aspects that affect the ROM include;

- Structure and shape of the articulating bones which determines how closely they fit together
- Strength and tension of the joint ligaments which allow movement of the articulating bones while restricting the ROM


- Arrangement and tension of the muscles which support the ligament in restricting joint movement
- Resistance by other body parts where one surface comes into contact with another and limits movement
- Wrist/forearm postures (the largest effects are those of wrist flexion/extension on radial deviation ROM (Tortora, Grabowski, 2003).

Wrist ROM


Figure 2-18 shows the articulations of the wrist joint complex allowing movement in flexion-extension in a sagittal plane and radial-ulnar deviation in a frontal plane.

Approximately 60% of flexion occurs at the midcarpal joint and 40% in the radiocarpal joint, while 67% of extension occurs at the radiocarpal joint and 33% at the midcarpal joint (Hamill, Knutzen, 1995). During both radial and ulnar deviation the distal row of carpal bones follows the metacarpal bones of the hand whereas the proximal row of carpal bones move in the direction opposite to hand movement (Hamill, Knutzen, 1995).

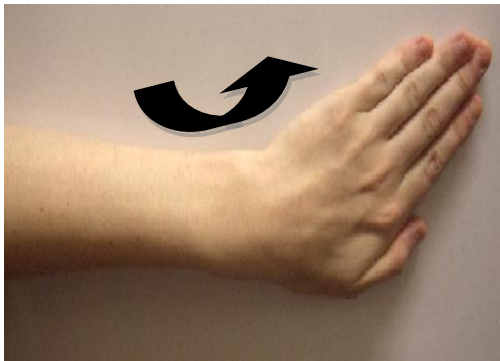
i) Wrist flexion in a frontal plane



ii) Wrist extension in a frontal plane



iii) Ulnar deviation in a sagittal plane



iv) Radial deviation in a sagittal plane

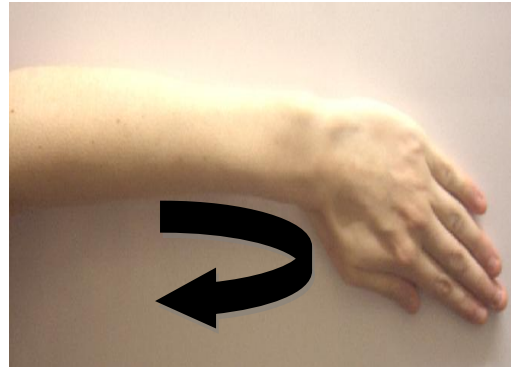


Figure 2-18: Articulations of the wrist.

The normal range of movement (ROM) for flexion of the wrist is approximately 65-80 degrees, but it is believed that only 10-15 degrees of flexion is needed for most of the daily activities involving the hand (Wells, 2004). Wrist extension has a ROM of 55-75 degrees with only approximately 35 degrees of extension needed for everyday life (Wells, 2004). The ROM for radial deviation is 15-20 degrees and for ulnar deviation is 30-40 degrees (Hamill, Knutzen, 1995).

ROMs of the Digits

The co-ordination of the fingers and the various shapes they can attain is achieved through the joints. The 2nd and 3rd metacarpals of the hand are connected to the trapezoid and capitate bones in the wrist and to each other to form an immobile unit. The 4th and 5th metacarpals articulate with the hamate bone enabling approximately 10°-15° of flexion/extension at the 4th carpometacarpal joint and 20°-30° at the 5th (Wells, 2004). These ROMs allow for the cupping of the hand and are essential for gripping actions (Hamill, Knutzen, 1995). The range of flexion at the metacarpophalangeal joint is approximately 90° but at the interphalangeal joints flexion of 110° is possible at the proximal interphalangeal joints and 90° at the distal interphalangeal joints (Wells, 2004).

At the wrist, the thumb metacarpal bone articulates with the trapezium to form a saddle joint which allows the thumb a wide range of movement (ROM). The opposition movement involves abduction of the thumb together with rotation at the carpometacarpal joint which moves the thumb towards the distal end of the little finger, with slight flexion of the interphalangeal joint allowing the thumb to touch the

tip of the little finger. The opposition movement is functionally the most important motion the thumb performs (Wells, 2004).

2.1.5. Classification of Hand Actions

The classification of the infinite variety of actions that the human hand is capable of performing has been attempted with the most basic categories distinguishing actions such as poking or pressing from gripping movements (Napier, 1956; Landsmeer, 1962; Long, *et al* 1970; Kamakura, *et al* 1980; Wells, 2004)

Napier (1956) first identified the distinction between prehensile (gripping) and non-prehensile actions which was added to by Landsmeer (1962) who provided further discussion on Napier's initial classification. Napier (1956) classified gripping actions into two main categories; the power grip where an object is held with the fingers and the thumb against the palm and the precision grip where an object is manipulated using the tips of the fingers and thumb. During the power grip the thumb is abducted at the carpometacarpal and metacarpophalangeal joints and the fingers are flexed, laterally rotated and ulnar deviated. During the precision grip the thumb is abducted and rotated and the fingers are abducted and flexed at the metacarpophalangeal joints (Napier, 1956). The pinch grip was defined by Long *et al* (1970) as compression force between the thumb and index finger or the thumb and the first two fingers.

Further studies by Ayoub, *et al* (1976) classified common task related prehensile grasps for ergonomics applications use, while others have provided common terms for

pinch grips for applications relevant to clinicians (Smith, 1985). Kroemer (1986) produced an alternative classification for grasps that was intended to be used along with Napier's and Landsmeer's classifications to describe practical handling patterns (Kroemer, 1986).

Kamakura *et al* (1980) reported on a study involving the classification of handling patterns based on contact with an object using the palm of the hand. They noted 14 patterns including five patterns for the power grip involving the palm and volar surface of the digits, four intermediate grip patterns involving the radial sides of the index and middle fingers, four prehension patterns with the object held between the fingers and the thenar eminence of the thumb and one prehension pattern without the involvement of the thumb (Kamakura, *et al* 1980).

The functional positions of the hand have been described for the power grip, the hook grip and the precision grip (Wells, 2004). The power grip involves grasping an object by flexing the metacarpophalangeal joint, using the intrinsic muscles in the palm and interphalangeal joint, using the long flexor muscles to the fingers, while extending the radiocarpal and midcarpal joints using the extensor muscles of the wrist. The hook grip involves flexion of the 2nd and 3rd interphalangeal joints using the long flexor muscles of the fingers as when holding a carrier bag. However the degree of flexion to the fingers can vary depending on the size of the object held. The precision grip requires fine control of the movement of the fingers and thumb such as holding a pencil or threading a needle. During this grip the wrist and the hands are held firm by the long flexor and extensor muscles with the intrinsic hand muscles controlling the fine movements of the digits (Wells, 2004).

The above categories are simple classifications for a huge range of prehensile hand postures with the reports only classifying hand forms at the final stage of the movement and not the motion of the hand and wrist during the activity.

At the anatomical level, the balanced synergistic actions (similar and mutually co-operative actions) of the digital flexors and extensor muscles of the hand, contract together to provide reaction forces (action of force exerted in the opposite direction) against the object that is held and add contractile forces (forces produced by a reduction in size or length of the muscle in response to stimulus) to the wrist, especially under load (Wells, 2004). The contribution of these muscles is proportional to the forces needed to perform the task, with nearly all the forearm muscles contracting to stabilize the wrist during extreme exertions. A firm grip requires maximum output and will use the extrinsic muscles whereas fine movements such as a pinch grip will use the intrinsic muscles to fine tune the movement (Wells, 2004).

When performing a task, the finger posture defines the type of grip used, with the number and strength of the individual digits affecting the magnitude of force generated on the object being held (Wells, 2004; Buckle, Devereux, 2002). However it is difficult to define working postures of the hand precisely due to the variation between tasks and individuals.

2.2. Work Related Upper Limb Disorders

Work-related upper limb disorder (WRULD) includes a large variety of inflammatory and degenerative conditions affecting the muscles, tendons, ligaments, joints, nerves or blood vessels in the neck, shoulder, arm, wrist or hands. These conditions are characterized by a range of symptoms (e.g. aches, pains, cramps, numbness, tingling, and heaviness) which can vary in location, intensity and nature (Buckle, Devereux, 2002).

The World Health Organisation define that disorders are work-related, when the work activities and work conditions significantly contribute to their development or exacerbation but are not necessarily the sole determinant of causation (World Health Organization, 1985). Some occupational diseases can be defined as having a direct cause-and-effect relationship between the occupational hazard and specific illnesses; e.g. asbestos and asbestosis, whereas WRULDs are multi-factorial and can result from a number of elements including the working environment (Hagberg, *et al* 1995).

2.2.1. Incidence and Prevalence of WRULDs

WRULDs are widespread in many industrialized countries with consequences to the individual and well as direct and indirect costs derived from disruption in productivity, worker training, health care, sick leave and sickness pensions (Punnett, Wegman, 2004). However it is believed that the incidence of WRULDs is higher than that actually reported by the medical experts and the legal system (Buckle, Devereux, 2002).

Establishing the true financial cost of WRULDs is difficult. The direct costs from compensation claims are thought to be only 30-50% of the total cost, with indirect expenses such as disruption in productivity, training, absence and worker replacement leading to a figure which could be more than double the amount paid out in compensation (Hagberg, *et al* 1995; Buckle, Devereux, 2002).

The Health and Safety Executive (HSE) commissioned a survey in 2003/04 called the Labour Force Survey (LFS), to investigate work-related illness in the UK. The results estimated that 2, 233, 000 people believed they were suffering from an work-related musculoskeletal disorder that was caused or made worse by their current or past work (5.2% of the working population). The survey showed that an estimated 448, 000 people in the UK, believed they were suffering from a work related upper limb disorder caused or made worse by their current or past employment. This is equivalent to 1.0% of the working population in 2003/04 with an estimated 4.7 million working days lost in that 12 month period (Jones, *et al* 2005). Figure 2-19 is a graph that illustrates the number of work related musculoskeletal disorder per 100 people employed.

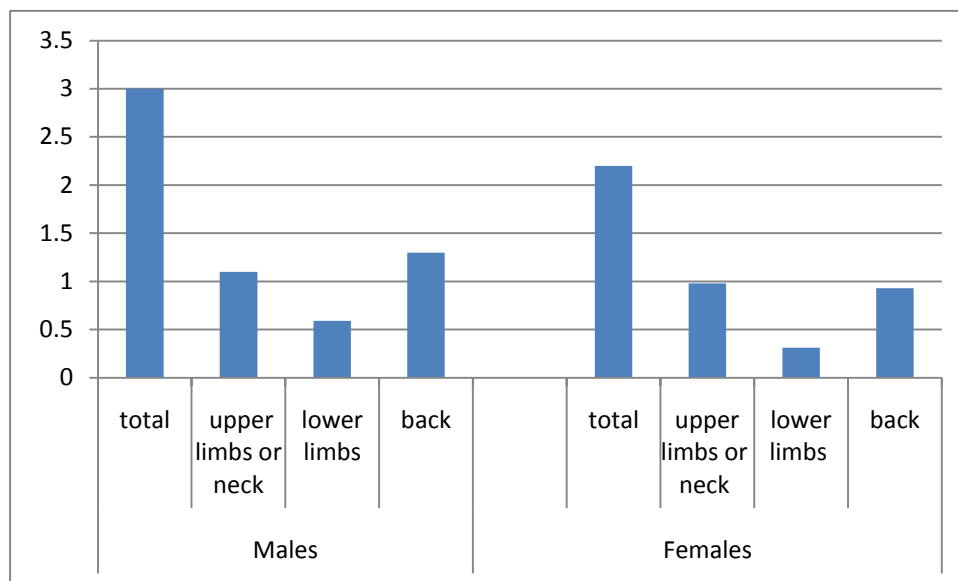


Figure 2-19: Estimated values for the rate of work related musculoskeletal disorder per 100 people employed (<http://osha.europa.eu/en/publications>. Last viewed 25/02/10)

There is substantial evidence that within the European Union (EU) member states work-related upper limb disorders are also a significant problem. However, the existence of different measures of assessment and insurance systems makes calculating the incidence and prevalence of WRULDs in the EU difficult (Buckle, Devereux, 2002).

“Turn your Back on Work-related Musculoskeletal Disorders” was the theme for the European Week for Safety and Health at Work being run by the 15 European Union Member States during October 2000 (<http://osha.europa.eu/en/publications>. Last viewed 25/02/10). The publication estimated that in the year 2000, 36% of workers believed they had a work-related musculoskeletal disorder that affected their neck,

shoulders or upper limbs. Figure 2-20 shows the prevalence of the different musculoskeletal disorders reported in the publication.

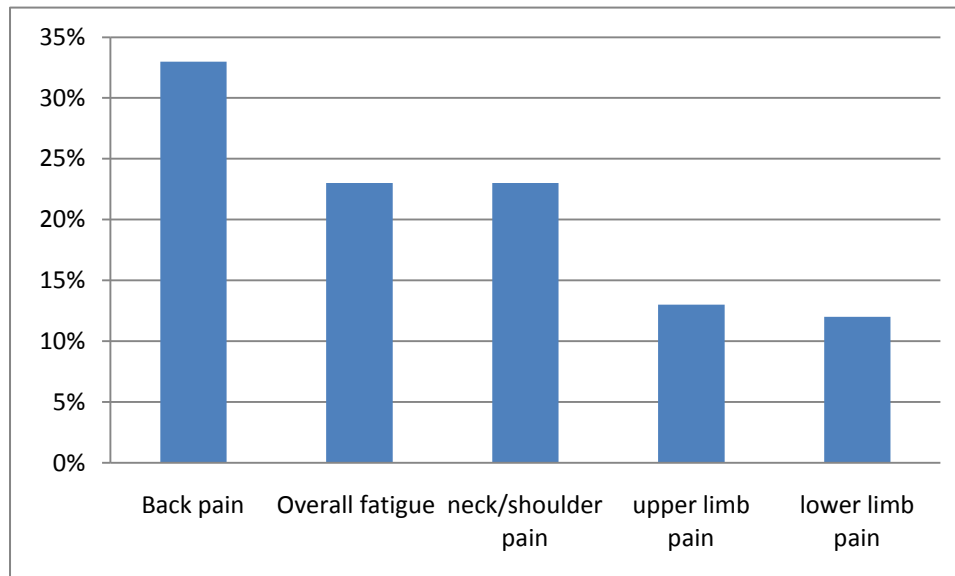


Figure 2-20: The estimated prevalence of musculoskeletal disorders.

(<http://osha.europa.eu/en/publications>. Last viewed 25/02/10)

In Italy claims for compensation for musculoskeletal injury caused at work had increased from 873 to 2000 between the years 1996 and 1999, whereas France showed an increase in claims from 2602 in 1992 to 5856 in 1996 (European Agency for Safety and Health at Work. 2000). Health care costs associated with WRULDs in the Nordic countries have been estimated from expenses such as medical care, sick leave and sickness pensions, as approximately 0.5%-2% of the gross national product (European Agency for Safety and Health at Work. 2000).

However, the lack of standardised assessment criteria for WRULDs makes comparison of data between member states difficult and little is known of the validity

of the reported data. Therefore the true extent of ill health and associated costs within the workplace across member states is difficult to assess (Buckle, Devereux, 2002).

In the United States the Annual Survey of Occupational Injuries and Illness conducted by the Bureau of Labor Statistics reported that 32% of all days away from work were as a result of overexertion or repetitive motion. From these 93,325 injuries were due to overexertion when pushing or pulling objects and 92,576 injuries were the result of repetitive motion including typing, keyboard use or repetitive use of hand tools or other objects (NIOSH, 1997). Recent studies in the US have given an incidence of CTS, one type of WRULD, as 280.6 for every 100,000 patients visiting general practitioners per year (Latinovic, *et al* 2006).

2.2.2. Risk Factors in the Development of WRULDs

Risk factors are occupational hazards that can lead to musculoskeletal injury including WRULDs and include rapid work pace, repetitive motion patterns, insufficient rest and physiological recovery time, forceful manual exertions, non-neutral body postures, vibration, stress and exposure to cold temperatures (Hagberg, *et al* 1995; NIOSH, 1997; Malchaire, *et al* 1997; Punnett, Wegman, 2004).

The literature suggests that upper limb injuries can arise from one or a combination of these risk factors, along with other undesirable features such as a poor psychosocial working environment (Hagberg, *et al* 1995).

Industrial occupations most affected by WRULDs include;

- Industrial assembly line workers in industries such as automotive, electronics and food processing
- Checkout workers in supermarkets
- Sewing machinists
- Musicians especially those who play string instruments
- Keyboard users especially data entry workers, copy typists, legal secretaries and journalists (Pheasant, Haslegrave, 2006).

Additionally, the multi-factorial nature of WRULDs can involve both occupational and non-occupational risk factors. The physical stresses of daily life and the playing of certain sports can present risk factors by putting strain on the musculoskeletal system, and systemic diseases such as rheumatoid arthritis and diabetes can also contribute to the development of injury. The risk of acquiring an upper limb disorder can also vary with such factors as age, gender, anthropometry, obesity and muscle strength (Punnett, Wegman, 2004).

Individual, psychological and physical factors related to WRULDs have been studied using epidemiological, clinical and biomechanical data and there is good evidence supporting the contribution of work related factors in the development of upper limb disorders (Hagberg, *et al* 1995). However, the evidence is stronger for some types of WRULDs and some risk factors than others, possibly because of the scarcity of well-designed longitudinal epidemiological studies.

The data from administrative systems (such as medical and insurance data) is a useful indication of occupations and practices associated with risk factors. However, this is often incomplete due to the under reporting of injuries because of situations such as job security or labor relations, or individual differences such as pain thresholds and psychological factors.

In spite of the wealth of information and opinions on WRULD's, the current medical understanding of exactly how this condition is caused, what the damage consists of and how to determine a prognosis, is still very limited. However, three groups of risk factors have been identified and are generally accepted as such.

These are:

- static muscle loading
- overuse and repetition
- stress

Static muscle loading describes muscular activity, which involves holding an object or on maintaining a certain posture or position with little or no movement (Carls, 1961).

When muscle contracts they compress the blood vessels which feed them. If the contraction is maintained above a certain level for any length of time, as during static activity, the blood supply is reduced and the accumulation of waste products such as carbon dioxide or lactic acid increases (Jonsson, 1988). The result is muscle fatigue experienced as an ache or discomfort.

As an example, computer work can cause static muscle loading in a variety of body areas unless regular breaks and changes in activity occur. When using the keyboard,

static muscle work is required to hold the arms and hands in place. Furthermore, if the back is not well supported, static muscle activity will occur there and in the muscles of the neck. Over time, this can lead to localised muscle tightness and postural imbalances, which can compromise the blood supply and the nerve function in the arms and hands (Jonsson, 1988).

Repetitive tasks, performed continuously without sufficient breaks or changes in activity can lead to demands and overuse of specific muscles and structures and carry the risk of straining tissues beyond their normal capacity, resulting in injury. Initially fatigue occurs but if demands increase it can result in aches, pains and injury (Barr, Barbe, 2002).

Stress and other psychological factors, can cause metabolic changes and increased muscle tension that sensitise the nervous system, leading to an increased perception of pain. Stress factors, whether related to work, family or any other area, can be important contributors to WRULD's (<http://osha.europa.eu>. Last viewed 25/02/10).

In addition, further risk factors associated with the development of WRULDs are:

- Work environment
- Individual variation
- Psychosocial factors and work organisation

With respect to work environment factors, the climate of the workplace can affect the body's muscles. Excessive heat increases overall fatigue and can result in the worker sweating making it hard to hold tools and requiring more force to be applied.

Excessive cold can make the hands feel numb, making it hard to grip and also requiring more force. Poor lighting can create glare or shadows that require the workers to move into awkward positions so that they can see what they are doing. High levels of noise may cause the body to become tense and a more rapid onset of fatigue (<http://osha.europa.eu>. Last viewed 25/02/10).

Concerning individual variations, the physical capacities of workers can be contributing risk factors as individuals vary in their body build, age, gender and the level of physical fitness. Previous injuries may also contribute by reducing the capability of the body, making it more vulnerable to impairment even after recovery of the old injury. Lack of experience or familiarity with the job can increase their exposure to overload and ill-fitting clothing or personal protective equipment can restrict postures and increase the applied force necessary to do the work (<http://osha.europa.eu>. Last viewed 25/02/10).

Psychosocial factors and work organisation can develop into risk factors and affect how workers feel about their job. Workers who perform monotonous jobs that involve only a few, similar tasks or that have incentives or quotas to encourage a faster work rate have a higher risk of developing WRULDs (<http://osha.europa.eu>. Last viewed 25/02/10). Excessive work demands, limited control by the worker over what they do, limited opportunities for social interaction, or little support from their managers, supervisors and other workers has been associated with an increased risk of developing WRULDs (<http://osha.europa.eu>. Last viewed 25/02/10).

It appears that the nature of industrial work often involve movements that can result in the risk of injury to the hands and wrist either by the exertion of force or from highly repetitive movements. This makes it susceptible to occupational hazards that pose a risk of WRULDs. However, the evidence is stronger for some types of WRULDs and some risk factors than other and the magnitude of the association between the physical activity within the workplace and WRULDs varies among studies, reflecting gaps in existing knowledge and differences in the interpretation of scientific data (Punnett, Wegman, 2004).

2.2.3. Etiology and Pathology of WRULDs

WRULD is a term under which a large variety of conditions and symptoms are classified. As already mentioned, the symptoms include pain, tingling, cramps, numbness, heaviness and tightness in the upper limb which vary in location, intensity and nature depending on the site and strength of the injury.

Knowledge and understanding of the biological mechanisms of each type of WRULDs varies greatly. For example, the information on CTS is extensive (Fornage, 1988. Buchberger, *et al* 1992; Nakamichi, Tachibana, 2002; Leonard, *et al* 2003; Altinok, *et al* 2004; Kotevoglul *et al* 2004; Yesildag, *et al* 2004) when compared to other disorders where more research is needed. However the general development of WRULDs has been described as an increasing cycle containing sets of cumulative exposure, dose, capacity and response variables, so that response at one level can act as dose at the next. This cycle starts when the physical activity generates strain forces

on soft tissue which result in a range of biomechanical and physiological responses by the body, such as impeded circulation or muscle fatigue. Figure 2-21 shows a conceptual model of upper limb musculoskeletal disorders and illustrates the pathways involved in the pathogenesis of these disorders.

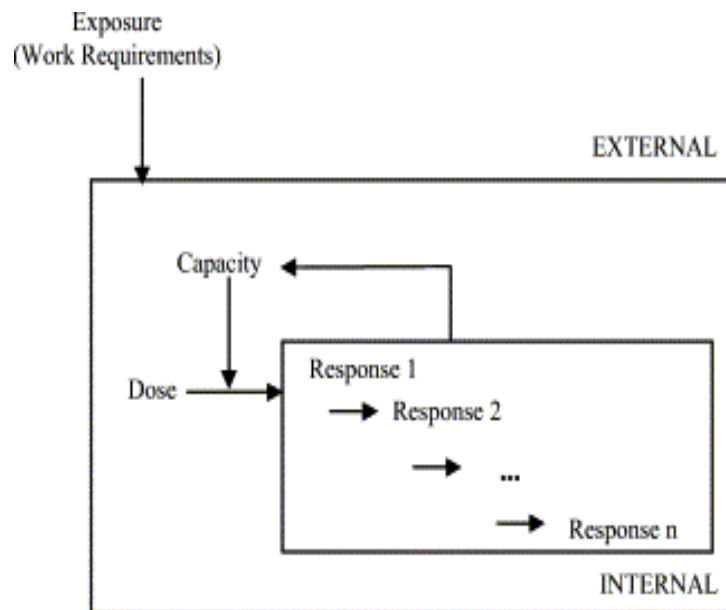


Figure 2-21: Conceptual model for WRULDs (Armstrong *et al* 1993)

Concerning nerve injury, the cumulative cycle can start with compression that inhibits the transport signal of the nerve impulses, impairs blood flow and inhibits oxygenation of the Schwann cells and myelin sheath of the tendons (Hagberg, *et al* 1995; Rempel, *et al* 1999; Buckle, Devereux, 2002). The nerve tissue can usually recover quickly but if there is inadequate rest time the ability of the nerve to react to added internal force or compression decreases, further reducing the capacity of the nerve to function normally. If the cumulative cycle continues structural tissue

deformation and permanent nerve damage can occur (Viikari-Juntura, Silverstein, 1999).

A similar cumulative cycle may occur in the blood and nutritional supply of the tendons, resulting in a further increase in force and compression of the adjacent anatomical structures (Tanaka, McGlothlin, 1993). If the tendon does not have time to rest and recover, inadequate lubrication leads to increased friction and results in the tendon being strained. The friction damage can produce scar tissue, which remains after the recovery from the initial strain. This scar tissue increases friction further and continues to cause problems (Tanaka, McGlothlin, 1993).

A fundamental distinction can be made between specific conditions that are well recognised, with diagnostic symptoms and those of a non-specific nature which lack a clear diagnosis (Boocock *et al* 2009). Table 2-1 gives examples of specific and non-specific WRULDs.

Table 2.1: Examples of specific and non-specific WRULDs

Specific clinically diagnosable WRULDs	Non-specific WRULDs
Carpal tunnel syndrome (CTS) Tendonitis Tenosynovitis de Quervain's syndrome Lateral epicondylitis Thoracic outlet syndrome	Non-specific work-related upper limb disorder Occupational overuse syndrome Repetitive strain injury Repetitive strain disorder Cumulative trauma disorder

Specific WRULDs have an etiology that is localized to particular anatomical structures and includes conditions that result from inflammation of tendons and their surrounding structures such as tendonitis, tenosynovitis, de Quervain's syndrome and lateral epicondylitis and conditions that affect the nerves of the upper limb such as thoracic outlet syndrome and CTS. The non-specific disorders cannot be assigned to any of the conventionally accepted clinical categories, with symptoms of pain and dysfunction often reported at several sites in the upper limb, shoulders and neck (Boocock, *et al* 2009). A study developed in the UK produced data that suggested that approximately 50% of cases of upper limb disorder reported have a non-specific classification (Buckle, Devereux, 2002).

Tendon injury

Tendons are tough yet flexible bands of fibrous tissue that form the connection between the muscle and bone to enable movement. The form and function of tendons are described in section 2.1.2. A normal functioning tendon glides easily and smoothly in response to muscle contraction but when the tendons become inflamed the gliding action of the tendon pulling on the muscle becomes irritated and may result in a tendon injury such as tendonitis, tenosynovitis and de Quervain's syndrome.

Tendons are subject to many types of injuries that come in various forms and generally result in inflammation, degeneration or weakening of the tendons, which may eventually leads to tendon rupture (Sharma, 2006). Tendon injury is mainly associated with overuse and includes repetitive mechanical load, tears, and acute and chronic phases of inflammation that can lead to tendon degeneration (Fredberg,

Stengaard-Pedersen, 2008). Repeated heavy loading can produce initial pathological changes in either the extracellular matrix or the cellular components of a tendon (Khan, *et al* 1999). When the mechanical load exceeds the tendon's capabilities (resistance), the structure of the tendon can become disrupted and collagen fibres begin to slide past one another and denature, causing inflammation edema and pain (Kannus, 1997). Cumulative trauma is thought to weaken collagen cross-linking and the non-collagenous matrix and vascular elements of the tendon, and finally leads to irreversable tendon damage (Kannus, 1997).

Tendonitis is a form of tendon injury that translates from Latin as 'inflammation of the tendon' (Hamill, Knutzen, 1995). Figure 2-22 shows the anatomy of the wrist and the area where tendonitis occurs.

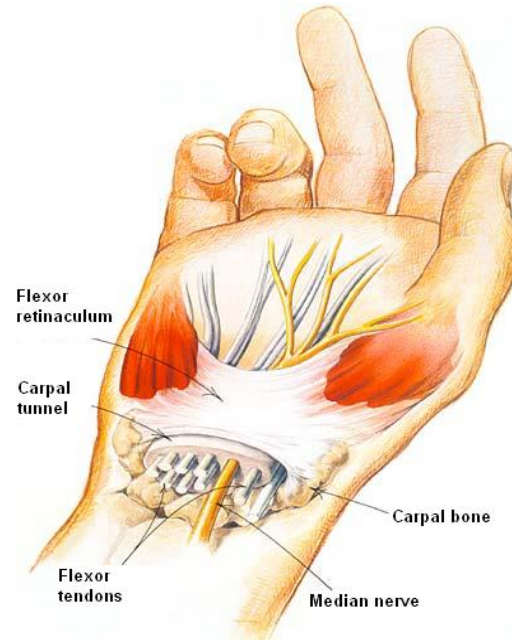


Figure 2-22: Anatomy of the wrist showing the flexor tendons involved in tendonitis (<http://maxcdn.fooyoh.com/files/attach/images.jpg>. Last viewed 05/04/10)

Tendonitis can affect the tendons in the regions of the shoulder, elbow, wrist, finger, thigh, and knee or back of the heel. Symptoms cover a spectrum from aches, pains and local stiffness to a burning sensation in the joint that surrounds the inflamed tendon. Swelling may occur together with heat and redness and there may be visible bulges around the joint. The pain usually worsens during and after activity, and the joint in the inflamed area may become stiffer in the following days (Hertling, Kessler, 2006).

Tenosynovitis is another form of tendon injury and involves inflammation of the protective sheath of tissue called the synovium. Most tendons that cross joints are surrounded by the synovium sheath which produces synovial fluid during activity and allows the tendon to move easily by preventing friction (Nordin, Frankel, 2001). Symptoms of tenosynovitis include pain, tenderness, swelling and stiffness of the joint which is moved by the tendon. It may just last a few days, but in some cases can go on for many weeks or even months. Tenosynovitis can affect any tendon in the body but it is more common in the hand and wrist (Hamill, Knutzen, 1995). The joint that is attached to the tendon may be stiff and painful and there is tenderness and swelling over and around the affected area which is sometimes warmer than the surrounding skin (Hamill, Knutzen, 1995). Figure 2-23 is a representation of tenosynovitis.

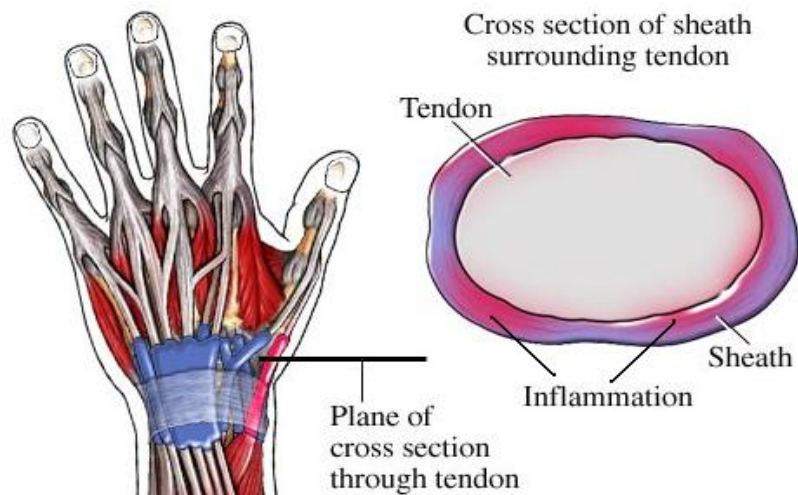


Figure 2-23: Tenosynovitis of the wrist

(<http://claralieu.files.wordpress.com/2008/01/tenosynovitis.jpg>. **Last viewed 05/04/10**)

The cause of tenosynovitis is thought to be overuse through heavy and/or repetitive physical activity. Other possible causes could be linked to rheumatism, arthritis or infection but in many cases it is impossible to clearly identify what led to the disorder (Hertling, Kessler, 2006).

De Quervain's syndrome (also known as washerwoman's sprain, de Quervain disease, de Quervain's tenosynovitis) is an inflammation of the sheaths surrounding two tendons on the side of the wrist at the base of the thumb. These tendons attach to the extensor pollicis brevis and the abductor pollicis longus muscles which run side by side, and function to produce radial abduction of the thumb (Hertling, Kessler, 2006). Figure 2-24 illustrates de Quervain's syndrome.

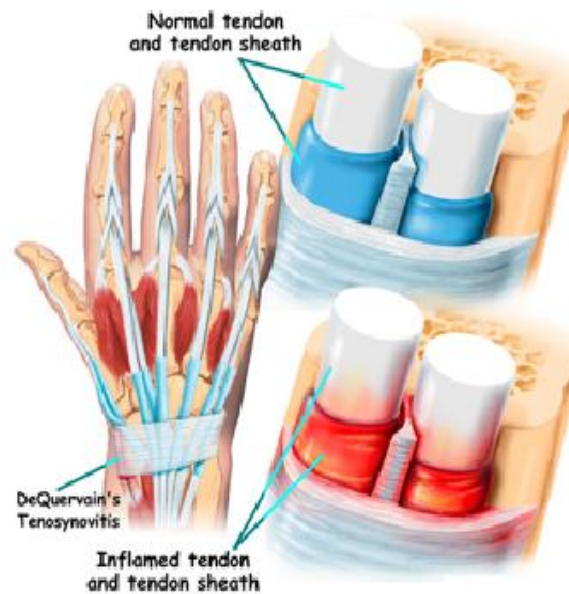


Figure 2-24: de Quervain syndrome

(<http://www.aurorahealthcare.org/healthgate/images.jpg>. Last viewed 05/04/10)

The cause of de Quervain's syndrome is not known. Some claim that the syndrome should be included among overuse injuries and that repetitive movements of the thumb are a contributing factor, but there are no scientific data that supports this theory (Ilyas, *et al* 2007). Symptoms of de Quervain's syndrome are pain, tenderness, and swelling over the thumb side of the wrist, along with difficulty in gripping. Pain is aggravated by lifting the thumb away from the hand or when using scissors (Hertling, Kessler, 2006). There is also little evidence that it is caused by work activities, but the pain can certainly be aggravated by hand use and is commonly seen in people who use handheld devices, which has led to the condition being dubbed "Blackberry Thumb" (Ilyas, *et al* 2007).

Lateral epicondylitis (common name: tennis elbow) is the medical term for a painful condition that affects the tendons of the extensor carpi radialis brevis (ECRB) muscle in the area around the bone in the elbow called the lateral epicondyle. The tendons of the extensor digiti minimi (EDM) muscle which is involved in extension of the wrist also has its origin at the elbow and can be affected by the disorder. It is a non-inflammatory degenerative disease that develops when the tendons that join the ECRB and EDM muscles of your forearm to the humerus, tear or rupture (Nirschl, Pettrone, 1979). Figure 2-25 shows the anatomy of the elbow in the area affected by lateral epicondylitis.

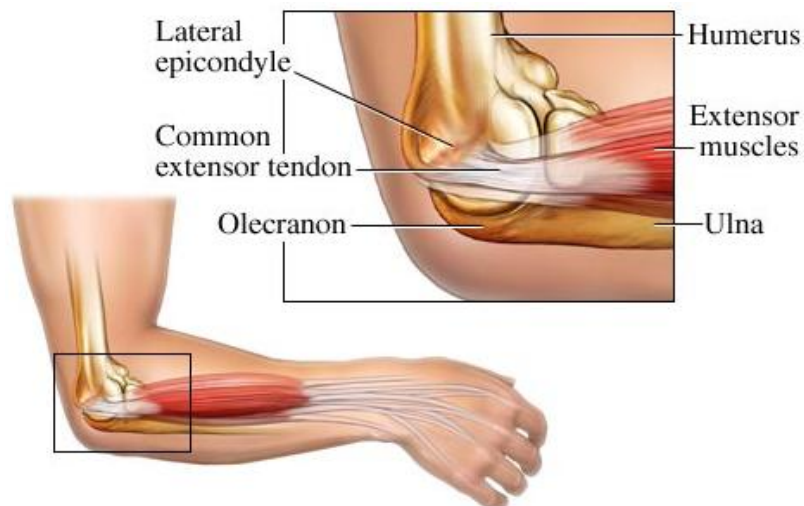


Figure 2-25: The area affected by lateral epicondylitis

(http://www.otsmed.com/images/tennis_elbow.jpg. Last viewed 05/04/10)

The most common cause of lateral epicondylitis is repeated overuse of the arm which may become worse if the activity that triggered the pain continues, resulting in a more serious tear or rupture to the tendon. The symptoms include pain and tenderness on the outside of the elbow and at the wrist (due to the involvement of the tendons of the

EDM muscle in the disorder) especially during gripping, wrist extension and lifting movements and sometimes in the muscles at the top of the forearm. It usually develops gradually on the dominant side because this is the arm most used (Hertling, Kessler, 2006).

Most people who develop lateral epicondylitis do not play tennis. There is a range of different activities including those involving repeated hand, wrist and forearm movements that are more likely to be the cause. This includes activities like using a screwdriver, using vibratory work equipment (such as a drill), or even using a keyboard (Kaminsky, Baker, 2003).

Nerve injury

Nerve injury produces a long-lasting neuropathic pain, but the mechanism underlying the lasting abnormal pain is not well understood (Zhang, *et al* 2004). Classification of nerve injury has been traditionally based on a three-grade system which include neurapraxia, axonotmesis and neurotmesis (Seddon, 1943).

The mildest grade of nerve injury is called neurapraxia, which results from a reduction or complete block of nerve conduction across a segment of a nerve while preserving the conduction both proximally and distally to the injury (Grant, *et al* 1999). Axonotmesis is a more severe grade of nerve injury and is the result of damage to the axons but with preservation of the internal structures such as the connective tissue sheath (endoneurium), epineurium and Schwann cell tubes (Grant, 1999). Neurotmesis is the most severe grade of peripheral nerve injury and occurs when the axon, myelin, and connective tissue components are damaged and disrupted

(Schwartz, 1999). Recovery through axonal regeneration cannot occur. This grade of injury includes nerve lesions in which external continuity is preserved but intraneural fibrosis occurs and blocks axonal regeneration (Schwartz, 1999).

Although the peripheral nervous system is relatively resistant to ischemia, long periods of stretch and compressive force can cause vascular compromise and ischemia (Adams, Duchen, 1992). Other causes of neurapraxia include ischemia secondary to vascular compromise, metabolic derangement, and diseases or toxins causing demyelination of the nerve (Grant, 1999).

Section 2.1.3 described the conditions imposed on the peripheral nerves during everyday postures and movements caused by stress on the nerve. The application of a consistent tensile stress will result in a progressive increase in nerve strain resulting in physiological and structural alterations in the nerve. With increasing tensile load, structural separation occurs first in the core-sheath interface, then in the axons and connective tissues in the endoneurial core, and finally in the cells and connective tissues of the perineurial and epineurial sheath. When the amount of applied load damages particular elements of the nerve, the transition between the recoverable strain and permanent deformation occurs (Topp, Boyd, 2006). With fewer intact structural elements to provide resistance, when the nerve reaches its full elongation length mechanical failure can occur (Topp, Boyd, 2006).

Direct damage to myelin and axons from compressive stress has been shown to occur with extraneural compression of as low as 50 mm Hg maintained for 2 minutes, with the axons in the compressed area showing evidence of demyelination, focal myelin

thickening, and axonal degeneration (Dyck, *et al* 1990). Intraneural blood flow and sensory responses are blocked at extraneural tissue pressures 45 mm Hg below the mean arterial pressure (Powell, Myers, 1986). A compressive stress of only 30 mm Hg, if maintained for 2 hours, results in endoneurial edema (Powell, Myers, 1986) and, if maintained for 8 hours, results in endoneurial pressure high enough to subsequently impair blood flow (Lundborg, *et al* 1983). The same compressive stress of 30 mm Hg applied for 8 hours is sufficient to impair axonal transport (Lundborg, *et al* 1983).

The pathological consequences of prolonged compression include subperineurial edema; inflammation; deposition of fibrin; activation of endoneurial fibroblasts, mast cells, and macrophages; demyelination; axon degeneration; and fibrosis (Powell, Myers, 1986).

In general, most nerve injuries result in increased nerve swelling and pressure caused by endoneurial edema with mechanical injury and focal demyelination causes the conduction block associated with this type of injury (Grant, 1999).

CTS and thoracic outlet syndrome are both common nerve injuries and while thoracic outlet syndrome is discussed below CTS is discussed in the following section.

Thoracic outlet syndrome is a nerve injury that refers to a group of disorders involving compression at the superior thoracic outlet, a neurovascular structure in the area just above the first rib and behind the clavicle (Hertling, Kessler, 2006). This compression affects the brachial plexus which is the origin of the nerves that pass into the arms from the neck, and/or the subclavian artery and vein which carry the blood

vessels between the chest and upper extremity. Figure 2-26 illustrates the area of compression in the thoracic outlet.

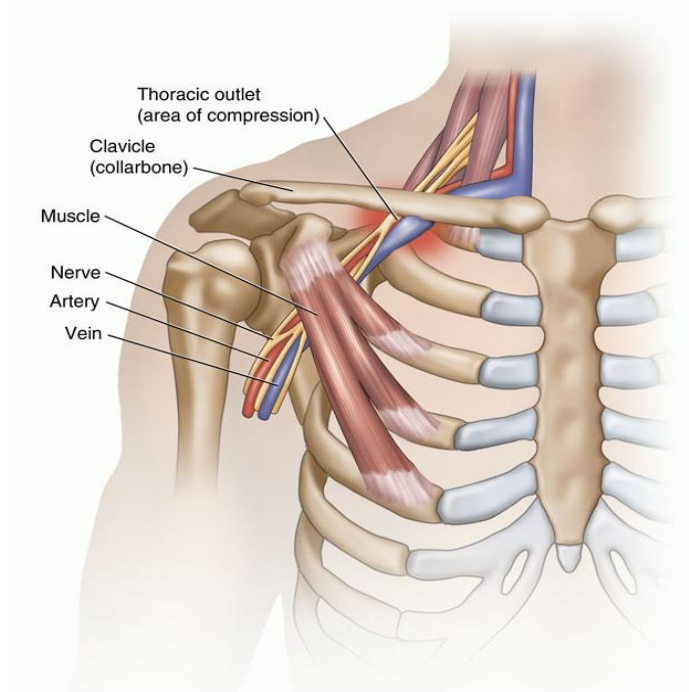


Figure 2-26: Thoracic outlet – area of compression

(<http://media.summitmedicalgroup.com/media/db/relayhealth-images/thoracic.jpg>.

Last viewed 05/04/10)

The thoracic outlet is surrounded by muscle, bone, and other tissues and any enlargement or movement of these structures can cause thoracic outlet syndrome. Due to the brachial plexus, subclavian vein, and subclavian artery being affected, thoracic outlet syndrome is usually classified into neurological, venous, and arterial forms. However, diagnosis and treatment are controversial and often no specific cause is found (Sanders, *et al* 2007).

Symptoms of thoracic outlet syndrome include pain and numbness in the neck, shoulder, and arm or impaired circulation to the extremities that can cause a discoloration in the skin. Individuals can have a wide spectrum of symptoms from mild and irregular, to severe and steady. Pains can extend to the fingers and hands and can cause weakness and impairment when gripping (Hertling, Kessler, 2006).

Individuals who have suffered a neck injury such as, for example, whiplash in a motor vehicle accident and keyboard users who adopt non-ergonomic postures for extended periods of time are more likely to develop thoracic outlet syndrome (Hertling, Kessler, 2006).

2.2.4. Entrapment neuropathies and the median nerve

Peripheral nerves are vulnerable to injury as they travel through the upper limb due to their superficial location. However, injuries tend to occur at certain points where the area around the nerve is more constrained and often within anatomical tunnels (Hoochman, Zilberfarb, 2004). Entrapment neuropathy is a term that relates to the impingement or compression on the peripheral nerves by adjacent anatomic structures. This compression may result in an impairment of the conduction of impulses along a nerve and can result in weakness or wasting of the muscles supplied by the nerve along with motor function and sensory loss.

Long term exposure to compression may produce irreversible nerve damage, however if the degree of compression is minimal there may be no clinical evidence of impaired conduction (Campbell, 1997). The main entrapment neuropathies of the upper limbs

involve the median nerve, ulnar nerve, or radial nerve and are shown in Table 2.2 which is followed by a sub-section detailing the disorders of the median nerve.

Table 2.2: Nerves of the upper limb and their specific disorders

Nerve	Disorder
Median nerve	Pronator syndrome Anterior interosseous syndrome Carpal tunnel syndrome
Ulnar nerve	Cubital tunnel syndrome Ulnar tunnel syndrome
Radial nerve	Radial tunnel syndrome Posterior interosseous syndrome Superficial radial nerve syndrome

Pronator Syndrome

Pronator syndrome is a median nerve entrapment syndrome that can involve multiple sites of compression including the elbow and proximal forearm. The symptoms are pain in the forearm that is aggravated by activity and relieved by rest along with a decreased sensation in the thumb, index finger, middle finger, and radial side of the ring finger and weakness of thenar muscles (Morris, Peters, 1976).

Anterior Interosseous Syndrome

Anterior interosseous syndrome involves compression of the branch of the median nerve arising approximately 6 cm below the elbow and supplying motor function to the index finger, whose causative factors include tendonous bands, abnormal radial

artery branches, and fractures. Symptoms include indistinct pain in the proximal forearm and weakness in the index finger along with an inability to form a circle by pinching their thumb and index finger together (Hill, *et al* 1985).

Carpal Tunnel Syndrome

Carpal tunnel syndrome (CTS) is a result of median nerve compression within the carpal tunnel and is the most commonly studied nerve disorder of the upper limb (Buchberger, 1992). It is characterized by pain, abnormal skin sensations (as tingling or tickling or itching or burning), and numbness in the distribution area of the median nerve and in advanced cases, weakness and deterioration of the thenar muscles (Yassi, 1997). The cause of CTS can be a combination of nerve compression, reduced blood supply and stimulation of the body's stress response (Tanaka, McGlothlin, 1993).

This results in a low level inflammation of the nerve and a reduction in its conduction velocity, which generates the symptoms and results in difficulties in performing daily hand activities (Tanaka, McGlothlin, 1993).

The carpal tunnel contains the median nerve and the nine extrinsic flexor tendons of the thumb and fingers with an anterior surface formed by the flexor retinaculum. Any process that increases the compression on the median nerve within the carpal tunnel, including disorders that affect the other structures within the tunnel, can cause CTS. If the pressure or compression within the tunnel rises to a significant level, congestion within the blood and nutritional supply of the nerve results in oedema (an excessive accumulation of serous fluid in the intercellular spaces of the surrounding tissue) and a further increase in carpal tunnel pressure (Tanaka, McGlothlin, 1993). If this persists, fibroblasts (a cell from which connective tissue develops that synthesizes

collagen) multiply producing scar tissue and irreversible damage to the nerve. Figure 2-27 shows the region of the hand affected by median nerve compression in CTS.

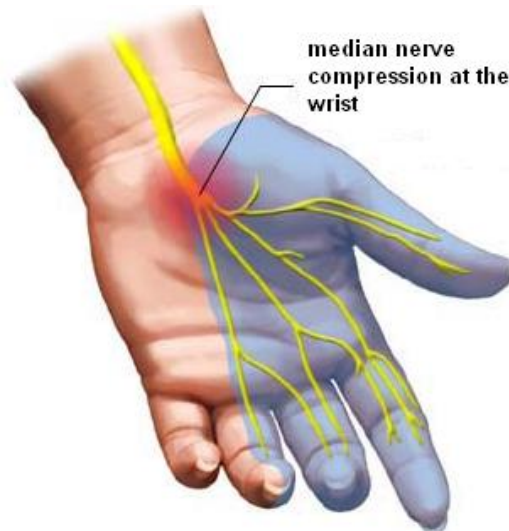


Figure 2-27: Median nerve compression in CTS

(www.nlm.nih.gov/medlineplus/ency/images/ency.jpg. Last viewed 04/05/10).

Subjects with carpal tunnel syndrome have been shown to have higher pressures in the carpal tunnel than control subjects, and carpal tunnel pressure is altered by muscle activity and wrist posture (Rempel, Diao, 2004).

If the activity is continued, the initial inflammation within the wrist may progress to a swelling of the structures producing a further increase in carpal tunnel pressure which could eventually lead to chronic tenosynovitis and permanent damage to the median nerve (Tanaka, McGlothlin, 1993).

Additional factors involved in median nerve disorders

Along with the work-related factors that can cause median nerve disorders other factors can also contribute. CTS is a common feature of diabetic neuropathy in diabetic patients and results in a decreased or distorted nerve impulses that mainly affects sensation. The severity of the disorder is related to the patient's age and the length of time they had diabetes (Comi, *et al* 1985).

Autoimmune diseases including rheumatoid arthritis and hypothyroidism, results when the body's immune system attacks tissue and can cause widespread inflammation which may affect the carpal tunnel. Arthritis, gout, and other medical conditions that damage the muscles, joints, or bones in the hand can also cause changes that lead to median nerve dysfunction (Pal, 1997). Osteoporosis (loss of bone density), is not a direct cause of nerve dysfunction but can increase the risk of wrist fractures that can lead to median nerve disorder (Erselcan, *et al* 2001).

Obesity and lack of fitness increase the risk of nerve dysfunction. Increased body mass appears to reduce the nerve impulses into the hand (Werner, *et al* 2004).

Hormonal fluctuations in women are thought to play a role in median nerve disorders and include fluid retention which is one reason that CTS may develop during pregnancy (Baumann, *et al* 2007).

Median nerve disorders are strongly associated with a family history of the disorder. Many of these cases can be attributed to physical characteristics or medical conditions associated with CTS, which also run in families (Hakim, *et al* 2002). Other genetic factors may contribute to this disorder and include abnormalities in certain genes that

regulate myelin (a fatty substance that serves as insulation for nerve fibres) and genes that produce increased levels of a collagen subtype used to build all connective tissue, muscle, bones, and ligament (Stevens, *et al* 1992).

The Labour Force Survey detailed previously in this chapter, investigated work-related illness in the UK (Health and Safety Commission, 2003) and reported that the average prevalence rate for disorders of the upper limbs or neck was nearly a fifth higher for females than for males (1.3% of females and 1.1% of males who have ever worked). For both males and females prevalence rates were highest in the older working age group, 1.9% of males and 2.7% of females who have ever worked (age 45 to retirement).

Hormonal factors have already been mentioned as one possible explanation for the higher prevalence of upper limb disorders among females however, it has also been suggested that the work that females perform has a greater exposure to repetitive hand movements and general static postures (more standing than seated) while male employment involves more load lifting and walking during their working day (Hagberg, Wegman, 1987; Buckle, 1997; Buckle, Devereux, 2002; Punnet, Wegman, 2004; Treastera, Burra, 2004). Another possible explanation could be that females report symptoms more readily but the results from research in this area have been inconsistent, with differences in the accuracy of responses from the female participants that took part in the studies (Gusbers Van Wijk, Kolk, 1997).

2.3. Assessment of Hand and Wrist Injury

Diagnosis of WRULDs of the hand and wrist has been traditionally based on physical examination and electrodiagnostic testing (as described below). However there are now several imaging procedures that can not only contribute to the diagnosis of injury but also be used to advance existing knowledge of the normal physiology of the hand and wrist. These imaging technologies included in this sub-section are computed tomography (CT) and magnetic resonance imaging (MRI) with high resolution ultrasonography being detailed in the following section.

2.3.1. Physical Examination

Passive motion tests such as Tinel's test and Phalen's sign are simple physical examinations specifically for assessing CTS. Tinel's test demonstrates nerve irritability by lightly tapping (compressing) the nerve as it passes through the carpal tunnel, with a positive tests for CTS resulting in pain and a sensation of tingling in the distribution area of the median nerve (Scheri, Templeton, 2003). Figure 2-28 illustrates Tinel's test.

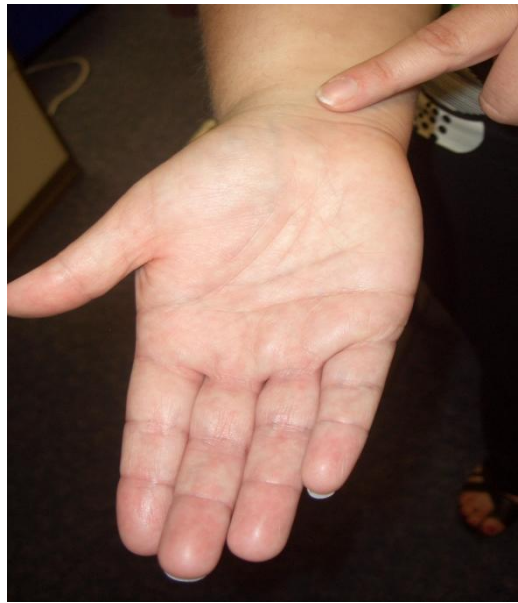

Figure 2-28: Tinel's test

Phalen's test reproduces the symptoms of CTS using the palmar flexion of both wrists with the dorsal aspects of the hands held together for 30-60 seconds. This increases the pressure in the carpal tunnel. A positive test results in the characteristic symptoms of CTS (pain, numbness and tingling over the thumb, index, middle and ring fingers (Scheri, Templeton, 2003). Illustrations of Phalen's sign are shown in Figure 2-29



Figure 2-29: Phalen's sign

2.3.2. Electrodiagnostic Testing (EDT)

Electrodiagnostic testing is a tool that evaluates the character, location and severity of nerve and muscle dysfunction. When a nerve is compressed the myelin sheath (an encasement of insulating tissue that surrounds the nerve and facilitates the transmission of nerve impulses) is affected and results in the slowing of nerve impulse conduction (Hoochman, Zilberfarb, 2004). The decrease in motor and sensory impulses is the quantitative change that EDT detects and records (Hoochman, Zilberfarb, 2004). EDT is constructed of both nerve conduction studies (NCS) and electromyography (EMG), which are often performed alongside each other but offer distinct and different information (Chemali, 2005).

NCS measure the speed at which a motor and/or sensory nerve transmits impulses and is a non-invasive, painless test. Two pairs of flat electrodes are placed on the surface of the skin, one pair more proximal to the main trunk of the body and one pair more distal. The proximal pair stimulates the nerve being examined by the application a low level electric current with the distal pair recording the resulting electrical activity (Scheri, Templeton, 2003). The velocities at which the electrical impulses are transmitted through the nerve are divided by the known distance between the electrodes to give the nerve conduction velocity which is revealed on either a computer screen or an oscilloscope. If there is a reduction in nerve response to stimulation when compared to base-line data obtained from a normal nerve response, then this suggests nerve damage (Scheri, Templeton, 2003). Figure 2.30 shows a NCS and the associated recording of the electrical activity.

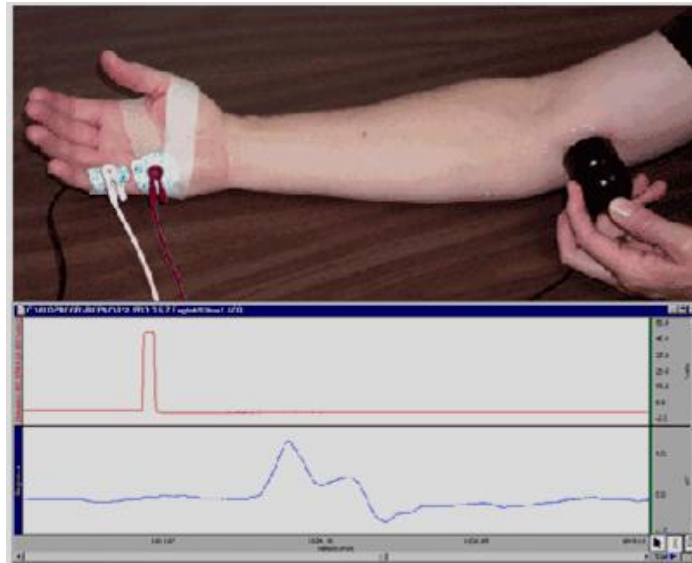


Figure 2-30: NCS of the arm. (<http://www.ebme.co.uk/arts/nerve/nerve2.gif>. Last viewed 04/05/10)

EMG is a technique for evaluating the electrical activity produced by muscles and records this activity onto a myogram. It is performed using an instrument called an electromyograph, which detects the electrical activity generated by muscle cells when they are electrically or neurologically stimulated (Nikias, Raghuvver, 1987). While NCSs are useful to monitor the general picture of muscle activation, EMG monitors the activity of only a few fibres (Scheri, Templeton, 2003).

Intramuscular EMG involves inserting a needle electrode or a needle containing two fine-wire electrodes through the skin into the muscle tissue and observing the resulting electrical activity during contraction of the muscle (Scheri, Templeton, 2003). Normal muscle at rest produces certain electrical activity when the needle is inserted. This activity is detected by an electrode and displayed on a computer screen or an oscilloscope. Abnormal spontaneous activity indicates some nerve and/or

muscle damage (Scheri, Templeton, 2003). Figure 2-31 is an illustration of a needle being inserted into a muscle and the recorded activity on a computer screen.

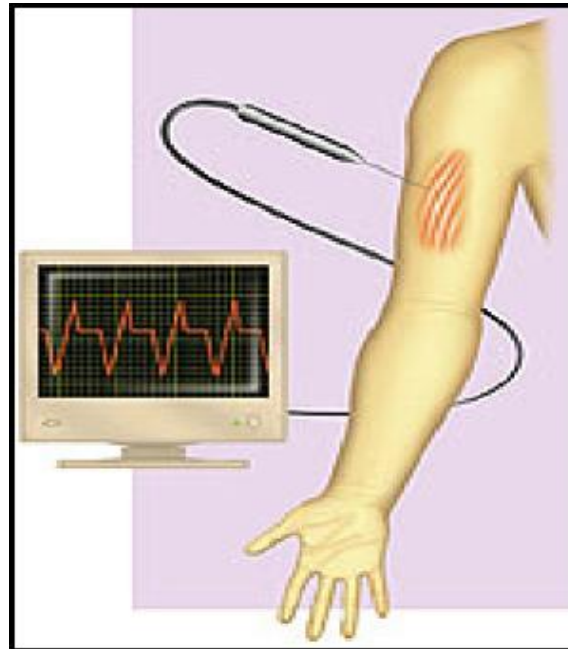


Figure 2-31: Insertion of the needle EMG into a muscle.

(<http://eegemg218.com/images/emg>. Last viewed 04/05/10)

EDT is useful in differentiating between nerve and muscle dysfunction and distinguishing between partial and complete nerve impairment however, there is considerable controversy over the validity and accuracy of NCS for diagnosing CTS. A definitive conclusion may be difficult when the findings are non-specific, inconsistent, when multiple sites of nerve compression are involved or when another condition mimics the symptoms of nerve compression or co-exists with it such as arthritis, back strain, diabetic peripheral neuropathy, multiple sclerosis, hyperventilation or stroke (Hoochman, Zilberfarb, 2004). A normal conduction time does not necessarily rule out compression of the nerve such as when the reduction in

the signal is mild or when fast conducting fibres remain intact (Hoochman, Zilberfarb, 2004). Conduction can also be reduced by other forms of neuropathy that are not under investigation at the time of the assessment.

While EDT shows the level at which the injury occurs, it does not provide information about the surroundings anatomy. In addition, EMG can be invasive and mildly uncomfortable. (Altinok, *et al* 2004).

2.3.3. Computed Tomography (CT)

Computed Tomography (CT) is particularly useful in imaging the skeletal system especially regions of complex anatomy such as the pelvis, spine and wrist and it can provide useful diagnostic information on the extent of a wide variety of ailments such as fractures, dislocations, infection, joint disease and genetic or metabolic diseases that could contribute to musculoskeletal disorders (Scheri, Templeton, 2003). The image can be viewed in the axial, coronal, or sagittal planes known as multiplanar reformatted imaging (Freedman, Hart, 2003).

CT scanning involves a computer assisted radiograph in which an X-ray beam traces arcs at multiple angles around sections of the body producing an image of a transverse section of the body called a CT scan (Tortora, Grabowski, 2003). As the X-ray beams are transmitted into the body of the subject being scanned, the amount of radiation that passes through the tissue is detected and processed by a computer. The scan differentiates soft tissue and organs by their different tissue densities and images are

shown in various shades of grey. Multiple scans can be assembled to build a 3-D view of the image being scanned (Tortora, Grabowski, 2003). Figure 2-32 illustrates a CT scan.

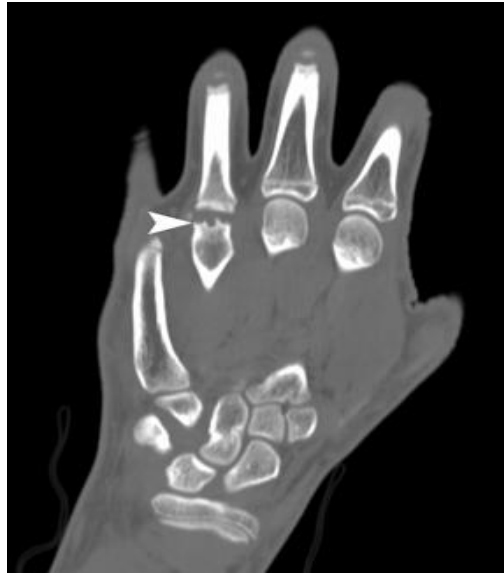

Figure 2-32: CT scan of the hand.

(www.rsna.org/Media/rsna/RSNA08_newsrelease_target.cfm. **Last viewed 04/05/10**)

CT possesses a good contrast resolution and can provide information regarding the diagnosis of a wide variety of disorders that could contribute to musculoskeletal disorders but it is not sufficient enough to identify soft tissue changes within the carpal tunnel (Freedman, Hart, 2003). It is high in cost in relation to the purchase, instillation, use and maintenance of the technology. In addition, it employs X-ray radiation and is therefore not recommended for children or pregnant women because of the risk to the unborn baby.

At this present time most CT scanning procedures involve the participant remaining static during image acquisition however, the development of dynamic CT imaging has provided a means to capture images during physical joint movement, provided that the velocity of the movement is not too fast (Tay, 2008). Techniques for assessing joint motion using CT involves slow and sequential periodic movements to obtain a series of images that represent the joint motion with retrospective techniques that compile the multiple images required to characterize a single motion (Tay, 2008).

Dynamic real time CT technology is limited by low frame rates and equipment that is too restrictive for most dynamic activities. However, advances in CT technology, such as faster temporal resolution and wider detector coverage, will in the near future, improve dynamic wrist imaging by overcoming the limitations (Tay, 2008).

2.3.4. Magnetic Resonance Imaging (MRI)

Magnetic resonance imaging (MRI) is an imaging technique that produces high quality images of the inside of the human body. It is especially good at detailed visualizations of soft tissue structures and can image pathological changes and subtle injuries seen in some musculoskeletal disorders (Altinok, *et al* 2004).

The human body is primarily fat and water which consist of many hydrogen atoms. Hydrogen nuclei have an NMR signal produced from the hydrogen proton which possesses a property called spin. For these reasons magnetic resonance imaging primarily images the NMR signal from the hydrogen nuclei.

MRI detects electromagnetic signals released from the body when it is placed within a powerful magnet field and subjected to radio waves (Freedman, Hart, 2003). The magnetic field aligns the atoms in the body being scanned and the radio frequency fields alter this alignment. When an additional magnetic field is applied, perpendicular to the main field, some atoms rotate in a different direction, before realigning with the main field over time (Freedman, Hart, 2003).

As the atoms in different tissues of the body realign at different speeds, the speed at which this realignment takes place is a result of the signal characteristic of the tissue. Each tissue is characterized by its hydrogen density and two magnetic relaxation constants: the longitudinal constant T1-weighted and the transverse constant T2-weighted (Freedman, Hart, 2003). This in turn, affects how bright the tissues appear on the image of the scan known as its signal-intensity (Altinok, *et al* 2004).

MRI can image the normal and pathological anatomy of the carpal tunnel with the bones appearing as high signal-intensity structures while the flexor retinaculum, the flexor tendons and the median nerve appearing as low signal-intensity structures. Cross-sectional scans of the normal median nerve show it to be round or ovoid in shape, while images of the nerve from patients with CTS show an increase in swelling, flattening along with increased signal-intensity. Figure 2-33 shows a MRI scan of the carpal tunnel.

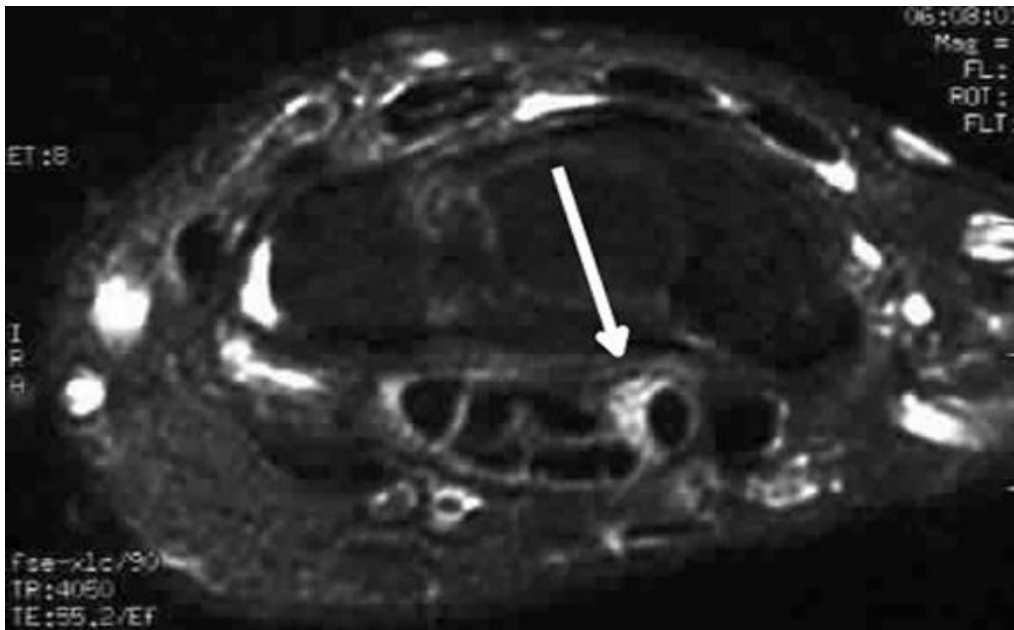


Figure 2-33: Axial fast spin-echo T2-weighted MRI scan of the median nerve (shown by the arrow) within the carpal tunnel

(www.emedicine.medscape.com/article/388525-overview **Last viewed 23/10/10**)

MRI scanners are able to generate multiple two-dimensional cross-sectional slices of tissue along with three-dimensional reconstructions of the area being scanned. It provides a much greater contrast resolution between the different soft tissues of the body when compared to CT, which is better at imaging bony structures. This makes MRI especially useful for musculoskeletal imaging within the carpal tunnel (Haacke, *et al* 1999). In addition unlike CT, it does not use X-rays making it relatively safer. However, the high cost of purchasing, installing, maintaining and operating the technology and equipment results in an expensive procedure with limited availability which has prevented its extensive use in the assessment and diagnosis of WRULDs (Freedman, Hart, 2003).

More recently, dynamic MRI has been developed and used as a tool for the measurement of human movement including cardiac, joint, and muscle motion (Drapper et al 2009). It has been described by various names, including kinematic MRI (Powers, *et al* 1998. Shellock, *et al* 1993), cine phase contrast MRI (Sheehan, *et al* 1998. Sheehan, *et al* 1999), motion-triggered cine MRI (Brossmann, *et al* 1993), or fast phase contrast MRI (Rebmann, *et al* 2003). Studies into physical movement obtain a sequential series of images as the participant executes a discontinuous motion (typically flexion and extension), with each MR image acquired at a periodic phase representing different positions of the joint motion. Thus, multiple images are required to represent a single motion (Bey, et al 2008).

At present, dynamic MRI imaging has limitations similar to those associated with dynamic CT (Dupuy, *et al* 1997). The procedure is still too slow for the examination of rapidly moving organs and joints and it is limited by the physical dimensions of the MRI scanner which do not allow for certain activities that involve sizeable ranges of motion in the joints (Bey, *et al* 2008).

The advent of short-bore high-field systems and open MRI units, provides greater opportunity to apply dynamic MRI techniques. With faster imaging techniques, dynamic MRI imaging will evolved from simply displaying static images in a dynamic format to acquiring images at a rate that provides true dynamic information on joint movements. Accuracy will also improve with developmental accessories such as motion-tracking sensors and patient-positioning devices for providing controlled reproducible joint movements (Drapper et al 2009).

2.2. High Resolution Ultrasonographic Imaging

High resolution ultrasonography is an imaging technique that involves exposing part of the body to sound waves that have a frequency greater than the upper limits of human hearing (above 20kHz) with the returning echo being processed and transformed by computer software, into images of the soft tissue structures in the area being scanned (Walker, *et al* 2004).

The emergence of ultrasonography more than three decades ago has marked the advent of its use in a variety of medical specialties but it is most commonly known for its use in obstetrics, in which it is used to visualize the embryo or foetus in the uterus and can provide information on the health of the mother, the un-born baby and the overall progress of the pregnancy (Ziskin, 1991). Figure 2-34 shows an ultrasonographic image of a foetus during pregnancy.

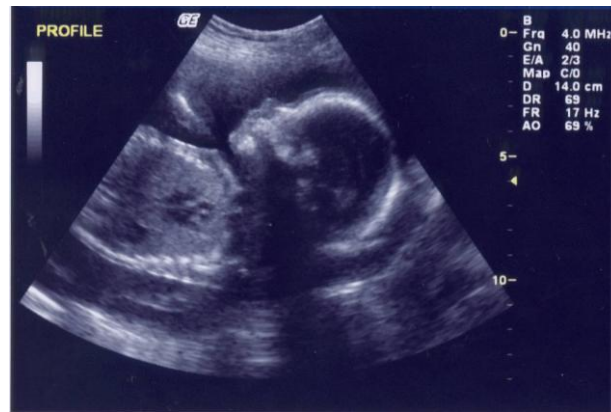

Figure 2-34: Fetal ultrasound scan. (Ziskin, 1991)

Other ultrasonographic scans routinely conducted are cardiac (Douglas, 2007), renal (Brown, *et al* 1997), liver (Debongnie, *et al* 1981) and gallbladder (Blair, *et al* 1983) as well as applications such as ultrasound eye scans (Cass, *et al* 2002), testicle (Dogra, *et al* 2008), thyroid, (Rago, *et al* 2001), salivary glands (Gritzmann, *et al* 1989), and lymph node scans (Baatenburg De Jong, *et al* 1988).

Recent advances in real time dynamic imaging capabilities of ultrasonography now allows for the imaging of soft-tissue structures within the body such as the muscles, tendons and the peripheral nerves, during physical movement (Walker, *et al* 2004). The dynamic imaging capabilities has also established ultrasonography as a means of imaging blood flow (Polito, *et al* 2006) and it is often used to guide interventional procedures such as fine needle aspiration (Peric, *et al* 2010) or biopsy of masses for cytology or histology testing in the breast, thyroid, liver, kidney, lymph nodes, muscles and joints (Jones, *et al* 2004).

2.4.1. Ultrasonographic Equipment

The basic ultrasonographic equipment consists of a linear array transducer probe that sends and receives the sound waves, a central processing unit (CPU) computer that processes the ultrasound data, the monitor that displays the image and a keyboard and cursor used to input the data and take measurements from the display.

Conventional ultrasound equipment also known as B-Mode, is the most common ultrasonographic tool and produces a two-dimensional image of a three-dimensional structure. The equipment mainly uses the pulse echo approach with a brightness mode (B-mode) display that results in a bright reflection of the structures lying in the wave's path. Sophisticated computer analysis examines the temporal and acoustic properties of the returning echoes from many sequential pulses, to reconstruct an image of the structures in the area being scanned (Walker, *et al* 2004). The cross sectional B-mode image generated by computer analysis is seen directly on a monitor, with superficial structures that produce the earliest returning echoes, shown higher up on the image (Walker, *et al* 2004).

The transducer probe is the main part of the ultrasound equipment. It is placed on the participant being scanned and emits the sound wave into the body, recording any reflected echoes from the interfaces between tissues. The sound wave is generated and received by the probe using piezoelectric crystals in a principle called the piezoelectric effect (pressure electricity effect). When an electric potential is applied to the crystals within the probe they change shape rapidly, producing the sound wave pulse that travels outward. When the sound wave returns back to the probe, a small voltage of electricity is generated by the crystals. Therefore, the same crystals within

the probe, sends and receives the sound waves. Figure 2-35 illustrates a linear array transducer probe.



Figure 2-35: Linear array transducer probe

Conventional ultrasound B-Mode equipment is the most common ultrasonographic system and presents a two-dimensional image of a three-dimensional structure.

However, there are a number of other ultrasonographic systems, all of which involve the sending and receiving of high-frequency sound waves.

Doppler ultrasound is a special technique that measures the change in frequency of the echoes produced by movement of internal structure such as the rate of blood flow through the heart and major arteries (DuBose, Baker, 2009). There are three types of Doppler ultrasound: Color, Power and Spectral Doppler. Color Doppler converts measurements into a range of colours to visualize the speed and direction of blood flow (DuBose, Baker, 2009). Power Doppler is a newer and more sensitive technique that is capable of providing clearer detail of blood flow, especially when blood flow is minimal (DuBose, Baker, 2009). Spectral Doppler is a technique that displays blood

flow measurements graphically (distance travelled per unit of time) instead of visually like the other two techniques (DuBose, Baker, 2009).

Recently, ultrasound systems capable of producing three-dimensional (3-D) and four-dimensional (4-D) images have been developed. The 3-D systems involve acquiring several 2-dimensional images which are combined by specialized computer software to form 3-D images. They are best used for the early detection of tumors, visualizing the foetus and blood flow in various organs (Michailidis, *et al* 2002). 4-D systems allows for 3-D images to be obtained in motion, as real time videos. However they are still a relative new technology and their diagnostic capabilities are still being explored (Benacerraf, *et al* 2005).

While existing ultrasonographic methodologies continue to advance technically by extending into higher frequencies and taking advantage of the harmonic properties in tissues, new ultrasound technologies also are emerging and offer exciting promise for making significant improvements in the imaging of disease and disorders (Feleppa, *et al* 2002). These emerging methods include spectrum analysis, elasticity imaging, contrast-agent methods, and advanced flow detection and measurement techniques (Feleppa, *et al* 2002).

2.4.2. Physics of Ultrasonography

The primary physical principle involved in ultrasonography is the sending and receiving of sound wave pulses at a specific velocity per second. Soft tissue is mainly

made up of water that can both reflect and transmit the sound waves produced from ultrasonography. The reflected sound generates the image at the boundary of the structure being scanned, while the transmitted sound penetrates into deeper levels within the body. In biological structures that have low water content such as bone, there is almost no transmission of the wave with all the sound being reflected back. This produces a bright echo that defines the outer boundaries of the bone but because there is no further sound penetration a shadow is formed and the ability of the sound waves to create images from a deeper level is not possible (Walker, *et al* 2004).

The velocity (v) at which the sound wave travels is determined by the frequency (f) and the wave length (λ) and this relationship can be expressed by the equation

$$v = \lambda f$$

The speed (c) at which ultrasound propagates through tissue depends on the stiffness and density (ρ) of the tissue which can be combined into a parameter known as its acoustic impedance (Z) with the stiffer tissue producing the higher speeds. This relationship is given by the equation

$$Z = \rho c$$

The value given for the acoustic impedance of soft tissue has been reported as $1.64 \times 10^6 \text{ kg.m}^3.\text{s}^{-1}$ while for bone it is $7.68 \times 10^6 \text{ kg.m}^3.\text{s}^{-1}$ (Cameron, Skofronick, 1978).

This shows that a sound wave pulse propagates faster through bone than through soft tissue. If the speed of the sound wave through the medium is known then the reflection from the returning wave can be measured as a function of time and information can be obtained on the position of the tissue.

When a sound wave reaches the boundary between two mediums, the wave can change its behaviour and be reflected off the medium, diffracted or refracted around the medium and/or transmitted into the medium (Cameron, Skofronick, 1978).

The basis of ultrasonography as an imaging technique is the partial reflection of sound at the boundary of two structures that have different acoustic impedances to produce an echo (Cameron, Skofronick, 1978). The ratio of reflection of the sound wave (R) to the incident wave (A_0) depends on the acoustic impedance at the boundary of two media (Z_1 and Z_2) and is given by the equation

$$\frac{R}{A_0} = \frac{Z_2 - Z_1}{Z_1 + Z_2}$$

When sound waves encounter a medium or a boundary with varying acoustic impedance it changes direction and bends around the medium or passes through small openings between two boundaries and spreads out in a process called diffraction. The amount the wave is diffracted depends on the wavelength and the difference in acoustic impedance of the medium or the boundary. The sharpness of the diffraction increases with increasing wavelength and decreases with decreasing wavelength.

When the wavelength is smaller than the medium or opening, no noticeable diffraction occurs.

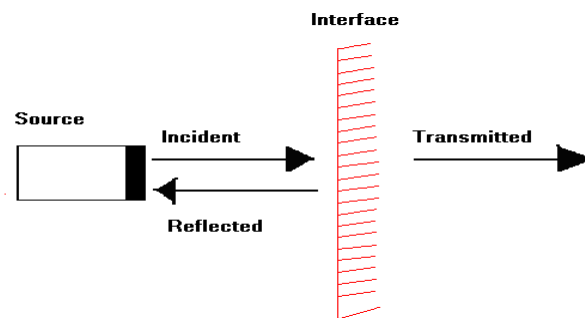
Refraction produces a change in the direction of the sound wave as it passes from one medium to another and is accompanied by a change in its speed and wavelength.

Refraction of sound waves is most evident when a wave passes through a medium with gradually varying properties. The refraction of the transmitted sound wave

depends on the angle of the incident wave and the speed of sound on either side of the boundary (Cameron, Skofronick, 1978).

Figure 2-37 shows the behavior of ultrasound at a boundary from a perpendicular and non-perpendicular incidence. In Figure 2-36 a) a proportion of the ultrasound wave is reflected back to the source while a proportion is transmitted and continues along the original path. In Figure 2-36 b) part of the wave is reflected but not returned to the transducer and part is refracted at a different angle.

a)



b)

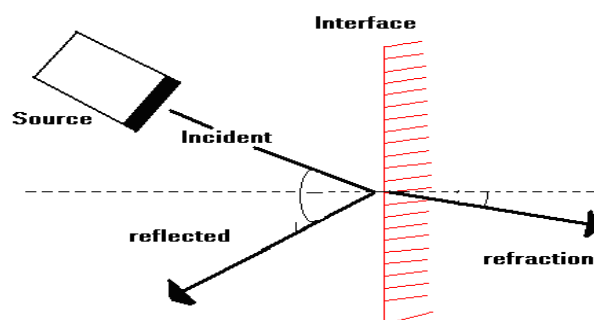


Figure 2-36: Reflection and refraction of an ultrasound wave. (Adapted from Evans, 2006).

If $Z_1 = Z_2$ then there is no reflection and the sound wave becomes completely transmitted. The ratio of the transmitted sound wave (T) to the incident wave (A_0) is given by the equation

$$\frac{T}{A_0} = 2 \frac{Z_2}{Z_1 + Z_2}$$

As an ultrasound wave pulses through tissue the amplitude and intensity of the wave is reduced due to absorption or scattering in a process called attenuation. Absorption is the conversion of the mechanical energy of the sound wave into heat while scattering results in the energy redirected out of the incident energy path. Structures with large differences in acoustic impedance at their boundary produce a scattering of the incident sound wave resulting in the wave being transmitted in all directions (Suetens, 2002).

Figure 2-37 illustrates the scattering of the sound wave. The pattern and the amount of scattering that occurs, depends on the size and the density of the structure within the propagation path of the incident energy. Structures smaller than the wavelength, produce a uniform scattering pattern while larger structures produce a more complex scattering pattern (Suetens, 2002).

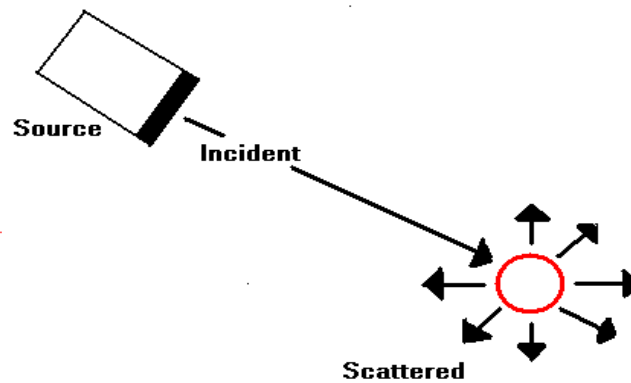


Figure 2-37: Scattering of ultrasound wave. (Adapted from Evans, 2006)

Once the transducer has sent the sound wave pulse and sufficient time has elapsed for all the echoes to return, another sound wave is produced from a slightly different direction and the sequence is repeated. The position of the structure that produced the echo is calculated from the direction that the pulse was transmitted and the time delay between the transmission of the pulse and the receipt of the reflection (Suetens, 2002).

2.4.3. Strengths and weaknesses of ultrasonographic imaging

Although physical examinations and EDT are commonly employed to confirm a diagnosis of nerve pathology and to localise the site of injury it does not allow for the direct visualisation of the anatomical structures being investigated and fails to provide spatial information about the etiology of the nerve and the surrounding structures (Hoochman, Zilberfarb, 2004). Ultrasonography, MRI and CT are techniques that are capable of directly imaging anatomical structures within the body. CT scans have a limited value in the evaluation of nerve compression but are capable of detecting fractures, dislocations, infection, joint disease and genetic or metabolic diseases that could contribute to the

compression of a nerve (Scheri, Templeton, 2003). The strengths and weakness of physical examinations and EDT along with MRI and CT techniques are discussed in the previous section, with this section highlighting the strengths and weaknesses of ultrasonography.

Ultrasonography and MRI provides a high contrast resolution between the different soft tissues of the body including the nerves and the associated pathologies (Haacke, *et al* 1999) and unlike CT, both technologies do not use X-rays (Chemali, 2005). The estimated cost of ultrasonographic equipment (between £4,000 and £140,000) is relatively less expensive when compared to the estimated cost of CT (ranging from £95,000 to £650,000), and MRI (ranging from £660,000 to £2,000,000). In addition, it is more widely available when compared to MRI and the scanning procedure is quicker (Freedman, Hart, 2003). Furthermore ultrasonographic sound waves are not distorted by ferromagnetic implants and can be used to study patients with metallic pacemakers or cochlear implants for which MRI and CT scans are inadvisable (Hoochman, Zilberfarb, 2004).

Recent advances in the dynamic scanning capabilities of ultrasonographic technology, now allow for non-invasive investigation into superficial anatomical structures during physical movement of the limb or area being scanned. Its real time capabilities permit the imaging of activity as the physical movement happens, to produce a time-motion cine-loop video record of the anatomical activity during the time of the physical movement (Chemali, 2005).

The high frequency transducer probe used in ultrasonographic scanning increases the resolution of the image which makes the technology particularly suitable for the study of

the small superficial structures within the body (Walker, *et al* 2004). However, this increase in frequency results in a decrease in the depth that sound wave penetrates, producing difficulties when imaging deep lying structures, especially in obese patients (Walker, *et al* 2004). In addition, the sound wave is unable to penetrate bone and is therefore not suitable for scanning the human brain. It also performs badly when there is a gas between the transducer and the organ of interest due to the extreme differences in acoustic impedance, for example gas in the gastrointestinal tract making scanning of the pancreas difficult (Hoochman, Zilberfarb, 2004).

However, ultrasonographic imaging is operator-dependent and relies on the technical expertise of the operator to acquire good-quality images when using the equipment and analyzing the results (Walker, *et al* 2004). Proficiency of the procedure requires a good scanning technique and a detailed understanding of the anatomy of the area being scanned and the associated pathologies (Walker, *et al* 2004).

2.2.4. Peripheral nerve ultrasonography

Recent technical improvements in ultrasonography including compound linear array technology, improved computer processing and dynamic imaging capabilities has allowed for the imaging of smaller joints and structures including abnormalities of nerves due to compression/entrapment and specific lesions that may be the cause of pathology. CTS is the most studied peripheral neuropathy (Buchberger, 1997) however, the pathological changes associated with injury in a number of other nerves have also been observed using ultrasound.

The use of high resolution ultrasonography to image peripheral nerves started in the 1980s with a study that aimed to report the normal appearance of the median and ulnar nerves in the upper limb from cadavers and healthy participants (Fornage, 1988). A description of the normal appearance of the nerves was given from longitudinal scans, as linear hyperechogenic structures parallel with hypoechogenic areas (Fornage, 1988) as shown in Figure 2-38.

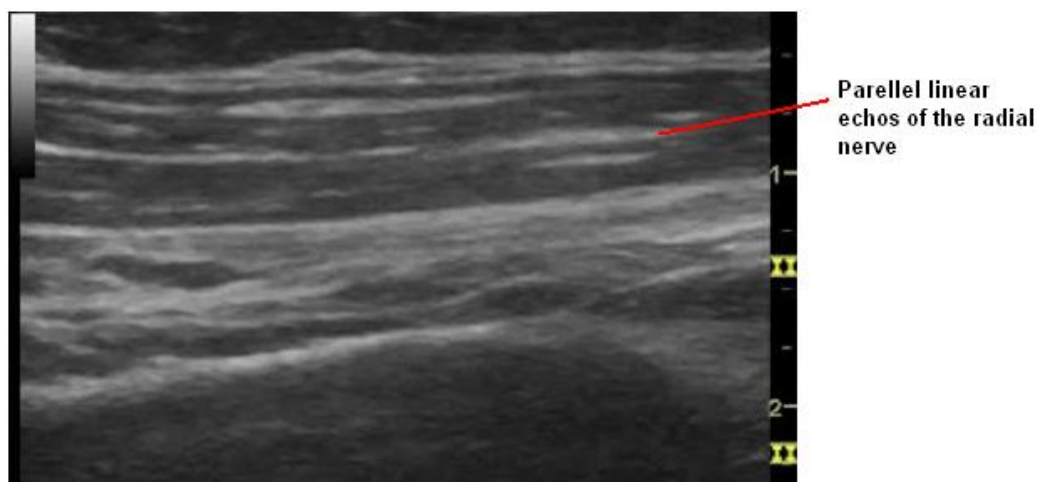


Figure 2-38: Longitudinal sonogram of the radial nerve.

Transverse scans were also described as oval hyperechogenic structures with internal punctuated hypoechogenic areas (Fornage, 1988) as shown in Figure 2-39.

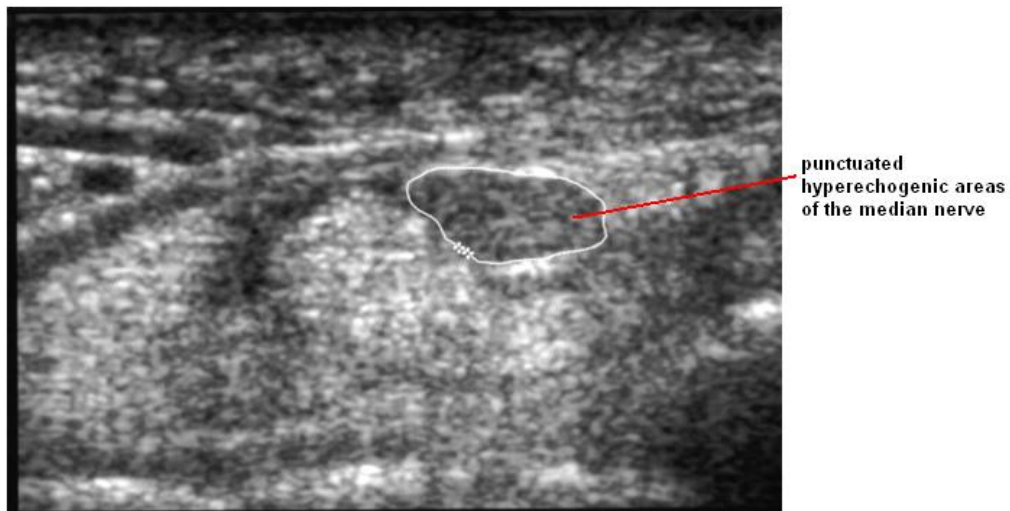


Figure 2-39: Transverse sonogram of the median nerve

The study also differentiated the nerves from the tendons and muscles by their relative inactivity when compared to the other structures during flexion and extension movements of the arm. Grechenig, *et al* (2000) described the same echogenic characteristics as Fornage in the sciatic nerve in the lower limb from healthy participants and reported that the perineurium of the sciatic nerve produced a bright echo at the boundary of the nerve.

In the 1990's, a study that employed fifty healthy participants and 10 patients suffering with hereditary motor and sensory neuropathy, aimed to investigate how well ultrasonography could image peripheral nerves including the radial nerve at the humerus, the ulnar nerve distal to the cubital tunnel, the sciatic nerve in the middle of the thigh and the tibial and common peroneal nerves just distal to their bifurcation (Heinemeyer, Reimers, 1999). The study found that in healthy subjects the ulnar and radial nerves could be identified in all cases, the sciatic nerve in 37 cases, the tibial and peroneal nerves in 10 cases. The average values given for the cross-sectional area of the arm nerves were 3 mm^2 and for the sciatic nerve were 6 to 7 mm^2 . The study stated that ultrasonography allowed

reliable imaging of the major nerves in the upper limb and occasionally, the sciatic, tibial and peroneal nerves in the lower limb. However, no significant differences were seen in nerve size and structure between patients and healthy subjects.

The ulnar nerve crosses the elbow joint within the cubital tunnel, and enters the hand through Guyon's canal. Entrapment or compression of the ulnar nerve at the elbow is known as Cubital tunnel syndrome (CuTS), a condition brought on by increased pressure on the ulnar nerve at the elbow resulting from fractures, ganglion formation and bony projections that form along the joint known as bone spurs (Ellis, *et al* 2002).

A study by Thoirs, *et al* (2007) aimed to test the influence of ulnar nerve measurements when discriminating between 22 limbs that were affected by ulnar nerve entrapment at the elbow and 108 healthy limbs. The study found that that the cross-sectional measurements for area and diameter of the ulnar nerve made at the level of the medial epicondyle could distinguish between healthy limbs and those affected by ulnar nerve entrapment.

Yoon, *et al* (2004) proposed the use of a ratio between the cross sectional area at the site of injury and at an unaffected site on the ulnar nerve to improve the diagnostic accuracy of ultrasonography in CuTS, when compared to a single measurement taken at the site of maximal enlargement of the nerve. The ratio was suggested to reduce the variables arising from individual variations such as the age, sex, weight etc of the participant in the measurements taken by ultrasonography. The study measured the cross-sectional area of the ulnar nerve at three sites in 30 healthy participants and 26 individuals with ulnar nerve entrapment. They found that the ratio data produced values with a sensitivity of 100% (the

proportion of people with the disorder who were correctly diagnosed) and specificity (particularly suited for the use) of 96.7% for the diagnosis of CuTS.

Nerve entrapment within Guyon's canal at the wrist is rare, although specific causes such as ganglia and abnormal muscles can be demonstrated by ultrasound (Ellis, *et al* 2002). Nakamichi and Tachibana (1998) used ultrasonography to study the anatomy of the Guyon's canal at the wrist and imaged a ganglion arising from the joint between the triquetrum bone and the hamate bone in participants with ulnar neuropathy. The study reported that the role of ultrasonography was not only to identify the pathology but also to determine its relationship with other structures in the area.

A study that aimed to determine the capability of ultrasonography to image radial neuropathy caused by a fracture in the humerus was performed by Bodner, *et al* (2001) using 11 patients with radial nerve deficiency after a humeral fracture and 10 healthy participants. The study found that ultrasonography could detect an abrupt change in course of the nerve around the fractured area which was confirmed in 5 patients during surgery.

In the lower limb, the sciatic nerve and its major branches can become compressed or entrapped by a variety of soft tissue masses. Displacement of the nerve from its normal course is the main ultrasound sign but ischial bursitis (inflammation of the hip joint) can also irritate the sciatic nerve, producing compressive-like symptoms (Ellis, *et al* 2002). The peroneal nerve, as it winds around the fibular neck and the tibial nerve, within the tarsal tunnel at the ankle joint, can become compressed or entrapped. This is the result of pathologies that include ganglia, soft tissue tumors, tenosynovitis and fracture deformity.

Schwemmer, *et al* (2005) aimed to evaluate the feasibility of ultrasound in identifying the anatomy of the sciatic nerve and its division into the tibial and peroneal nerves. The study involved 74 participants who were scanned at the popliteal fossa at the back of the thigh and the distance of the joint to the tibial and peroneal nerve division was measured using a caliper. The sciatic nerve and its division were visualized in 53 of 74 (72%) participants and a significant correlation was shown between the width of the knee-joint line and the depth of the nerve division.

2.5. Studies on Ultrasonography and the Median Nerve

There have been a number of studies over the last 20 years that have shown that ultrasonography can provide accurate assessment of the median nerve. For this thesis, a literature review was undertaken using the search engines *ScienceDirect*, *Web of Knowledge* and *Google Scholar*.

The keywords '*ultrasonography*' and '*median nerve*' were put into an advanced search in *ScienceDirect* and 3,839 articles were found which was reduced to 452 when the additional keyword '*work-related upper limb disorder*' was inserted into the *search within field* option. Using the keywords '*ultrasonography*' and '*median nerve*' in the *Web of Knowledge* search engine 556 results were obtained which was reduced to 457 when the term '*work-related upper limb disorder*' was added into the *search within results* option. In *Google Scholar*, 21,400 results were obtained using the keywords '*ultrasonography*' and '*median nerve*'. This was condensed to 2,990 results when the keyword '*work-related upper limb disorder*' was added to the search. In addition, the reference section of papers gave further articles. Although the literature search produced a high amount of research

only a small percentage specifically focused on research with respect to all the terms used, with a number of papers either identifying literature that was concerned with ultrasonography and work related disorders of other nerves or investigations into median nerve biomechanics using other forms of technology (e.g. electrodiagnostic tests, MRI). Therefore this thesis concentrates on the most relevant literature and is detailed below. At this time, the greatest amount of information on neurological ultrasonography comes from studies into the median nerve and CTS. This could be due to the median nerve being relatively large and superficial at the wrist, making it easy to study using sonographic technology (Walker, *et al* 2004).

The use of high resolution ultrasonography to image peripheral nerves started in the 1980s and since then it has been used to image the median, radial, and ulnar nerves in the upper limb and the sciatic, tibial and common peroneal nerves in the lower limb. Initial studies (Fornage, 1988) used ultrasonography to image peripheral nerves from static images and described the anatomy of the carpal tunnel and the echogenic appearance of the median nerve. These studies were followed by a number of reports that aimed to use ultrasonography to measure the median nerve as a way of objectively assessing any differences between a control group and participants suffering from CTS (Buchberger, *et al* 1992; Nakamichi, Tachibana, 2002; Leonard, *et al* 2003; Altinok, *et al* 2004; Kotevoglou, *et al* 2004; Yesildag, *et al* 2004). Table 2.3 shows the data obtained from all of the relevant studies for cross sectional area and/or flattening ratio and their corresponding statistically significant values for non symptomatic (controls) and participants (patients) with CTS. The cross-sectional area and flattening ratio values are given in this table because they are the most commonly reported measurements directly concerning the median nerve.

Table 2.3: The reported mean and SD values for cross-sectional area and flattening ratio of the median nerve proximal to the carpal tunnel for a control group and a group symptomatic of CTS

Previous Studies	Participant Number controls/patients	Control Group		Patient Group	
		Cross-Sectional Area mm ² (sig value)	Flattening ratio (sig value)	Cross Sectional Area mm ² (sig value)	Flattening ratio (sig value)
Buchberger, <i>et al</i> 1991	28/18	8.1 ± 1.3 (p = <0.001)	3.0 ± 0.5 (p = <0.001)	14.5* ± 3.8 (p = <0.001)	2.7* ± 0.5 (p = <0.001)
Nakamichi, Tachibana, 2002	408/275	9.6 ± 2.4 (p = <0.0001)	-	14.4 ± 2.4 (p = <0.0001)	-
Leonard, <i>et al</i> 2003	20/20	7.8 ±0.7 (p = 0.004)	2.8 ± 0.3 (p = 0.013)	11.6 ± 2.2 (p = 0.004)	3.5 ± 0.4 (p = 0.013)
Altinok, <i>et al</i> 2004	20/40	6.8 ± 1.5 (p = <0.0001)	2.0 ± 0.3 (p = <0.0001)	10.3 ± 2.4 (p = <0.0001)	2.3 ± 0.3 (p = <0.0001)
Kotevoglu, <i>et al</i> 2004	14/24	6.9 ± 0.7 (p = <0.001)	2.0 ± 0.2 (p = <0.001)	15.3 ± 6.2 (p = <0.001)	2.6 ± 0.5 (p = <0.001)
Yesildag, <i>et al</i> 2004	45/86	7.8 ±1.6 (p = <0.001)	2.5 ±0.5 (p = <0.001)	14.9 ± 4.7 (p = <0.001)	2.9 ± 0.4 (p = <0.001)

One of the first studies to measure the parameters of the median nerve using (Buchberger, *et al* 1991) used the data as an assessment for CTS and compared it with measurements obtained from MRI imaging. Transverse static scans were taken from 18 patients and 28 controls and imaged at three levels on the wrist: distal carpal tunnel, mid carpal tunnel at the level of pisiform and proximal to the carpal bone at the level of the hamate bone. Cross-sectional area of the median nerve was calculated indirectly using the ellipsoid formula

$$\text{Area} = \pi (\text{major axis} \times \text{minor axis}) / 4$$

and assumed that the nerve is an ellipsoid shape. In addition, the flattening ratio (a ratio obtained by dividing the nerve's major diameter by its minor diameter) and the bowing of the flexor retinaculum was also calculated.

Sonographic measurements taken for cross-sectional area proximal to the carpal tunnel and flattening ratio in the distal carpal tunnel in the control group were significantly different when compared to the patient group with the median nerve in the patient group showing an increase in cross-sectional area and flattening when compared to the control group. However, the measurements taken for palmer bowing of the flexor retinaculum were less accurate (Buchberger, *et al* 1991).

A number of studies followed this by investigating the accuracy of the methods and measurements proposed by Buchberger, *et al* (1991) (Nakamichi, Tachibana, 2002; Leonard, *et al* 2003; Altinok, *et al* 2004; Kotevoglu, *et al* 2004; Yesildag, *et al* 2004).

A large study was performed (Nakamichi, Tachibana, 2002) to establish the diagnostic accuracy of the cross-sectional area measurement of the median nerve for CTS. The research involved 408 controls and 275 patients with CTS, clinically diagnosed by nerve conduction studies. Cross-sectional area measurements were taken of the median nerve at the three levels proposed by Buchberger, *et al* (1992). However, this study used a continuous boundary trace (an application tool that outlines the circumference of the nerve) and calculated from this was the area and the major and minor axis. The study found statistically significant differences in the size of the nerve's area in patients when compared to the control groups, at all levels but the measurement taken at the level proximal to the carpal tunnel (the distal wrist crease) was found to be more reliable when compared to the other levels. The research concluded that ultrasonographic measurement was a satisfactory objective test for diagnosis of CTS when five repetition measurements or more were averaged.

Further studies were also performed to assess the accuracy of the cross-sectional area and flattening ratio parameters and validated the use of ultrasonography by comparing it to other forms of evaluation. Leonard, *et al* (2003) assessed the accuracy of the measurements for cross-sectional area along with the flattening ratio for the diagnosis of CTS, by comparing 20 participants with a positive Phalen test and 20 controls. While Kotevoglou and Gulbahce-Saglam (2005) undertook a study that aimed at investigating if ultrasound measurements would correlate with the findings from two clinical tests: Phalen test and Tinel sign. The study used 24 patients with signs and a typical history of CTS along with 14 control subjects. Both studies found significant differences between the groups for the cross-

sectional area measurement, which was correlated with the findings from the physical tests. The report produced by Leonard, *et al* (2003) whereas Kotevoglou and Gulbahce-Saglam (2005) concluded stated that the ultrasonographic measurements were a relatively poor predictor of CTS that sonographic measurement of the median nerve is highly predictable for diagnosis of CTS.

Altinok, *et al* (2004) looked at the accuracy of cross-sectional area and flattening ratio measurements for diagnosis of CTS in 40 wrists that had been evaluated by nerve conduction studies as being either mild or moderate cases of CTS and 20 healthy participants. The study found significant differences between the control groups and the groups that contained patients suffering from CTS which correlated with finding obtained from nerve conduction studies. The authors concluded that ultrasonography could play a useful role in the diagnosis of CTS at different levels of severity (Altinok, *et al* 2004).

Yesildag *et al* (2004) investigated the usefulness of ultrasound in 86 patients with CTS with the diagnosis confirmed by electromyography and 45 controls. The study found that cross-sectional area was the most predictive measurement of CTS when compare to the findings from electromyography. The authors concluded that a cut off value of $<10.5\text{mm}^2$ for the cross-sectional area measurement at the level proximal to the carpal tunnel is a useful criterion for diagnosis of CTS.

The variability seen in the mean data between the studies reported in Table 2.3 showed values for cross sectional area ranging from $6.8\text{mm}^2 - 9.6\text{mm}^2$ for the non-symptomatic group and $10.3\text{mm}^2 - 15.3\text{mm}^2$ for symptomatic participants.

Different studies gave mean values for flattening ratio in the non-symptomatic group ranging from 2.0 – 3.0, while the mean values for the symptomatic group ranged from 2.3 – 3.5. The differences in the values in the values obtained for the median nerve between the reported studies introduces challenges for median nerve research and the diagnosis of upper limb disorders, as the difference in the individual values given for the normal and symptomatic nerve are often bigger than the differences between the groups within each study. This variability in data provides no clear cut-off value for a standardized assessment of CTS. There are a number of possible explanations why the reported studies produced such different values including individual characteristics such as age, sex, physical size etc., variations in the severity of the disorders studied or inclusion of a more/less general population.

In some of the studies the specific posture of the participants was not given including whether the participants were sitting, standing or lying down (Buchberger, *et al* 1992; Nakamichi, Tachibana, 2002; Leonard, *et al* 2003; Altinok, *et al* 2004). As the nerve adapts mechanically to small differences in posture or position of the participant, the parameters of the nerve within the carpal tunnel also adapt and change. For example flexion of the elbow or the wrist results in a stretching of the ulnar nerve and a shortening of the median and radial nerves (Butler, 1991). If the participants in each study were in different positions during the scanning process, no matter how small, it would produce the differences in the data obtained.

When comparing the published reports, there are also a number of differences seen in the way data was collected. Some studies used the indirect way of measuring the cross sectional area of the nerve by using the ellipsoid formula (Buchberger, *et al* 1991; Altinok, *et al* 2004). Although this method is easier to execute, calculation of the area from a direct tracing of the cross-sectional circumference is more accurate because the shape of the nerve is not usually a perfect ellipsoid (Yesildag, *et al* 2004). The use of different methods of data collection would inevitably produce different results.

The previous studies undertaken were mostly investigating the diagnostic value of ultrasonography by comparing the parameters of the normal nerve to those obtained from participants symptomatic of CTS (Buchberger, *et al* 1991; Buchberger, *et al* 1992; Nakamichi, Tachibana, 2002; Leonard, *et al* 2003; Altinok, *et al* 2004; Yesildag, *et al* 2004). The studies evaluated raw measurements from static scans and did not involve physical movement of the limb. However two pieces of research by Greening, *et al* (2001) and Erel, *et al* (2003) did investigate median nerve dynamics during physical movement.

The study performed by Greening *et al* (2001) investigated 12 participants suffering from non-specific arm pain alongside 16 controls and reported on the median nerve during wrist movement, starting at neutral, through to 30° extension and 30° flexion. The location of the nerve was measured at the start and the end of each movement, relative to markers placed on the anterior surface of the wrist and while the participants were in a supine position. They found that the median nerve was 4.8 (± 0.42) mm more radial at 30° flexion than at 30° extension in the control group

whereas in the symptomatic group the nerve moved significantly less with a $1.2 (\pm 0.5)$ mm difference between 30° extension and 30° flexion (Greening, *et al* 2001).

The authors concluded that ultrasound imaging may be helpful in understanding non-specific arm pain and that the reduced movement seen in the median nerve in symptomatic participants was confirmed in findings from previous studies that used MRI. However the study did not attempt to look at the change in cross sectional area or flattening ratio values between the start and end positions of the movements.

The study performed by Erel, *et al* (2003) measured longitudinal sliding and transverse movement of the median nerve in 18 control participants and 17 participants symptomatic of CTS during extension of the metacarpalphalangeal joint from 90° flexion to neutral (when the fingers line up with the palm to create a flat hand), while the participant was in a supine position. They found that there was very little difference in the values obtained for longitudinal sliding of the nerve between the control group (2.26 ± 0.15 mm) and the symptomatic group (2.20 ± 0.21 mm) and that these values were not statistically significant.

From transverse scans, movement from extension to neutral resulted in a mean value for radial nerve movement of 1.6 ± 0.24 mm in the control group, and 0.9 ± 0.89 mm for the symptomatic group (Erel, *et al* 2003). Although this represented a 43% reduction in transverse nerve movement in the symptomatic group when compares to the control group the reduction was not significantly different ($p = 0.08$). The study also gave results on the change in flattening ratio and found that for the control group the nerve was significantly more rounded in a neutral position (with a flattening ratio

of 2.00 ± 0.05) when compared to metacarpalphalangeal flexion (2.48 ± 0.13 $p = < 0.05$). The value obtained from the control group in the neutral position was also significantly different to the value obtained for the symptomatic group (2.29 ± 0.03 $p = < 0.05$) in the same position and represented a 34% greater flattening for the symptomatic group when compared to the control group.

The authors concluded that because there was no longitudinal sliding of the median nerve in CTS patients when compared to the control group, the symptoms of the disorder could not be attributed to an increase in nerve strain along the nerve. However, they did suggest that the decrease in transverse nerve movement in CTS patients resulted in the increase in flattening ratio due to the nerve failing to move away from the flexor tendons and remaining under pressure. The authors implied that this could be explained by local nerve injury which may be sufficient to cause the pain and impairment associated with CTS.

Both of the previous studies obtained measurements from participants while in a supine (lying down) position and studied simple hand and wrist movements. This was considered appropriate for the comparison of normal median nerve activity with that found in symptomatic participants for the purpose of diagnosing upper limb disorders. However to investigate median nerve activity during functional hand activity, a seated position using more purposeful movements is likely to produce more realistic results that can be related to work-related behaviour and contribute to knowledge on the dynamics of the median nerve and the differences seen in the symptomatic nerve.

At this present time when reviewing the published literature, no other studies could be found that used high resolution ultrasonography to quantify the changes in cross-sectional area, flattening ratio or the location of the median nerve within the wrist, throughout functional hand activity.

2.6. Overview of the Literature

The purpose of the literature review was to gain an understanding of the anatomy of the hand and wrist and its function during upper limb movement and to become familiar with the existing studies on the subject of WRULDs, ultrasonography and the median nerve.

The background material of the chapter aimed to illustrate the complexity of the anatomy and function of the hand and wrist along with the infinite variety of configurations that can be used in both gross work and for precision movements. The literature showed that movement of the hand involves stability of the longitudinal arches, activity in the joints, muscles, tendons and ligaments, along with sensory input by the nerves to all points of the hand. The anatomical and functional details of the median nerve were considered, as it is critical for fine motor hand function concerning both motor and sensory supply and is the only one of the three nerves in the upper limb that travels through the carpal tunnel and is implicated as being involved in WRULDs such as CTS.

The review has also aimed to show the problem of WRULDs including their incidence and prevalence and their effect on the individual, industry and society as a

whole through costs derived from loss of wages, disruption in productivity, health care and sick leave (Punnett, Wegman, 2004). The work activities cited by the literature as occupational risk factors include rapid work pace, repetitive motion patterns, forceful manual exertions, non-neutral body postures, vibration, exposure to cold temperatures and insufficient rest and physiological recovery time (Hagberg *et al* 1995; NIOSH, 1997; Malchaire *et al* 1997; Punnett, Wegman, 2004).

A number of WRULDs were explained including those that affect the peripheral nerves. CTS is a result of median nerve compression within the carpal tunnel and is the most commonly studied nerve disorder of the upper limb. It is characterized by pain and numbness in the distribution area of the median nerve and results in inflammation and a reduction in the conduction velocity of the nerve's signal (Tanaka, McGlothlin, 1993). Diagnosis of CTS has been traditionally based on physical examination using techniques such as Tinel's test and Phalen's sign and electrodiagnostic testing involving both nerve conduction studies (NCS) and electromyography (EMG). However, imaging of the median nerve and other soft tissue in the upper limb, along with some of the pathological changes found in WRULDs can now be achieved using MRI, CT and high resolution ultrasonography.

The review summarized examination and imaging techniques used to study WRULDs and specifically detailed the strengths and weaknesses of ultrasonography. It showed that ultrasonography can give information that is lacking in electrodiagnostic testing such as the nature and extent of the disorder. When compared to MRI it is quicker, more portable, relatively less expensive and more widely available and it is safer than CT scans which use ionizing radiation (Chemali, 2005). Ultrasonographic sound

waves unlike MRI scans are not distorted by magnetic implants and do not effect metallic pacemakers or cochlear implants. Moreover, recent advances in ultrasonographic technology allows for information to be obtained on the activity at an anatomical level during physical movement, due to its real time dynamic scanning capabilities (Chemali, 2005). Table 2.4 shows a comparison of the different imaging technologies available in today's market.

Table 2.4: Comparison of different imaging technologies

Imaging technology	Principal modality for imaging	Resolution of soft tissue in the carpal tunnel	Ability to measure structures within the carpal tunnel	Dynamic imaging capabilities during physical movement of the hand	Radiation exposure	Time taken for scanning (approx.)	Cost (estimated)
CT	X-rays	Limited	No	Limited	Moderate - high	5 minutes	£95,000-£650,000
MRI	Electro-magnetic radiation	High	Yes	Limited	Very little	30 minutes.	£660,000-£2,000,000
Ultra-sonography	High frequency sound waves	High	Yes	Dynamic imaging in real time	No radiation	10-15 minutes.	£4,000-£140,000

The limitations of ultrasonography include its total inability to penetrate bone and it also has difficulties when imaging organs that contain gas due to the extreme differences in acoustic impedance. However it is very useful when imaging soft tissue structures such as tendons ligaments and nerves. The depth that the sound wave penetrates is limited and depends on the frequency of the transducer. This can produce difficulties when imaging deep lying structures especially in obese patients, although for superficial structures such as the median nerve within the wrist ultrasonography can produce high contrast resolution images. In addition, ultrasonographic technology is operator-dependent and relies on the technical expertise of the user to operate the equipment, acquire good-quality images and analyze the results.

Research into ultrasonographic imaging of the median nerve in participants with CTS, has indicated that a larger cross-sectional area at the level of the distal wrist crease (mid level) is diagnostic of CTS along with an increase in the flattening ratio. However when comparing studies, there are considerable differences in the values obtained for cross-sectional area and flattening ratio, resulting in no clear cut-off value for the diagnostic assessment of CTS using ultrasonography.

This review suggested explanations as to why the reported studies produced such different values for the measurement of the median nerve. This included general variations in the severity of the disorders studied or inclusion of a more or less general population and differences in the individual characteristics such as age, sex, physical size etc. of the participants involved in each study.

The use of different methods of data collection could have been a contributing factor in the production of the different results with a number of studies using the indirect way of measuring the cross sectional area of the nerve by using the ellipsoid formula (Buchberger *et al* 1991; Altinok *et al* 2004) and some using a direct tracing of the circumference of the nerve (Nakamichi, Tachibana, 2002; Leonard, *et al* 2003; Kotevoglou *et al* 2004; Yesildag, *et al* 2004). In addition, in the posture of the participants would have contributed to the variability of the results. To be able to compare results between independent studies a standard methodological approach is needed that establishes scanning technique, data collection and analysis.

The literature review also discussed research using the dynamic imaging capabilities of ultrasonography. Greening, *et al* (2001) used ultrasonography to measure the median nerve during wrist movement and found that the median nerve in the symptomatic group moved significantly less in a radial direction during movement of the wrist when compared to the control group. Erel, *et al* (2003) measured movement the median nerve during extension of the metacarpalphalangeal joint from 90° flexion to neutral. The study found less radial nerve movement of the nerve for the symptomatic group when compared to the control group and the nerve becoming more flattened in a neutral position in the symptomatic group when compared to control group. The authors concluded that the smaller movement and flattening of the median nerve implied local nerve injury within the wrist which might have been sufficient to cause the pain and impairment associated with CTS.

Both Greening, *et al* (2001) and Erel, *et al* (2003) obtained measurements from participants while they were lying down and studied simple hand and wrist

movements at the start and end positions. However to investigate median nerve activity throughout purposeful hand activity, a seated position is likely to produce more realistic results that can be related to work-related behaviour. Additionally, further measurements that analyze the nerve throughout the activity and not just at the start and end positions of the movement are needed to establish the true extent of normal nerve activity during movement and the difference in symptomatic nerve.

No other study could be found when reviewing the published literature that had used high resolution ultrasonography to calculate the changes in cross-sectional area or flattening ratio during the progress of the median nerve throughout physical hand movement that relates to working behaviour. Therefore, a method for collecting, quantifying and analyzing median nerve activity during physical movement has to be established to acquire data that could be comparable between the participants from each study and between different studies. This includes selecting an appropriate posture and physical movements that are related to working activities and can be easily replicated between individuals, acquiring an accurate way of collecting ultrasonographic scans during movement and a quantification method that can measure the changing parameters of the median nerve from dynamic ultrasound scans.

3. Aims and Objectives

Recent advances in ultrasonographic technology now allows for the dynamic imaging of peripheral nerves and other soft tissue structures in real-time, during physical movement including the anatomical activity of median nerve within the carpal tunnel. This has the potential to allow the experimenter to observe and quantify median nerve activity during movement of the hand, as it happens or for future analysis. However, the real-time dynamic imaging capabilities of ultrasonography have yet to be fully exploited by researchers in relation to median nerve dynamics and the pathology of the associated WRULDs.

WRULDs is a term that covers a broad range of musculoskeletal injury and affect many people in the industrial world who perform repetitive, labour intensive work (Punnett, Wegman, 2004). The most commonly studied WRULD is CTS, a median nerve disorder that occurs when the nerve gets compressed at the wrist and ceases to function properly (Tanaka, McGlothlin, 1993). However, the full etiology and pathology of each type of WRULD including CTS is still not completely understood.

A number of studies have imaged the median nerve in the carpal tunnel using high resolution ultrasonography (Buchberger, *et al* 1991: 1992; Nakamichi, Tachibana, 2002; Leonard, *et al* 2003; Altinok, *et al* 2004; Kotevoglou *et al* 2004; Yesildag, *et al* 2004). Although, the research indicated that an increase in the cross-sectional area and a flattening of the median nerve could be used to diagnose CTS, the values obtained for the normal nerve and those for the nerve symptomatic of CTS have been variable and there is no general consensus on the cut-off values for a standardised assessment of the normal or symptomatic nerve using ultrasonography.

Therefore, the primary aim of this study was to use high resolution ultrasonography to study the median nerve during simple but purposeful hand movement. The objectives used to achieve the aim were to:

- Establish the most appropriate ultrasonographic techniques for the dynamic imaging of the median nerve during functional hand movements
- Establish a analytical method to quantify the changing parameters of the normal functioning median nerve during movement
- Use the method to quantify the symptomatic median nerve within the wrist during functional hand movement
- Use the quantification method and the ultrasonographic technique to distinguish the changing parameters of the normal functioning median nerve and the symptomatic nerve.

High resolution ultrasonography is a low cost, easily available, non-invasive imaging technique that is ideal for the study of relatively large, superficial structures and its dynamic imaging capabilities makes it an appropriate technical tool for this study.

However, because the dynamic imaging capabilities of ultrasound is a relatively new application in the study of median nerve dynamics, a technique needed to be established for accurate scanning at the anatomical level during physical movement of the hand. The technique was required to produce clear, identifiable and synchronised images of the median nerve throughout the movement for each participant, in order for the data to be comparable across the study. Development of an accurate scanning technique of the wrist and recognition of the normal ultrasonographic appearance of the nerve and the surrounding anatomy was acquired during training and practice sessions.

In parallel with this, an analytical method was needed to produce quantitative measures of the size, shape and position of the median nerve within the carpal tunnel during physical movement of the hand. This was needed to establish normal median nerve activity throughout movement and to investigate if the ultrasonographic technology and the proposed methodology could identify any differences between participants with normal neural function and those with symptomatic symptoms. A methodology that could be used to record and quantify median nerve dynamics during the execution of the hand activity was then developed and assessed through a pilot experiment. Figure 3-1 gives an overview of the research programme that was undertaken.

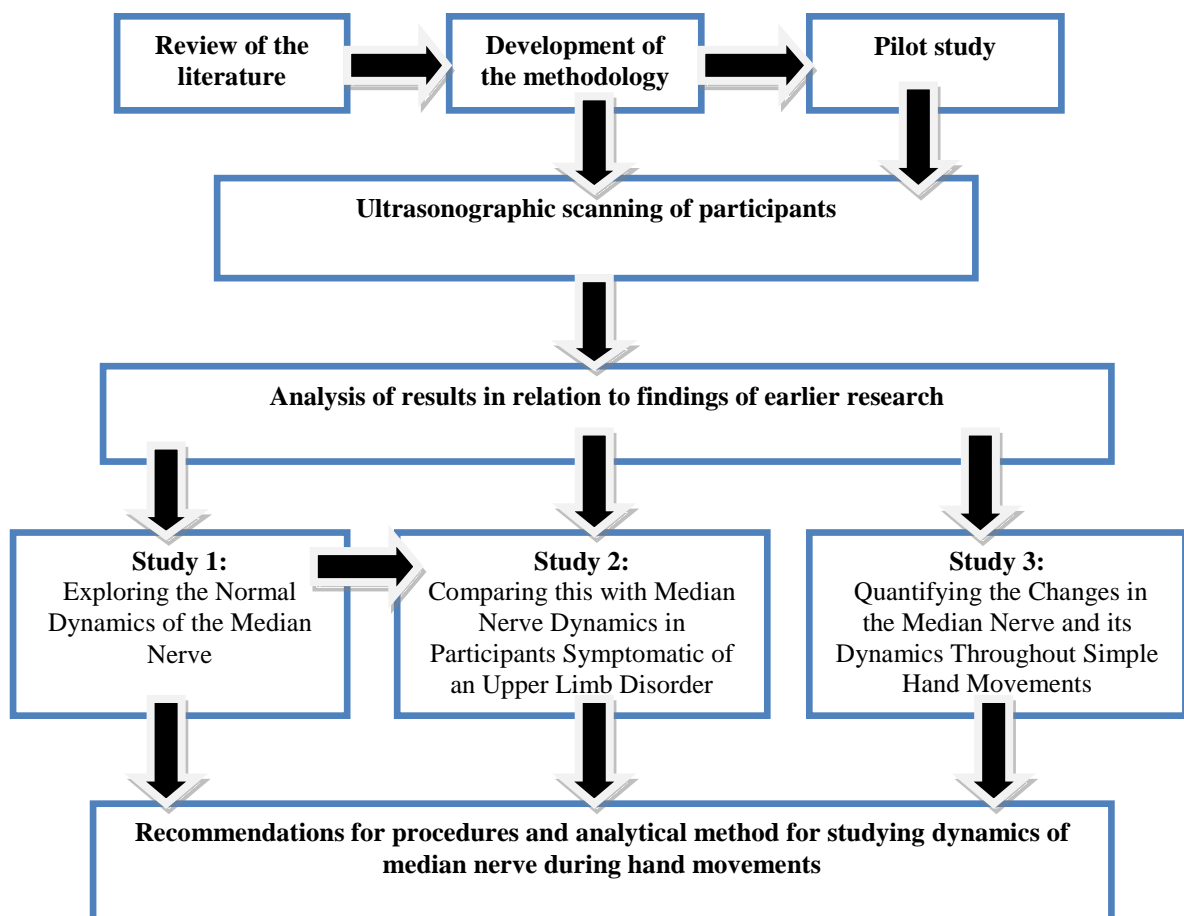


Figure 3-1: Overview of research programme

Once the methodology had been developed, and assessed in the pilot experiment and consequently improved, three experimental studies were conducted.

Study 1 Exploring the Normal Dynamics of the Median Nerve, aimed to investigate whether dynamic ultrasonographic imaging could be used to quantify normal median nerve activity between the start and end positions of four simple but purposeful hand movements. The objective of this study was to provide base-line data for normal median nerve activity during simple hand movements.

Study 2 Median Nerve Activity in Participants Symptomatic of a Median Nerve Disorder, aimed to quantify the change in the parameters of the median nerve during hand activity in participants symptomatic of a median nerve disorder. The objective of this study was to identify whether dynamic ultrasonographic imaging techniques, along with the quantification process, could distinguish any significant difference in median nerve activity between the normal and symptomatic nerve. Making a distinction between the two groups can contribute to the biomechanical knowledge of the median nerve activity during movement and could potentially suggest an explanation as to what is happening at an anatomical level in symptomatic nerves.

Study 3 Quantifying the Change in the Median Nerve Throughout Simple Hand Movements aimed to establish the changing pattern in the parameters of the median nerve at five intervals during physical movement of the hand. This would provide information on the changing activity of the median nerve as it progresses through the movement (not just the overall change). It was intended to conduct this study with both normal and symptomatic participants to investigate the possibility of identifying

any significant difference between the non-symptomatic and symptomatic groups for the purposes of contributing to knowledge on the normal dynamics of the median nerve and the contrast with the symptomatic nerve.

The data obtained from the studies has the potential to add to the existing knowledge of the median nerve and hand function by initiating a technique that can quantify the changing parameters of the nerve throughout purposeful movement and distinguish the anatomical behaviour between the normal functioning median nerve and a nerve symptomatic of a disorder.

4. Development of the Methodology

The aim of this chapter is to describe how the methodology used in the experimental studies was developed and discusses the specific ultrasound equipment and the practical experience needed to obtain and analyze the sonographic images. A pilot experiment was performed and the methods and results are discussed in relation to the procedures to be taken forward to be used in the main set of experimental studies.

Figure 4-1 gives an overview of the chapter.

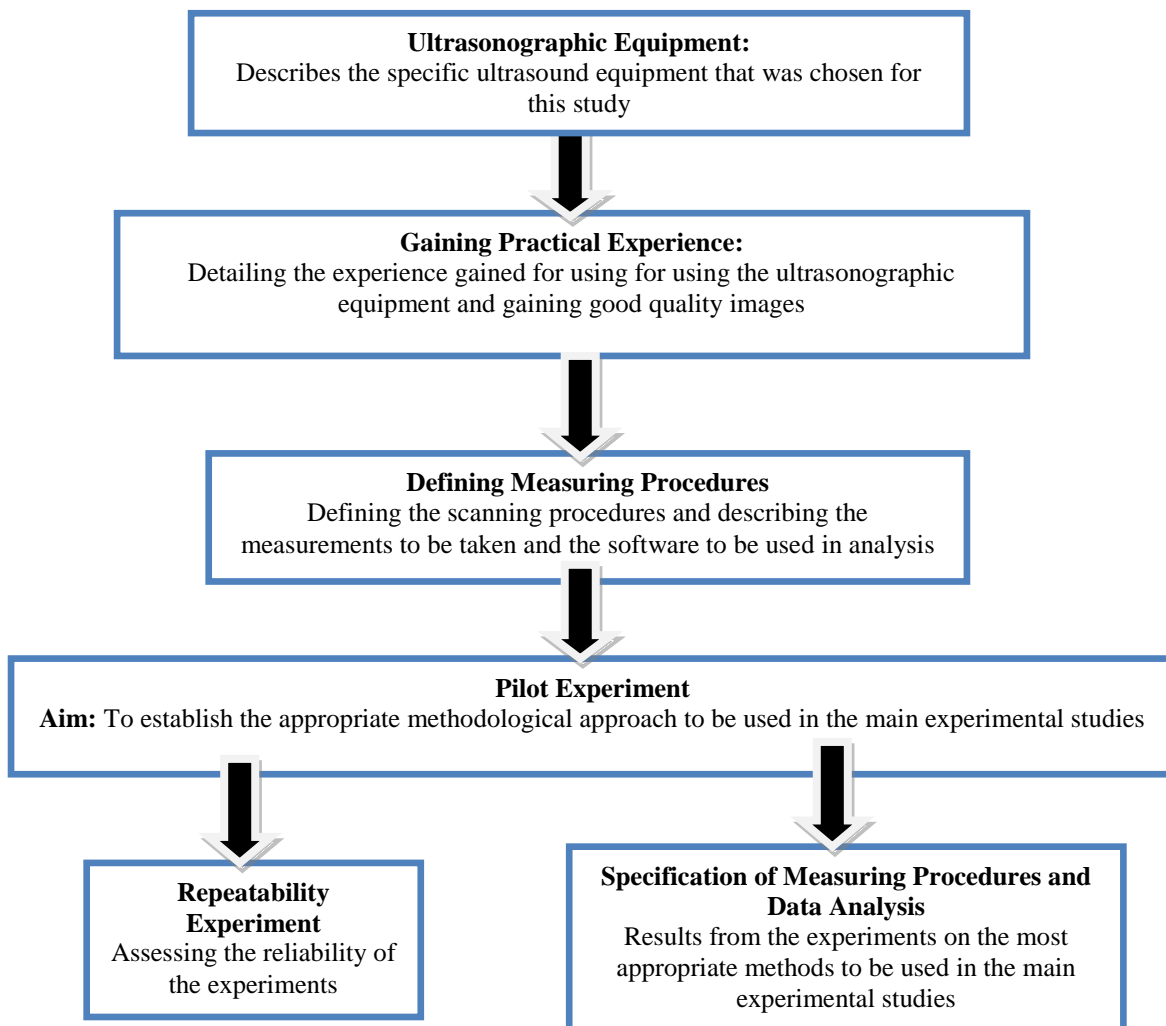


Figure 4-1: Overview of the development of the research

4.1 The Ultrasound Equipment

Chapter 2, section 2.3 discussed imaging technologies that could also be used in the study of the median nerve within the carpal tunnel and compared these to the characteristics of ultrasonographic technology detailed in *Chapter 2, section 2.4* to show why ultrasonography is the ideal tool for this study. One of the most commercially available and widely used ultrasonographic systems is DIASUS (Dynamic Imaging Application Specific Ultrasound) manufactured by Dynamic Imaging Livingston UK which was employed in all the experimental studies reported in this study.

DIASUS is an application specific ultrasound system whose purpose and function is to a certain range of clinical applications which are quite different from the more conventional obstetric, radiology, or echocardiography systems. The DIASUS ultrasound machine was purposely designed for applications requiring the highest resolution imaging of the anatomy of the musculoskeletal system and can reveal the detail of soft tissue anatomy including muscles, ligaments, tendons and nerves.

DIASUS is a B-mode pulse echo imaging ultrasound machine. The B-mode (brightness mode) display has a depth of view of 100mm (maximum) which produces a bright reflection of the returning echoes from the structures lying in the path of sequential pulses echoes. The DIASUS computer then processes the returning echoes and reconstructs an image of the structures being scanned onto a monitor. Figure 4-2 shows the DIASUS ultrasound machine used in this study.

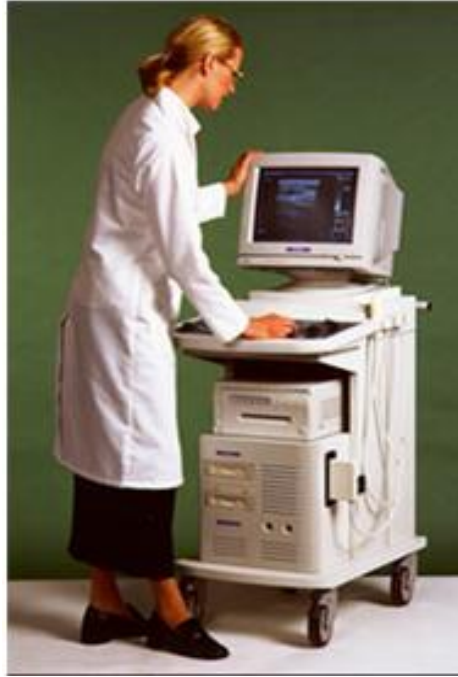

Figure 4-2: DIASUS ultrasound machine

DIASUS is compatible with both 5-10 MHz and 8-16MHz transducer probes but the 8-16MHz high frequency transducer was used in this project because it allows for the maximal contrast resolution (640 X 480 Pixels) of small and superficial structures within the wrist.

The equipment continuously records the previous five-seconds of ultrasound frames at the rate of 30 frames per second. This can be replayed back in what is known as a time-motion cine-loop recording. The cine-loop can record dynamic anatomical activity during physical movement of the area being scanned and the recording can be exported as Bitmaps to other computer devices and analytical software programs.

While playing back a cine-loop sequence any frame can be frozen and displayed on the monitor with the trackerball being used to move through the cine loop recording frame-by-frame, backwards or forwards. The chosen frame can be annotated while the

cine loop is paused and distance and area measurements can be taken using the trackerball to move the onscreen cursor. However these will be deleted once another frame has been chosen and displayed on the monitor.

The main characteristics of the DIASUS ultrasound equipment are detailed in Table 4.1 with a detailed description of the measurements that are available using DIASUS given in a following section.

Table 4.1: Characteristics of the DIASUS ultrasound equipment

DIASUS	Specifications
Scan mode	B Mode Cine Loop- 5 seconds
B Mode features	Depth of view- 100mm (max.) Frame rate 30- frames/second (max.) Magnification- 6 step zoom
Resolution	640 X 480 Pixels, 8 bits
Probe frequency (active length)	5-10 MHz (40mm) 8-16MHz (26mm)
Interface	Slide potentiometer* gain control e.g. brightness, contrast, etc Trackerball for measurement positioning QWERTY keyboard with function keys Colour monitor
Software measurements	Distance (mm) Traced (mm ²) Ellipse area (mm ²)
Export of images	TIFF, GIF, JPEG, BitMap

*An instrument for measuring with adjustable controls, widely used for volume control in radio and television receivers

4.2 Gaining Practical Experience

This thesis involved a certain amount of practical experience to acquire high-quality sonographic images, distinguish the anatomical structures and their physiology and obtain precise measurements of the median nerve. Practical experience concerning the use of the ultrasonographic technology included the use and maintenance of the technology and troubleshooting any problems that may occur. This was acquired by attending training and practice sessions during the 1st year as a post-graduate and was a pre-requisite to the experimental studies.

Hands on experience of the ultrasound equipment started with lab-based training sessions performed by a fellow researcher and an academic who were experienced in the use of ultrasonography. This included a demonstration on the proper operation of the ultrasound machinery to make adjustments to the controls and on positioning the transducer probe to obtain an adequate image quality. The training sessions were followed by a large number of practice sessions which refined the knowledge already acquired and provided experience in obtaining measurements using the trackerball to position the cursor onto the area being measured which involved a certain degree of hand-eye coordination. A great amount of time was invested in the practice sessions as they were a vital component in acquiring the experience to obtain good, clear sonograms.

The study of both anatomy and physiology of the upper limb was mainly obtained during the literature review however practical experience was also acquired during a number of sessions in the dissecting room in the Queen's Medical Centre,

Nottingham. This involved a study of the forearm, hands and wrist in cadavers and allowed for hands-on experience of physiology and anatomy.

In addition while attending practice sessions on the ultrasonographic equipment, the sonographic appearance of the anatomy within the carpal tunnel became familiar along with the physiology during dynamic imaging. Correct identification of the median nerve was established by the movement of the participant's thumb toward the base of the middle finger, resulting in considerable nerve movement within the carpal tunnel when compared to the flexor tendons.

An explanation of the procedure and how the study would be performed was needed before starting the study not only for the participants but also the ethical review board. This included a concise and simplified explanation of acoustic physics which was acquired from specialised books on ultrasound physics, along with an understanding of the workings of ultrasound technology obtained from the handbook provided by the manufacturers and specialised books on ultrasonographic technology.

4.3 Defining Measuring Procedures and Data Analysis

This section describes the measurements used to study the median nerve and the analysis software to be used in the pilot study.

4.3.1 The Measurements

The chosen parameters measured were decided upon during the practice sessions with the ultrasonographic equipment and were based on those set out by Buchberger *et al*

(1992) whose study is detailed in *Chapter 2* in section 2.5 *Studies on Ultrasonography and the Median Nerve*. The study found significant differences between a control group and a group symptomatic of CTS in the measurements taken for the median nerves cross-sectional area and flattening ratio. Measurements were also taken for palmer bowing of the flexor retinaculum in the wrist but no significant differences were found in this measurement. A number of studies have followed the methodology proposed by Buchberger, *et al* (1992) and validated the usefulness of the cross-sectional area and flattening ratio parameters (Nakamichi, Tachibana, 2002; Leonard, *et al* 2003; Altinok, *et al* 2004; Kotevoglou, *et al* 2004; Yesildag, *et al* 2004).

Greening, *et al* (2001) and Erel, *et al* 2003 performed studies that are detailed in *Chapter 2* in section 2.5 which introduced location of the nerve within the wrist as a parameter for the measurement of the median nerve. It seemed logical for a study investigating dynamic scanning procedures that location as a parameter should be measured, and was therefore considered as a parameter for the pilot experiment although, this study proposes a novel analysis method different from that proposed by Greening, *et al* (2001) and Erel, *et al* 2003.

Other structure in the wrist were considered for investigation such as measuring the area of the carpal tunnel as a whole and the tendon bulk. This required good distinct images that clearly defined the edges of the structures to be measured. However, it became apparent during the practice sessions that the edges of the tendon bulk could not always be identified clearly and that the entire carpal tunnel space could not always be captured by the small transducer head especially in participants with a larger wrist size. Therefore these parameters were rejected for this study.

4.3.2 On-line and off-line analytical software

DIASUS ultrasonographic equipment has the ability to obtain measurements on-line, using its own internal software programme or allowing the images to be exported in the form of Bitmaps for off-line analysis using alternative analytical software.

Therefore procedures for measuring and analyzing the sonographic images had to be established from either on-line or off-line software programme.

The ultrasonographic equipment continuously records the previous five seconds of ultrasound frames, which can be replayed back in a time-motion cine-loop recording. On-screen measurements using Dynamic Imaging Software (version P7.03. 2001) can be taken from any frame once the cine-loop is paused. However the measurements are deleted when a new frame is chosen and therefore all measurements taken using the DIASUS software needs to be taken at the time of scanning. The measurements were taken using a keyboard interface and included the tracker-ball to move the on-screen cursor, the straight line measurement tool, the free hand trace tool and the predefined ellipsoid shape tool. The keyboard interface applications are described in detail below.

The straight line measurement tool is used to measure the distance between two points. In this study it was used to measure the longest (major) and shortest (minor) axis of the median nerve by positioning the pointer at one point on the nerve and then moving it to the second point. Figure 4-3 is a sonogram of the wrist showing the median nerve and the major and minor axis obtained from the straight line tool.

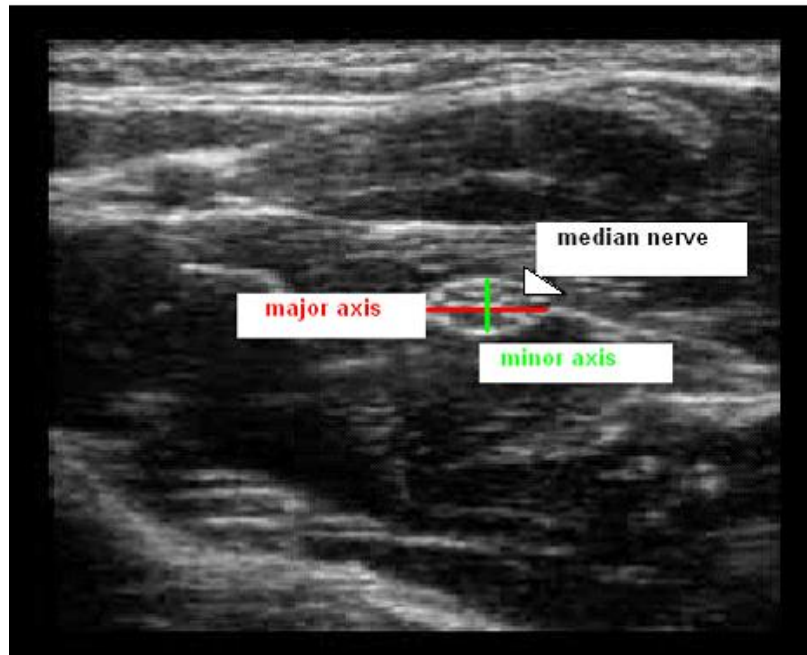


Figure 4-3: The major and minor axis measured with the straight line tool

A measurement for the flattening ratio of a structure can be calculated from the major and minor axis by dividing the major axis by the minor axis. This measurement gives an indication of the shape of the structure being scanned, with higher values suggesting a relatively more flattened shape and lower values suggesting a rounder shape.

The free hand trace tool was used to outline the contours of the median nerve by moving the pointer around the nerve until it returned to its start position, with the analytical software automatically calculating the circumference of the nerve and its cross-sectional area. Figure 4-4 shows a sonogram of the median nerve and the outline of its circumference.

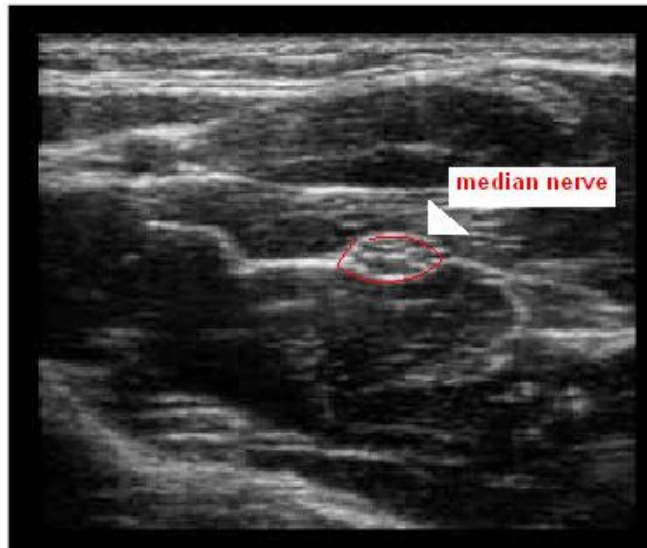


Figure 4-4: outline of the circumference of the median nerve

The predefined ellipsoid tool also gave a measurement of cross sectional area by automatically overlaying an ellipsoid shape onto the nerve (this tool assumes that the nerve is ellipsoid in form). The measurement was acquired by positioning the pointer at one end of the nerve, then moving it to the other end along its major axis and using the tracker-ball to open and close the ellipsoid shape until the required size was obtained. Figure 4-5 illustrates the ellipsoid shape overlaying a sonographic image of the median nerve.

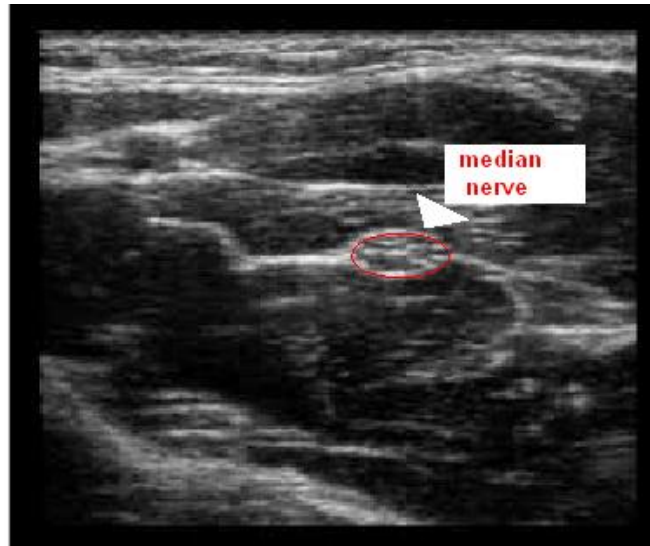


Figure 4-5: The ellipsoid shape tool overlaying the median nerve

Off-line analysis was performed using Scion Image Processing software package which is the Windows version of the Macintosh programme written by the National Institute of Health in Maryland (USA). Scion is a Java-based image program that can acquire, display, edit, enhance, analyze and animate 8-bit, 16-bit and 32-bit images including sonograms. It can read many image formats including TIFF, GIF, JPEG and Bitmap and it can calculate area, circumference, the centre of an object of uniform density, the pixel value and light intensity of defined selections of the image. Scion can take edge-to-edge measurements of distances and can produce X co-ordinate (mediolateral axis) and Y co-ordinate (anteroposterior axis) values giving positional data concerning the centre of a structure (Girish, Vijayalakshmi, 2004).

It supports many standard image processing functions, including contrast enhancement, density profiling, smoothing, sharpening, and edge detection of defined areas. A tool palette supports editing of colour and gray scale images, including the

ability to draw lines, rectangles, ellipses and text and it can flip, rotate, invert and scale selections (Girish, Vijayalakshmi, 2004).

For the measurement of small structures using Scion, a calibration was needed. This was achieved by calculating the number of pixels contained in a straight line of a known distance. After this calculation was made the resolution scale was set at 10.7 pixels/mm.

A continuous trace measurement of the circumference of a structure allows the Scion software to automatically calculate the cross-sectional area, the length of the major and minor axis and the X- and Y- co-ordinates giving the location of the structure along the mediolateral and anteroposterior axes, respectively.

The X and Y co-ordinate measurement obtained from Scion were not attainable from the DIASUS software package. It defines the position of the centre of the structure selected from the circumference trace and gives a value for its position along a horizontal mediolateral axis (X co-ordinate) and along an vertical anteroposterior axis (Y co-ordinate). Figure 4-6 is a diagrammatic representation of the median nerve and shows the anteroposterior plane and the mediolateral plane.

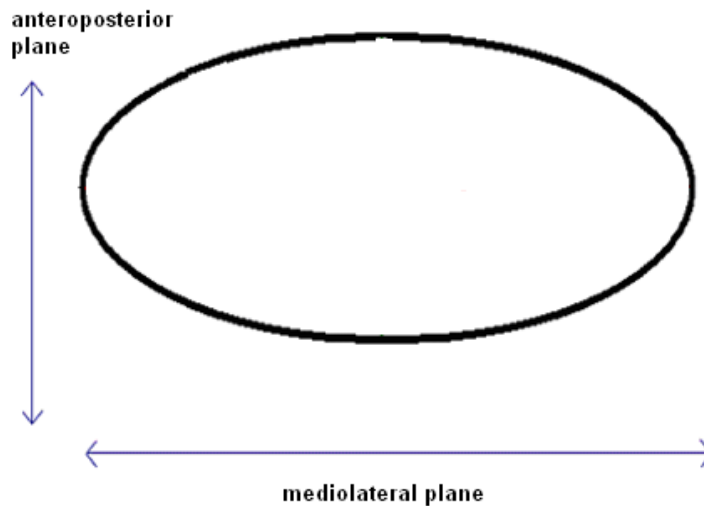


Figure 4-6: The planes of the median nerve

Scion directly supports any number of images simultaneously including those capturing cine loop recordings produced from DIASUS ultrasound equipment. It is free to download and can be run as an online applet or a downloadable application onto any computer (Girish, Vijayalakshmi, 2004).

Scion is a little more complex than other programs to set up and use. It can be a cumbersome and slow process to acquire measurements especially when measurements are from multiple images because every image opened also opens an additional text window, which will also then need to be saved and closed. Some operations such as resizing and cropping are not intuitive. Scion opens all images full size, which can be awkward with larger images, while taking multiple steps to enlarge smaller images (Eliceiri, Rueden, 2005).

4.4 Pilot Experiment

The normal appearance of the median nerve in the area of the carpal tunnel was explored in a pilot experiment that involved only one subject. The aim was to establish the ideal position on the wrist for the scanning procedure to take place, to assess the software packages supplied by DIASUS and Scion for accuracy and convenience and to refine methodological techniques involved in the design and execution of the main experimental studies.

4.4.1 Scanning process

The scanning process was conducted with the subject in a supported sitting position as shown in Figure 4-7. Static scans were taken of the right arm which was flexed 90° at the elbow and rested on the arm of a chair, with the anterior surface of the palm facing upwards. The wrist was in a neutral position (no deviation in a radial or ulnar direction) with the digits relaxed, and the whole upper limb position splinted with Velcro straps around the forearm and the fingers to prevent significant movement.

The seated posture was chosen because it is a novel position for ultrasonographic study of the median nerve with most of the previous research choosing a supine posture and it is a position that many individuals employ during their working life. The upper limb position was an easy posture to attain and hold throughout the experiment, easing the discomfort of long experimental procedure and reducing variability between each trial.



Figure 4-7: Position of the participant during scanning

Transverse scans of the wrist were taken using the procedures described in the previous study by Buchberger *et al* (1991) detailed in *Chapter 2* in section 2.5. This involved scanning at the proximal, middle and distal levels on the wrist and allowed for the whole of the median nerve to be imaged and relevant measurements to be obtained. The level proximal to the carpal tunnel was located from the proximal wrist crease on the surface of the lower arm and imaged at the radio-ulna joint. The mid carpal tunnel level was located from the distal wrist crease on the surface of the wrist and the contents of the carpal tunnel including the flexor retinaculum and the pisiform bone were imaged. The level distal to the carpal tunnel was located from images of the distal edge of the flexor retinaculum and the hook of hamate bone. The scanning positions are shown in Figure 4-8.

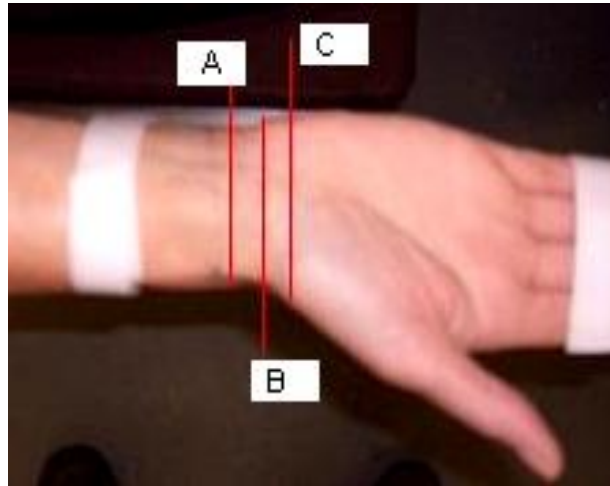


Figure 4-8: Position of the scanning area

The palmer surface area of the wrist was marked at the three positions to be scanned; A. proximal, B. mid and C. distal to the carpal tunnel. This ensured that the transducer was positioned in the same place for each successive image. A liberal amount of transmission gel was applied to the head of the transducer and then placed directly on the wrist perpendicular to the median nerve avoiding any compression that could cause deformation.

Measurements were first taken using the DIASUS's own ultrasound software and consisted of ten repeat trials for each measurement, which were averaged to give the final mean value. The start point for each scan was located by lining up the centre of the median nerve with the central marker located at the top of the ultrasonographic image displayed on the computer screen. At each level, median nerve measurements were taken of the cross-sectional area using the free hand trace and predefined ellipsoid shape, the major and minor axis using the line measurement using the DIASUS software at the time of scanning.

The sonographic images were also exported and analyzed off-line using Scion image processing software. Calculations were obtained by tracing the perimeter of the median nerve around its internal echogenic rim and the Scion software automatically computed measurements for circumference, area, major and minor axis, and X and Y co-ordinate.

4.4.2 Results of the Pilot Experiment

Initial observations were recorded about the local anatomy at each level and measurements were taken from ten trials in succession of each other, starting proximally followed by the middle and the distal measurement.

The first image was acquired proximal to the carpal tunnel and can be seen in Figure 4-9. The median nerve appeared roughly oval in shape and could be seen immediately superficial to the flexor tendons. It was surrounded by a thin echogenic rim and contained hyperechoic (lighter areas) spots distributed within a hypoechoic (darker areas) background. The tendons could be seen as more echogenic relative to the median nerve and the border of the lunate within the proximal row of the carpal bones and the radius were visible.

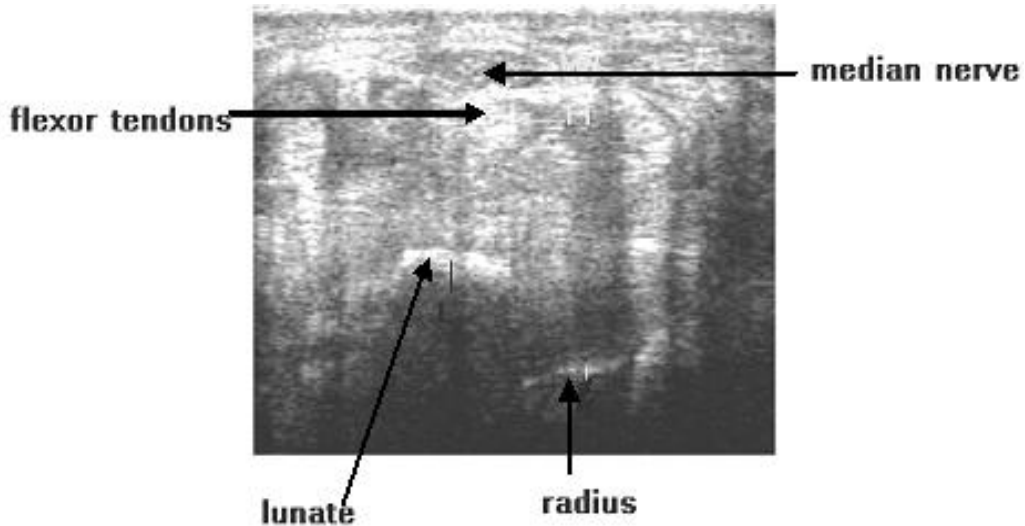


Figure 4-9: Ultrasonographic image proximal to the carpal tunnel

The second image acquired was from the middle of the carpal tunnel at the level of the pisiform bone and can be seen in Figure 4-10. The major axis of the median nerves ran parallel with the flexor retinaculum which was seen as bowed echogenic bands that span the anterior surface of the carpal tunnel, superficial to the nerve. The nerve's echogenic rim was clearly visible and the internal echo had a mottled appearance with the hyperechoic rounded areas seen within hypoechoic regions. The flexor tendons were once again more echogenic than the nerve and the proximal border of the capitate bone could be seen in the distal row of the carpal tunnel.

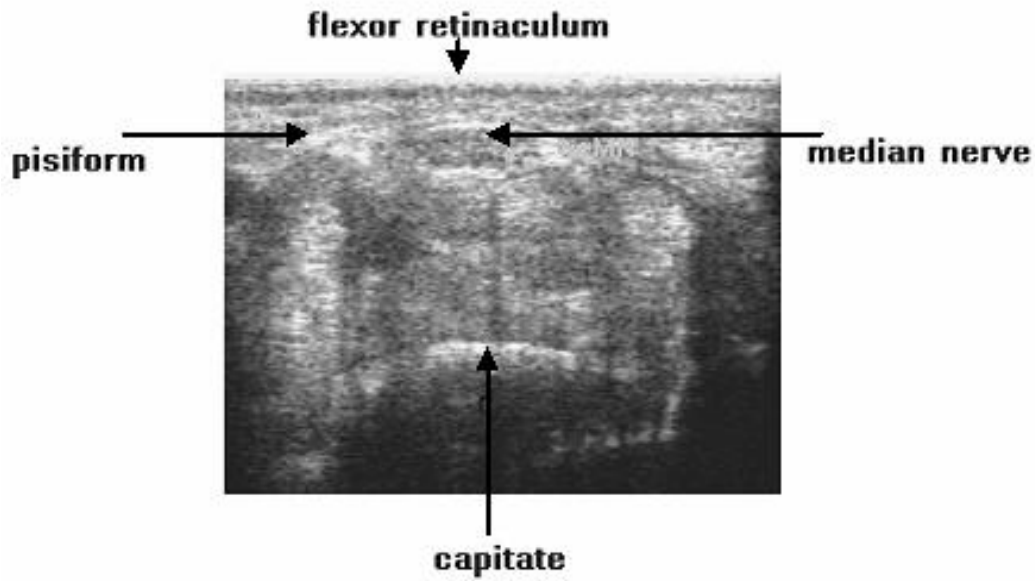


Figure 4-10: Ultrasonographic image at the middle of the carpal tunnel

The last image acquired was distal to the carpal tunnel and can be seen in Figure 4-11. Distally, the median nerve was not as easy to distinguish from its surrounding. The nerve's echogenic rim was less distinct and its mottled appearance was no longer apparent. The tendons could hardly be recognized, due to them being crowded into the smaller distal portion of the carpal tunnel. What could be distinguished was the proximal border of the hamate bone within the distal row of the carpal bones.

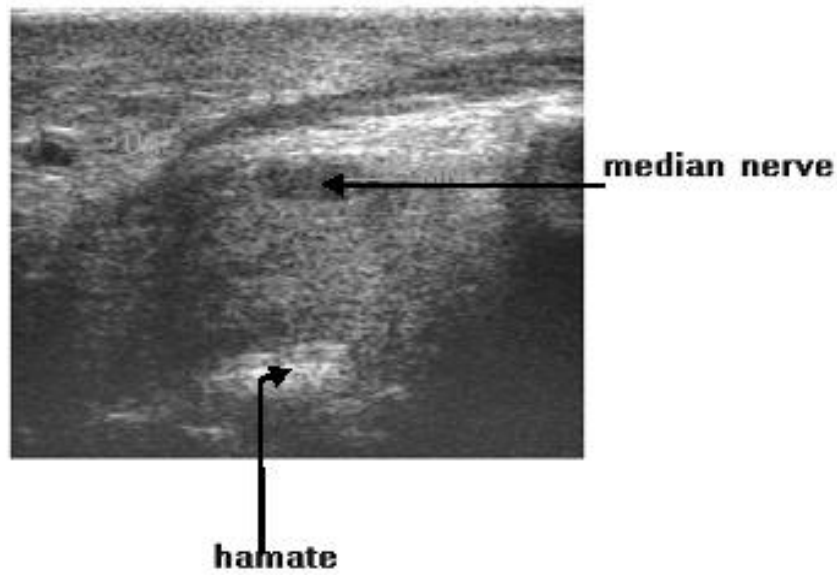


Figure 4-11: Ultrasonographic image distal to the carpal tunnel

Table 4.2 shows the mean values obtained from the 10 trials giving the parameters of the median nerve and their associated standard errors from both DIASUS and Scion applications.

Table 4.2: The mean and standard deviation values for the median nerve

Measurements	Proximal		Middle		Distal	
	DIASUS	Scion	DIASUS	Scion	DIASUS	Scion
Trace Area mm²	7.2 ± 1.3	7.5 ± 0.7	8.1 ± 1.3	7.9 ± 0.9	7.7 ± 1.5	7.6 ± 1.1
Ellipsoid Area mm²	8.6 ± 0.6	N/A	7.3 ± 1.0	N/A	8.7 ± 0.7	N/A
Major Axis mm	5.5 ± 0.3	5.1 ± 0.4	5.8 ± 0.2	5.4 ± 0.2	5.6 ± 0.7	4.9 ± 0.6
Minor Axis mm	1.7 ± 0.3	1.7 ± 0.2	1.8 ± 0.4	1.9 ± 0.1	2.0 ± 0.7	2.1 ± 0.6

The main findings for this study are discussed following the repeatability experiments in *Section 4.6* of this chapter.

4.5 Repeatability of Measurements

Another set of analytical experiments were performed to evaluate the reliability of the measurements that were obtained from the ultrasonographic images. Reliability refers to the reproducibility of a measurement and can be established by taking several measurements of the same parameters. Quantification of the median nerve during physical movement relies on the capability of the equipment to provide the best representation of the structure of interest and the ability of the user to optimize the equipment performance and to obtain and make use of the data.

The first reproducibility experiment used a single static scan of an ultrasonographic image from a non-symptomatic participant. The participant was in a seated posture with the wrist in a neutral position (not deviated in a radial or an ulnar direction). Two groups of ten measurements (20 measurements in total) were obtained for cross sectional area, flattening ratio, X and Y co-ordinate of the median nerve and the mean, standard deviation (SD) and standard error (SE) were calculated from a total of 20 measurements for each measurement. The mean values along with the standard deviation and standard error results are shown in Table 4.3.

Table 4.3: Repeat measurements taken from the same scan

	Area (mm²)	X Co-ordinate (mm)	Y co-ordinate (mm)	Major axis (mm)	Minor axis (mm)
Mean	5.24	24.49	9.31	4.25	1.59
SD	0.65	0.62	0.36	0.68	0.17
SE	0.21	0.20	0.11	0.21	0.06

The data showed a low standard error given in millimeters. Although, the values are near to the ideal value of zero, there is a slight variation in the data which could have arisen from the use of the software tools to obtain the measurements. Careful data collection is needed in successive studies or the implications could call into question the reliability of the measurements.

Single measurements were also taken from 20 different scans obtained from the same participant while the hand was in the same position. The mean values along with the standard deviation and standard error values obtained are shown in Table 4.4.

Table 4.4: Mean values for the repeat measurements taken from different scans

	Area (mm²)	X Co-ordinate (mm)	Y Co-ordinate (mm)	Major axis (mm)	Minor axis (mm)
Mean	5.97	30.15	8.04	4.69	1.52
SD	0.51	0.70	0.36	0.78	0.22
SE	0.23	0.31	0.16	0.35	0.10

The data again showed low standard error values given in millimeters for all the parameters. This was a slightly higher than the first repeatability study probably due to the position of the participant not being exactly replicated during each successive scan. Therefore, careful attention must be paid to the position of the participants to make sure they are exact, to reduce the variability in further studies.

The findings of the two repeatability studies show that most of the standard error values are much smaller than the recorded error values from other studies in the literature (Buchberger, *et al* 1991;1992; Greening, *et al* 2001; Nakamichi, Tachibana, 2002; Erel, *et al* 2003; Leonard, *et al* 2003; Altinok, *et al* 2004; Kotevoglu, *et al* 2004; Yesildag, *et al* 2004).

4.6 Discussion on the Measuring Procedures and Data Analysis for the Experimental Studies

The aim of the pilot experiment was to establish the scanning procedure, refine the methodological techniques and assess the software packages that could be taken forward and used in the main experimental studies.

The posture of the participant during the pilot experiment was easy to reproduce for each successive trial and allowed the experimenter easy access to the wrist being scanned. The seated position was relatively comfortable for the participant throughout the experiment and allowed the upper body posture to remain static. Replicating the posture precisely between the successive trials of the pilot experiment was vital to

reduce the variability of measurements caused by different positions that could affect the parameters of the median nerve within the carpal tunnel. This replication of body posture is also an essential requirement when comparing measurements between participants during each experimental study.

In addition, maintaining the position of the hand and wrist during scanning was also essential for the comparison of measurements taken during the trials. The pilot study involved the participant maintaining a relaxed finger posture however, the initial relaxed position was observed to change and the position had to be readjusted to replicate the initial finger posture. This 'relaxed position' instruction appeared not to be precise enough. It was therefore decided that more specific instructions were needed and involved holding the fingers in extension at the beginning of the scan to ensure precise co-ordination of hand movements during dynamic scanning procedures.

The process of scanning and obtaining measurements was a lengthy procedure and involved the participant remaining in a static seated position for more than an hour, throughout each of the trials. Although the participant appeared comfortable throughout the pilot experiment, the main experimental studies would require more information to be obtained and therefore would take more time. The main experimental studies would also involve participants that were symptomatic of median nerve disorders and a static position over a long period of time could cause additional stress to an existing injury. Therefore the time taken to perform the experiments needed to be reduced. This was done by adapting some of the methodological procedures which are detailed below.

The values obtained in the pilot experiment were calculated from the average of 10 trials, to reduce the effects of experimental error due to the examiner's lack of ultrasonographic experience. However, Nakamichi and Tachibana (2002), whose study to establish the accuracy of the cross-sectional area measurement of the median nerve (detailed in *Chapter 2* in sub-section 2.5), concluded that ultrasonographic measurement was satisfactory when five repetition measurements were averaged. In addition, it was felt that during the course of the pilot experiment the manual and technical skills had been enhanced and improved, shown by the low standard error values between each of the individual trials. It was therefore decided that 5 trials would be sufficient enough to acquire accurate measurements without applying additional stress to any existing injury in symptomatic participants.

All sets of measurements acquired at each level during the pilot experiment showed similar values for cross-sectional area, major and minor axis. However, the measurements taken at the distal wrist crease in the middle of the carpal tunnel produced clearer images overall including well defined boundaries of the median nerve. This allows for better identification of the nerve and more accurate measurements to be taken within its boundaries. Consequently, it was decided that for studies into median nerve dynamics, the level in the middle of the carpal tunnel at the distal wrist crease would be the most appropriate to be used in the successive experimental studies.

The method of collection for the cross-sectional area measurement was taken using the ellipsoid and the direct trace tools in the pilot experiment. Although the use of the

ellipsoid tool was technically easier to use, the nerve itself was not a perfect ellipsoid shape while the direct trace tool was able to encompass the true shape of the nerve. It was therefore decided that the direct trace tool would be used in subsequent experimental studies because it could acquire a more accurate measurement.

Analysis of the data for the pilot experiment was obtained from both DIASUS and Scion Image Processing Package software. Both on-line and off-line programs provided similar results. The measurements obtained from DIASUS were taken and recorded during the experiment because the information was deleted when a new frame within the cine-loop was chosen or a new scan was performed. This resulted in a procedure that involved obtaining a sonogram and taking the measurements before moving on to any successive scan, a process that added to the length of time of the scanning procedure and the time that the participant had to remain in a static position. The Scion software imported the images and calculated the measurements off-line without having to take measurements at the time of scanning. It was therefore decided that Scion software would be taken forward to be used in the consecutive experimental studies which would considerably reduce the time taken in the experimental procedure.

In addition, the Scion software can calculate the cross-sectional area and major and minor axis from a single direct trace of the median nerve around its perimeter. It could also calculate values for the X and Y co-ordinates showing the respective mediolateral (horizontal plane) and anteroposterior (vertical plane) location of the nerve within the wrist. For dynamic study of the median nerve it seems logical that these parameters should be considered as valid measurements for further investigation.

5. Experimental Studies

This chapter starts by detailing the general design and the issues that are common to all three experiments. This includes the experimental procedures, the development of which has been described in *Chapter 4* and the selection criteria and characteristics of the participants which were drawn from a common pool. Each of the three studies are then described in turn and includes the aims, results and a discussion on what was to go through to subsequent study(ies). Figure 5-1 gives an overview of the Chapter.

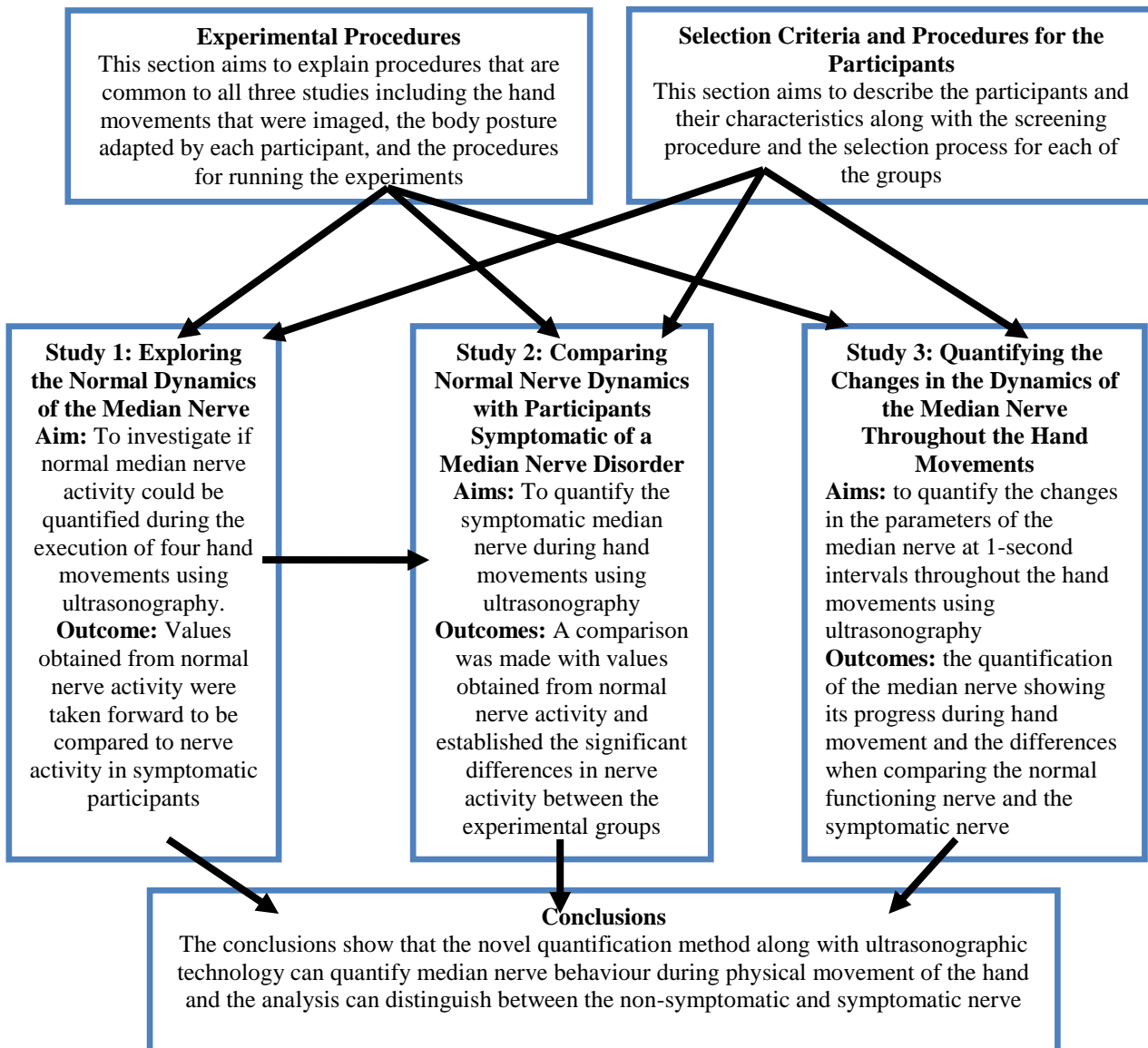


Figure 5-1: Overview of the experimental studies

5.1 Experimental Procedures

The basic procedures for the experimental studies were first identified in *Chapter 4: Development of the Methodology* and have been refined to consider the specific requirements of each of the experimental studies. These refinements include a number of common procedures that are related to all of the studies and are detailed below. Specific requirements from individual experimental studies are given at the start of the corresponding sections.

5.1.1 Choice of Simple Hand Movements for Study

Four functional hand movements were selected for this study. They were selected on the basis that they represented a good range of real common hand tasks and were easy to perform and replicate for the individual participant in each successive trial and between a number of individuals in each experiment, so that comparisons in data could be made. In addition, the position of the hand and wrist (palm facing upwards with the wrist in a neutral position) permitted access by the transducer to the wrist, while the movement was being performed.

The movements used in the experimental studies are the finger grip, the power grip, the pinch grip and thumb opposition which are described below and illustrated in Figure 5-2. All of the movements started with the fingers slightly extended as seen in Figure 5-2a.

- The finger grip, involved flexing all the fingers at the metacarpophalangeal and proximal interphalangeal joints slowly without moving the thumb, until the fingertips touched the palm of the hand (Figure 5-2b).
- The power grip, involved flexing all the joints in the fingers and thumb to form a fist (Figure 5-2c).
- The pinch grip is a type of precision grip and involved flexing the metacarpophalangeal joints in the thumb and first finger along with the proximal interphalangeal joint in the first finger, until they touched (Figure 5-2d).
- The thumb opposition involved movement of the thumb across the palm towards the ulnar side of the hand with a slight flexion of the thumb interphalangeal joint, until it touched the base of the little finger (Figure 5-2e).

These movements have been identified and classified in a number studies (Napier, 1956; Landsmeer, 1962; Long, *et al* 1970; Kamakura, *et al* 1980; Wells, 2004) and are detailed in the *Chapter 2* section 2.1.

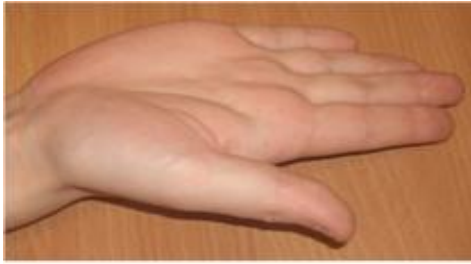

Figure 5-2a: The start position with the palm facing upwards and the digits extended



Figure 5-2b: The finish position of the finger grip



Figure 5-2c: The finish position of the power grip



Figure 5-2d: The finish position of the pinch grip

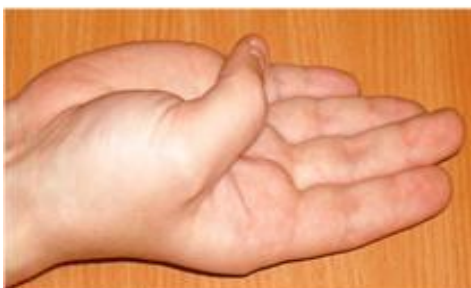

Figure 5-2e: The finish position of the thumb opposition

Figure 5-2: The hand movements

5.1.2 Choice of Body Posture for the Trials

Before running the experiment initial considerations included the positioning of the participant's posture and involved the whole upper body while they were seated position. The back needed to be straight and was aided by a high-back chair, both shoulder's had to be relaxed on both sides and the upper arms had to be placed at the side of the body, flexed at the elbow with the forearm resting on the arm of the chair, the palm facing upwards and the wrist in a neutral position.

A seated body position was chosen for the participants in this study because it appeared from the literature to be a novel position for ultrasonographic study, with most of the previous studies in this area choosing a supine posture. It was more representative of a work-related position with a number of jobs that have been cited as being high risk of musculoskeletal injury, employing a seated posture at work. In addition, it was an easy position for the participants to hold throughout the length of the scanning process and allowed easy access to the wrist being scanned.

5.1.3 Procedures in Running the Experiment

The participants were asked to practice each movement a number of times before the data collection started so that each movement could be co-ordinated precisely. This allowed for a reduction in variation between each trial, permitted comparisons between individuals and defined discrete points throughout the movement that could be used in subsequent analysis.

Every participant practiced each movement before being scanned whilst the examiner observed the activity and counted out the time of the five-second cine-loop recording. The intension was to co-ordinate the movement so that the participant arrived at six specific points in each movement within the five second scan, with each point representing the start position and 1-second intervals after that time. The participant then practiced the movements whilst being scanned with the experimenter counting through the five-second cine-loop and observing the dynamic sonograms on the monitor. This was necessary so that the examiner became familiar with the sonographic activity and was able to detect when the participant was out of time with the movement or had altered the posture of the upper body, without having to observe the participant directly.

When the examiner and the participants were comfortable and fully satisfied that the movements were performed correctly, the data collection commenced. The scanning process was carried out while the participant sat facing the experimenter, with the dominant arm flexed by 90° at the elbow and the anterior surface of the wrist facing upwards. The transducer was placed on the distal wrist crease of the participant, at the level of the pisiform and perpendicular to the median nerve. This produced transverse images of the contents of the carpal tunnel. The participants performed five trials for each movement while transverse images were captured as a cine loop recording. The set of recordings from each trail for each participant was assigned a random code number so that when analysis was performed, the identity of the individual participant was not immediately obvious.

Throughout the experimental studies the experimenter constantly verified the posture of the participant and the timing of the movement and checked that the participant was comfortable or needed a break.

Measurements were taken off-line, using Scion Image Processing Package software by direct trace around the perimeter of the median nerve. From this trace, the Scion software automatically calculated the nerve's cross-sectional area, major and minor axis and the X and Y co-ordinates. The measurements taken for cross-sectional area gives a value for the size of the nerve, while the X and Y co-ordinates shows the nerves location within the wrist (giving the position of the centre of the nerve along a mediolateral and anteroposterior plane, respectively). The measurements taken for the major and minor axis were used to calculate the flattening ratio (by dividing the major axis by the minor axis) which indicates the shape of the nerve with higher values indicating a flatter shape (a value of 0 is representative of a circle and 1 is a flat line).

The measurements obtained from Scion were processed by subtracting the values taken at one interval during the movement by the values taken in the previous interval, to produce data that showed the change in the size, shape and position of the median nerve for each movement. This change in the parameters is represented by a positive value, a negative value or a value of zero. A positive value for cross-sectional area shows an increase in the area of the nerve, whereas a negative value represents a decrease in area. A positive value for the flattening ratio shows an increase in the ratio and indicates the shape of the nerve is flatter, with a negative value indicating the shape has become rounder. Positive values for the X co-ordinate shows movement of the nerve towards the radial (towards the thumb) side of the wrist while a negative

value shows the position has moved in a more ulnar (towards the small finger) direction, while a positive value for the Y co-ordinate shows the nerve moving towards the anterior (surface) of the wrist and a negative value indicating movement towards the posterior (back) of the wrist. A value of zero indicates that there is no change in the parameter being analyzed.

5.2 Participant Characteristics and Selection Criteria

This section considers the participants involved in this research and includes the desired characteristics needed for the studies and the selection of the participants into their experimental groups.

5.2.1 Characteristics of Participants

The characteristics needed for this study was a non-symptomatic participant group with normal median nerve function along with a symptomatic group that showed signs of a median nerve disorder at the wrist. The disorder could include CTS, non-specific upper limb disorder or any other disorder that affects the median nerve at the wrist. Subjects were included if they reported no history of inflammatory arthritis, previous upper arm surgery, diabetes, heart disease, breathing problems, dizziness, fainting or blackouts, double vision or if the participants are pregnant.

When establishing a pool of participants for this study an attempt was made to acquire a similar amount of males and females, along with a broad age range. The state of the participants median nerve function was unknown at the recruiting stage and therefore assigning an equal amount of males/females that represented a broad range of ages

to each group was impossible. Current literature on this subject suggests that disorders are more common in females than males and are more likely to affect people in an older age range than the young (Hagberg, Wegman, 1987; Buckle, 1997; Gusbers Van Wijk, Kolk, 1997; Buckle, Devereux, 2002; Health and Safety Commission, 2004; Punnet, Wegman, 2004; Treastera, Burra, 2004). Therefore it was expected that the symptomatic group would possibly contain more female participants and an older age range.

5.2.2 Selection procedures for participants with/without symptoms of median nerve disorder

The subjects in this study were divided into three groups; non-symptomatic, moderate symptomatic and fully symptomatic groups. This selection process was the result of the upper limb function assessment, which is a clinical test of muscle and neural dynamics (Butler, 1991) and involved a combination of subjective and objective measures which specifically aimed to establish median nerve disorder at the wrist.

The subjective measures included a self-report pain questionnaire which was designed specifically for this study and is shown in *Appendix D*. The questionnaire provided information on the subject's profile and their physical state so that the physical examination and subsequent scanning process could proceed appropriately and safely. The objective physical examination performed by the physiotherapist included standard assessment techniques designed for

patients complaining of upper limb or cervical spine disorders, a myotome and dermatome assessment and the upper limb tension test 1 (ULTT 1).

The standard assessment technique involved the joints being evaluated using standard tests for active and passive range of movements in the neck, shoulder, elbow, wrist and finger. The active stage included a range of movements performed by the subject, while the passive stage involved the physiotherapist applying pressure to each of the movements. The purpose was to ascertain the full range of movement in the joint and to assess the 'end feel'; a term that describes the state of the soft tissue and bone as assessed by the physiotherapist during this stage. Soft tissue should have a stretchy end feel, whereas bones should have a hard locking end feel. Abnormal end feel can suggest disorder, disease, ageing, or postural problems etc (Butler, 1991).

Spinal nerve roots supply specific muscles (myotomes) and areas of skin (dermatomes) from the cervical spine area through to the distal regions of the upper limb (Ingram-Rice, 1997) and motor and sensory supply can be tested to establish nervous system disorders by examining these myotomes and dermatomes. Myotome assessment involved asking the participant to hold a position while resistance was applied by the physiotherapist. Dermatome assessment included a sensory evaluation by the physiotherapist who touched the area of a specific dermatome and recorded how and where the participant felt the touch (Ingram-Rice, 1997). Both tests were performed to establish the presence and location of a peripheral nerve disorder.

ULTT1 belongs to a group of physical examinations that selectively stress individual nerves. Movements are passive and involve the participant lying supine in a neutral position (head facing upwards, shoulders relaxed, arms at the side of the body and legs flat and together).

Shoulder abduction puts tension on the C5, 6 and 7 nerve roots, and maintenance of depression will also keep the brachial plexus on some tension. In this sub-test, there is no selective stress on a particular nerve trunk with all cords being under tension but if the test results in pain or discomfort it suggests that there is a problem with the nerves of the upper limb as a whole (Butler, 1991).

Elbow extension will tense the radial and median nerve and at the same time slackening the ulna nerve in the same area, while wrist and finger extension tightens the ulna and median nerve and slackens the radial nerve (Butler, 1991). With each of these movements the symptoms and signs of upper limb disorder were monitored. Reduced movement or the production of symptoms indicates a potentially positive ULTT1 and suggests a problem in the area being examined. This was then checked by moving other parts of the upper limb that are not structurally connected with the symptomatic region, but do have neural connections (Butler, 1991). If there is no change in symptoms with this process a positive neural test is confirmed.

As a result of the assessment the participants were divided into three groups: a non-symptomatic group, moderate symptomatic group and a symptomatic

group. The non-symptomatic group produced negative results during examination verifying normal neural function. This was established by having a full range of movement (ROM) in all the joints of the upper limb and being pain and injury free. The participants from the fully symptomatic group produced positive results by showing a limited ROM and declared themselves as either in pain during the assessment. The participants selected for the moderately symptomatic group either showed no abnormal signs in median nerve function but declared themselves as in pain, or stated themselves as pain free but showed a limited ROM. These participants could potentially have an early on-set of a median nerve disorder or could have another disorder that affects the median nerve at the wrist.

5.2.3 Sample Size and Recruitment

The sample size was established after discussions with two subject matter experts who were the supervisors of this project and experts in the field of upper limb biomechanics and ergonomics. The discussions revolved around the current literature on initial studies into median nerve and ultrasonography and established that many of the studies had used small sample sizes that ranged between 14 and 40 participants (Buchberger *et al* 1991;1992; Leonard *et al* 2003; Altinok *et al* 2004; Kotevoglou *et al* 2004).

The participants were recruited from the staff and students of the University of Nottingham. This was an opportunity sample drawn from a population based on availability, convenience, time and practicality and was used because it was quick and economical form of sampling.

5.2.4 Details of Participants in the Pool

The experimental procedure was approved by the local ethical committee and the Ethical Review Committee Form and Investigation Protocol for the Ethical Review Committee can be seen in *Appendix B*. Informed consent was obtained prior to the investigation from participants recruited from the staff and students of the university. The participant consent form is shown in *Appendix C*.

Twenty two participants signed up for the study. However, one participant was excluded from the study due to being hypermobile (a term that defines joints that stretch farther than normal, also known as being double-jointed) and was therefore not included in the upper limb assessment test or scanning process.

The characteristics of the 21 participants, who were assigned an experimental group after the upper limb assessment, are shown within their group in Table 5.1. There were some differences between the three groups, particularly in the gender distribution with the non-symptomatic group consisting mainly of men and being on average 10 years younger.

The participants in the fully symptomatic group were on average older women with a larger age range. This is consistent with the literature that has identified that disorders are more common in females in an older age range (Hagberg, Wegman, 1987; Buckle, 1997; Gusbers Van Wijk, Kolk, 1997; Buckle, Devereux, 2002; Health and Safety Commission, 2004; Punnet, Wegman, 2004; Treastera, Burra, 2004). However, the groups were relatively similar in stature and weight.

Table 5.1: The Characteristics of the Pool of Participants

Characteristics	Non-symptomatic group (n=8)	Moderately symptomatic group (n=5)	Fully symptomatic group (n=8)
Sex (male: female)	5:3	3:2	2:6
Mean age (years)	34	36	44
SD	7.2	9.3	11.2
Range	26 - 44	26 - 51	28 - 62
Mean height (m)	1.69	1.76	1.69
SD	0.08	0.05	0.11
Range	1.57 – 1.83	1.68 – 1.81	1.55 – 1.88
Mean weight (kg)	69	70	66
SD	± 11.9	± 7.4	± 21.0
Range	53 - 85	58 - 76	47 - 110

From this pool of participants two participants left the study before the scanning process took part. This resulted in 19 participants taking part in the initial scanning process which imaged the median nerve during the first movement (finger grip). Following this 5 other participants left the study (leaving 14 participants) and were not involved in the scanning processes of the remaining three movements (power grip, pinch grip and thumb opposition movements). Table 5.2 shows the participant characteristics of the pool that undertook the upper limb assessment.

Table 5.2: The Participant Characteristics of those that took part in the scanning process

Characteristics	Finger Grip Movement			Power, Pinch and Thumb Opposition Movement		
	Non-symptomatic group (n=7)	Moderately symptomatic group (n=4)	Fully symptomatic group (n=8)	Non-symptomatic group (n=6)	Moderately symptomatic group (n=3)	Fully symptomatic group (n=5)
Sex (male: female)	5:2	2:2	2:6	4:2	2:1	1:4
Mean age (years)	35	35	45	33	36	42
SD	± 7.4	± 9.0	± 11.5	± 7.3	± 10.9	± 12.8
Range	24-43	26 -51	29 - 60	24-43	27 -48	29 - 59
Mean height (m)	1.70	1.71	1.69	1.69	1.70	1.67
SD	± 0.7	± 0.2	± 0.11	± 0.7	± 0.1	± 0.14
Range	1.62-1.83	1.56 – 1.81	1.55 – 1.89	1.62-1.83	1.56 – 1.81	1.55 – 1.89
Mean weight (kg)	71	69	65	71	69	64
SD	± 11.9	± 7.5	± 20.9	± 12.8	± 9.3	± 26.4
Range	54-85	58 - 75	47 - 110	54-85	58 - 75	47 - 110

5.3 Study 1: Exploring the Normal Dynamics of the Median Nerve

The aim of this study was to use a novel quantification technique and dynamic ultrasonographic technology to measure normal median nerve activity within the carpal tunnel in participants with normal nerve function, during the execution of four functional hand movements. The experimental procedure including the scanning process, data collection and analysis, was performed as described in sections 5.1 and 5.2.

Seven participants (five male and two female) who had no clinical signs or symptoms of median nerve disorder were recruited from the staff and students of the University of Nottingham. However, one participant left the study and was therefore not included in three of the hand movements. The characteristics from the pool of participants are given earlier this chapter under the section 5.2 with Table 5.3 showing the related number of participants that took part in the scanning process for each hand movement.

Table 5.3: The number of non-symptomatic participants that took part in each movement

Movements	Number of Participants
Finger Grip	7
Power grip	6
Pinch Grip	6
Thumb Opposition	6

The measurements of the median nerve from 5 trials were taken off-line using Scion Image Processing Package software which calculated the cross-sectional area, major

and minor axes and X and Y co-ordinates (giving the centre of the nerves location along a mediolateral and anteroposterior plane, respectively), at the start and the end position of each movement. The data was then processed, by subtracting the value obtained at the end position by that obtained at the start position, to produce values that showed the change in size, shape and location of the nerve for each movement.

The results from this study are to be used to create baseline data on the normal pattern of nerve movement for some simple hand actions and compared to the values obtained from participants who were either moderately symptomatic or fully symptomatic of a median nerve disorder.

5.3.1 Results of Study 1

Table 5.4 gives the mean values for cross-sectional area and flattening ratio at the start and end of each movement along with the change in these values. For the X and Y co-ordinates only the change during the movement is given, as the location of the nerve at the start and end position is an arbitrary number with the zero reference differing between individuals. For the X co-ordinate, positive data indicates movement towards the radial side of the wrist (thumb side) and negative data indicates movement towards the ulnar side (small finger). For the Y co-ordinate, positive data indicates movement towards the anterior (surface) of the wrist and negative data indicates movement towards the posterior (back).

Table 5.4: Results of Study 1 - Parameters of the median nerve in non-symptomatic participants

Action	Number of participants (n)	Cross-sectional area mm ² Mean (SE)			Flattening ratio (FR) Mean (SE)			X co-ordinate mm Mean (SE)	Y co-ordinate mm Mean (SE)
		start	end	change end- start	start	end	change end- start	change end-start	change end-start
Finger Grip	7	3.7 (1.34)	5.6 (1.36)	1.9* (0.79)	2.7 (0.80)	2.1 (0.57)	-0.6 (0.53)	1.5* (0.56)	0.1 (0.64)
Power Grip	6	3.1 (0.51)	4.3 (0.42)	1.2 (0.85)	3.8 (0.67)	2.6 (0.65)	-1.2* (0.78)	2.6* (1.22)	0.2 (0.40)
Pinch Grip	6	4.4 (1.16)	5.0 (1.04)	0.6 (0.44)	2.9 (0.73)	2.5 (0.57)	-0.45 (0.72)	1.6* (0.71)	0.1 (0.27)
Thumb Opposition	6	3.9 (1.26)	4.5 (1.48)	0.6* (1.56)	2.9 (0.61)	2.5 (0.05)	-0.4* (0.32)	0.1* (1.34)	-0.2 (0.38)

* statistically significant difference at $p \leq 0.05$

The values obtained that show the change in the measured parameters during each movement is also given in Figure 5-3, and the full data giving the values obtained from each individual participant is given in *Appendix E*.

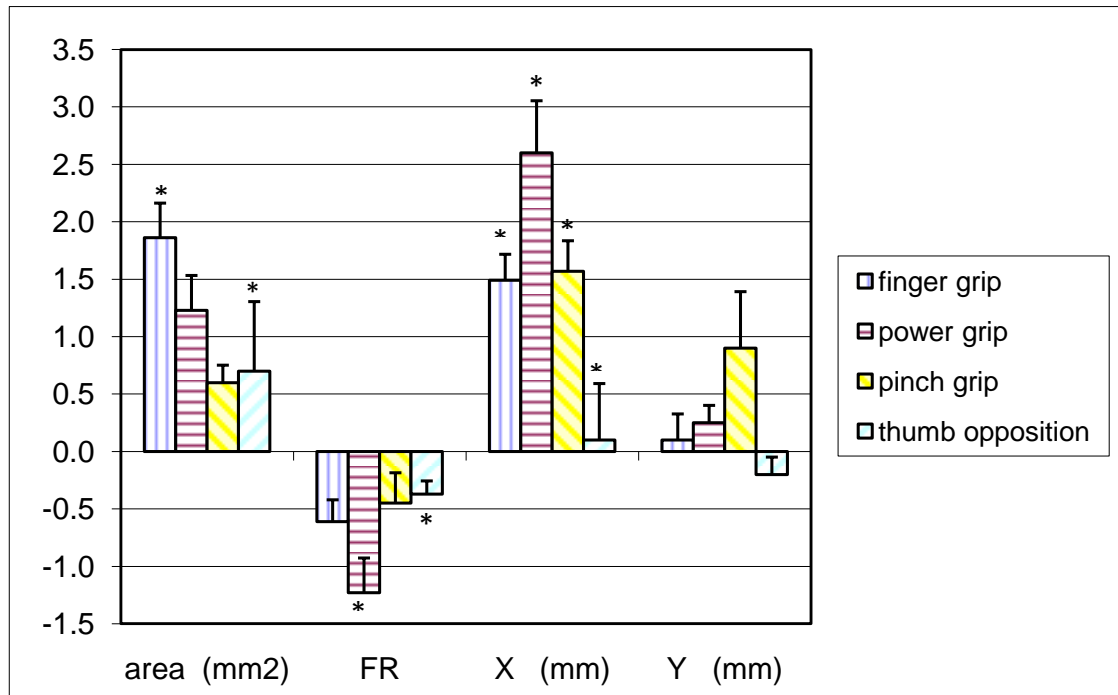


Figure 5-3: The mean changes in the median nerve parameters over each movement (Error bars represent standard error)

Analysis of the data was performed to investigate if there were any statistically significant differences between the movements using an analysis of variance (ANOVA) with differences accepted when the significant value (p) was equal to or less than 0.05. A series of ANOVAs revealed significant differences for the cross-sectional area ($F(df\ 3-21) = 2.26$), flattening ratio ($F(df\ 3-21) = 2.13$) and X-coordinate ($F(df\ 3-21) = 6.23$). No significant overall differences were found for the Y-coordinate ($F(3-21) = 1.28$).

A post hoc Tukey HSD statistical test was used to identify the statistically significant differences ($p \leq 0.05$) between the movements and indicated in Table 5.4 and Figure 5-3 by an asterisk.

The values giving the change in cross-sectional area showed statistically significant differences between the thumb opposition (M $0.6 \pm 1.56\text{mm}$) and finger grip (M $1.9 \pm 0.79\text{mm}$, $p = 0.04$) and the values showing the change in flattening ratio showed significant differences between the thumb opposition (M -0.4 ± 0.32) and the power grip (M -1.2 ± 0.78 , $p = 0.02$). The data giving the change in X co-ordinate produced statistically significant differences between the thumb opposition (M 0.1 ± 1.34) and all the other movements (finger grip: M $1.5 \pm 0.56\text{mm}$, $p = < 0.01$. Power grip: M $2.6 \pm 1.22\text{mm}$, $p = < 0.01$. Pinch grip: M $0.1 \pm 0.27\text{mm}$, $p = < 0.02$). There were no statistically significant differences for any of the values given for the Y co-ordinate.

The results show that while the finger grip, power grip and pinch grip all showed similar anatomical activity of the median nerve within the wrist, median nerve activity during the thumb opposition was significantly different in a number of parameters when compared to the other movements.

A paired samples t-test was also performed to investigate if the mean values obtained at the start of each movement were significantly different to the values obtained at the end of the position. The results of the analysis are given in Table 5.6 and show the t-value, the degrees of freedom (df) and the significant number (p) for measurements.

The measurements that show no significant differences are marked with X.

Table 5.6: Analysis of the difference between the parameters of the median nerve between the start and end positions

	Cross-sectional area	Flattening ratio	X co-ordinate	Y co-ordinate
Finger grip	$t(df\ 6) = -6.24,$ $p = < 0.01$	$t(df\ 6) = 2.80,$ $p = 0.03$	$t(df\ 6) = -6.96,$ $p = < 0.01$	X
Power grip	$t(df\ 5) = -3.56,$ $p = 0.01$	$t(df\ 5) = 3.89,$ $p = 0.01$	$t(df\ 5) = -5.20,$ $p = < 0.01$	X
Pinch grip	$t(df\ 5) = -3.48,$ $p = 0.02$	$t(df\ 5) = -3.38,$ $p = 0.02$	$t(df\ 5) = -5.47,$ $p = < 0.01$	X
Thumb opposition	X	$t(df\ 5) = 2.88,$ $p = 0.03$	X	X

Analysis between the start and the end positions during the finger grip showed significant differences in the cross-sectional area (start $3.7 \pm 1.34\text{ mm}^2$, end $5.6 \pm 1.36\text{ mm}^2$, $p = < 0.01$), in the flattening ratio (start 2.7 ± 0.80 , end 2.1 ± 0.57 , $p = 0.03$) and the X co-ordinate (1.5 ± 0.56 , $p = < 0.01$).

Analysis of the power grip showed significant differences for cross-sectional area (start $3.1 \pm 0.51\text{ mm}^2$, end $4.3 \pm 0.42\text{ mm}^2$, $p = 0.01$), flattening ratio (start 3.8 ± 0.67 , end 2.6 ± 0.65 , $p = 0.01$) and for X co-ordinate ($2.6 \pm 1.22\text{ mm}$, $p = < 0.01$).

During the pinch grip significant differences were seen in the cross-sectional area (start $4.4 \pm 1.16\text{ mm}^2$, end $5.0 \pm 1.04\text{ mm}^2$, $p = 0.02$), flattening ratio (start 2.9 ± 0.73 , end 2.5 ± 0.57 , $p = 0.02$) and for X co-ordinate ($1.6 \pm 0.71\text{ mm}$, $p = < 0.01$).

For the thumb opposition significant differences were seen only in the values obtained from the flattening ratio (start 2.9 ± 0.61 , end 2.5 ± 0.05 , $p = 0.03$).

5.3.2 Study 1: Discussion

Analysis of the data was performed to investigate if there was any difference in the activity of the median nerve between the hand movements. The data showed no significant differences between the finger grip, the power grip and the pinch grip with the median nerve moving to a more radial position within the wrist, the cross-sectional area increasing and the nerve became rounder in shape in each of the three movements. However the thumb opposition was found to be significantly different to the other movements in the values obtained for cross-sectional area, flattening ratio and the X co-ordinate.

Analysis of the data was also performed to investigate if there was any difference in the parameters of the median nerve between the start and the end position within each movement. The data showed that there were significant differences between the values obtained at the start and the end positions for cross-sectional area flattening ratio and the X co-ordinate during the finger grip, power grip and pinch grip, while during the thumb opposition significant differences were seen only in the values obtained at the start and end positions for the flattening ratio.

From observations and analysis of the data it appears that, as the digits move from extension at the beginning of the movement to flexion at the end, the median nerve moved in a radial direction during the finger, power and pinch grip the movements. This anatomical activity could account for the increase in cross sectional area and the decrease in flattening in the non-symptomatic participants as the median nerve moved to a less compressed position within the wrist

During thumb opposition lower arm rotation occurs where the radius bone rolls around the ulna bone at the wrist and the wrist size is visibly reduced whereas in the other movements there was no rotation of the radius and ulna and therefore the wrist size was not affected by the movement itself. It is anatomically plausible that as lower arm rotation occurs, wrist size is reduced and so too is the space within the carpal tunnel, which could account for the lesser change in parameters.

Previous studies undertaken into the area of sonographic imaging of the median nerve include research by Greening, *et al* (2001) and Erel, *et al* (2003) which are detailed in *Chapter 2* section 2.5. Greening, *et al* (2001) found that the median nerve was $4.8 (\pm 0.42)$ mm more radial during 30° flexion than in 30° extension in the group with normal median nerve function. Erel, *et al* (2003) found that normal median nerve movement was 1.6 ± 0.24 mm more radial during extension of the metacarpophalangeal joint when compared to the neutral position and that it was a more rounded shape in a neutral position (2.00 ± 0.05) when compared flexion (2.48 ± 0.03).

Although there are differences in experimental protocol between the studies of Greening, *et al* (2001) and Erel, *et al* (2003) and this present study, including differences in the posture of the participant and the physical movement studied (detailed in *Chapter 2*, section 2.5), both of the previous studies showed radial movement of the median nerve during hand activity which is consistent with the findings of this research.

5.3.3 Study 1: Conclusions

The results indicate that median nerve activity during physical movement can be measured using a novel quantification method and ultrasonographic technique. The data produced from this study was to be employed to produce baseline values for normal median nerve behaviour. This data is to be taken forward to the following study to be used for comparative purposes to investigate if ultrasonography and the novel quantification technique can distinguish between the data obtained from a normal functioning median nerve and with data obtained from participants that are symptomatic of a median nerve disorder.

5.4 Study 2: Comparing Normal Nerve Dynamics with Participants Symptomatic of a Median Nerve Disorder

The aim of this study was to quantify the change in size, shape and location of the median nerve during functional hand activity in participants who were either moderately symptomatic or fully symptomatic of an median nerve disorder using ultrasonography. The results from this study are then compared to the values from participants with normal median nerve function obtained in the first study.

The scanning process and the four movements performed by the participants are described in the section 5.1. Off-line analysis Scion Image Processing Package software which calculated values for cross sectional area, flattening ratio and the X- and Y- co-ordinates at the start and end positions of each movement. This data was then processed, by subtracting the values obtained at the end of the movement from

those obtained at the start, to give the size, shape and location of the nerve during each movement.

The screening and selection process is described in section 5.2. The process assigned the individuals into three groups; a non-symptomatic group, a moderately symptomatic group and a fully symptomatic group. The collective pool of moderate and symptomatic participants who took part in the scanning process contained twelve participants (five male and eight female). However, four participants left the study and were therefore not included in three of the hand movements. Table 5.7 shows the related number of participants that took part in each movement.

Table 5.7: The number of moderate and fully symptomatic participants that took part in each movement

Movements	Number of moderate symptomatic participants	Number of fully symptomatic participants
Finger Grip	4	8
Power grip	3	5
Pinch Grip	3	5
Thumb Opposition	3	5

5.4.1 Study 2: Results

The data obtained from the moderate and fully symptomatic groups are shown in Table 5.8 and shows the mean values for area and flattening ratio at the start and end of each movement along with the change in the values during the movement. For the

X and Y co-ordinates only the change during the movement is given, as the location of the nerve at the start and end position is an arbitrary number with the zero reference differing between individuals. The data in full for each individual participant is shown in *Appendix F*.

A one-way between-group analysis of variance (ANOVA) statistical test was performed to investigate if there was any significant difference between the four movements (accepted when the significant value was equal to or less than 0.05). The ANOVA revealed significant differences in cross-sectional area ($F(df\ 3-21) = 2.26$).

A Post hoc Tukey HSD statistical test Analysis of the data obtained from the fully-symptomatic group showed statistically significant differences in cross-sectional area between the thumb opposition ($M\ 0.1 \pm 0.63\text{mm}^2$) and the pinch grip ($M\ -1.6 \pm 0.49\text{mm}^2, p = 0.01$).

Table 5.8: Results of Study 2 - Parameters of the median nerve in moderate and fully symptomatic participants

Movement	Group	Number of participants	Cross-sectional area mm ² Mean (SE)			Flattening ratio (FR) Mean (SE)			X co-ordinate mm Mean (SE)	Y co-ordinate mm Mean (SE)
			start	end	change	start	end	change	change	change
Finger grip	Moderate symptomatic	4	3.6 (0.72)	3.4 (0.70)	-0.2 (1.01)	3.0 (1.57)	2.6 (1.05)	-0.4 (1.25)	0.4 (1.03)	-0.1 (0.59)
	Fully symptomatic	8	5.1 (1.71)	3.9 (1.01)	-1.2 (0.94)	2.0 (0.75)	2.6 (1.46)	0.6 (1.03)	0.4 (0.24)	-0.1 (0.55)
Power grip	Moderate symptomatic	3	3.3 (0.20)	4.0 (1.18)	0.7 (1.13)	2.9 (0.67)	2.4 (0.36)	-0.5 (0.31)	1.0 (1.10)	0.2 (0.11)
	Fully symptomatic	5	5.2 (1.78)	3.6 (1.02)	-1.6 (1.35)	2.7 (0.48)	3.3 (0.87)	0.6 (0.46)	0.6 (0.27)	-0.2 (0.23)
Pinch grip	Moderate symptomatic	3	3.0 (0.61)	3.2 (0.39)	0.2 (0.97)	2.7 (0.64)	2.3 (0.44)	-0.4 (1.04)	0.5 (0.84)	0.2 (0.30)
	Fully symptomatic	5	4.9 (1.08)	3.3 (0.67)	-1.6* (0.49)	2.7 (0.18)	3.0 (0.28)	0.3 (0.21)	0.4 (0.58)	-0.2 (0.36)
Thumb opposition	Moderate symptomatic	3	3.5 (0.33)	3.9 (0.17)	0.4 (0.32)	2.0 (0.33)	2.2 (0.26)	0.2 (0.22)	0.2 (1.25)	-0.4 (0.41)
	Fully symptomatic	5	3.6 (1.04)	3.7 (1.10)	-0.1* (0.63)	2.7 (0.62)	3.1 (0.70)	0.4 (0.53)	-0.5 (1.12)	-0.3 (0.34)

* statistically significant difference from the non-symptomatic group at $p \leq 0.05$

A paired samples t-test was also performed to investigate if the mean values obtained at the start of each movement were significantly different to the values obtained at the end of the position for each of the groups. The results of the analysis are given in Table 5.9 and show the t-value, the degrees of freedom (*df*) and the significant number (*p*) for measurements. The measurements that show no significant differences are marked with X.

Analysis between the start and the end positions during the finger grip showed significant differences in the fully-symptomatic group for cross-sectional area (start $5.1 \pm 1.71\text{mm}^2$, end $3.9 \pm 1.01\text{mm}^2$, $p < 0.01$). No differences were seen between the start and the end positions in the moderate group.

Analysis of the power grip for the fully- symptomatic group showed significant differences for cross-sectional area (start $5.2 \pm 1.78\text{mm}^2$, end $3.6 \pm 1.02\text{mm}^2$, $p < 0.05$), flattening ratio (start 2.7 ± 0.48 , end 3.3 ± 0.87 , $p = 0.04$) and for X co-ordinate ($0.6 \pm 0.27\text{mm}$, $p < 0.01$). Again, there were no differences in moderate group between the start and the end positions for the power grip.

During the pinch grip significant differences were seen in the fully symptomatic group for cross-sectional area (start $4.9 \pm 1.08\text{mm}^2$, end $3.3 \pm 0.67\text{mm}^2$, $p < 0.01$), flattening ratio (start 2.7 ± 0.62 , end 3.1 ± 0.70 , $p = 0.02$). There were no differences seen in the moderate group.

For the thumb opposition there were no significant differences seen in the values obtained from the moderate symptomatic group or the fully symptomatic group.

Table 5.9: Analysis of the difference between the parameters of the median nerve between the start and end positions for the moderate and fully symptomatic groups

Movement	Moderate symptomatic group				Fully symptomatic group			
	Cross-sectional area	Flattening ratio	X co-ordinate	Y co-ordinate	Cross-sectional area	Flattening ratio	X co-ordinate	Y co-ordinate
Finger grip	X	X	X	X	t (df 7) = 3.58, p = < 0.01	X	X	X
Power grip	X	X	X	X	t (df 4) = 2.76, p = < 0.05	t (df 4) = -2.82, p = 0.04	t (df 4) = 5.22, p = < 0.01	X
Pinch grip	X	X	X	X	t (df 4) = 7.15, p = < 0.01	t (df 4) = 3.48, p = 0.02	X	X
Thumb opposition	X	X	X	X	X	X	X	X

5.4.2 Study 2: Discussion

Analysis was performed to investigate if there was any difference in the activity of the median nerve between each hand movements from the moderate and fully symptomatic groups. The data showed no significant differences in the moderate-symptomatic group in all of the movements but the fully-symptomatic group showed significant differences in cross-sectional area between the thumb opposition and the pinch grip.

Analysis of the data was also performed to investigate if there was any difference in the parameters of the median nerve between the start and the end position of each movement. The analysis showed significant differences in the fully-symptomatic group between the values obtained at the start and the end positions for cross-sectional area (during the finger grip, power grip and pinch grip), flattening ratio (during the power grip and pinch grip) and the X co-ordinate (during the power grip) but the thumb opposition showed no differences.

From observations and analysis of the data it appears that the median nerve of the fully-symptomatic group decreased in area (during the finger grip, power grip and pinch grip movements), became flatter (during the power grip and pinch grip) and showed movement slightly towards a radial location (during the power grip).

Tables 5.10 to 5.14 compares the data obtained from the non-symptomatic group with the symptomatic groups for each movement. They give the mean values for area and flattening ratio at the start and end of each movement along with the change during movement. For the X and Y co-ordinates only the change during the movement is

given. The change in cross-sectional area, flattening ratio and X and Y co-ordinate, between the start and the end positions during each movement is also given in Figure 5-4 to 5-7. The data in full for each individual participant is shown in *Appendix F*.

A one-way between-group analysis of variance (ANOVA) followed by Tukey HSD Post hoc statistical test were used to investigate if there was a significant difference in the size, shape and location of the median nerve and how it changed, between the non-symptomatic group and the other symptomatic groups. Significant differences are marked in the tables and figures by an asterisk.

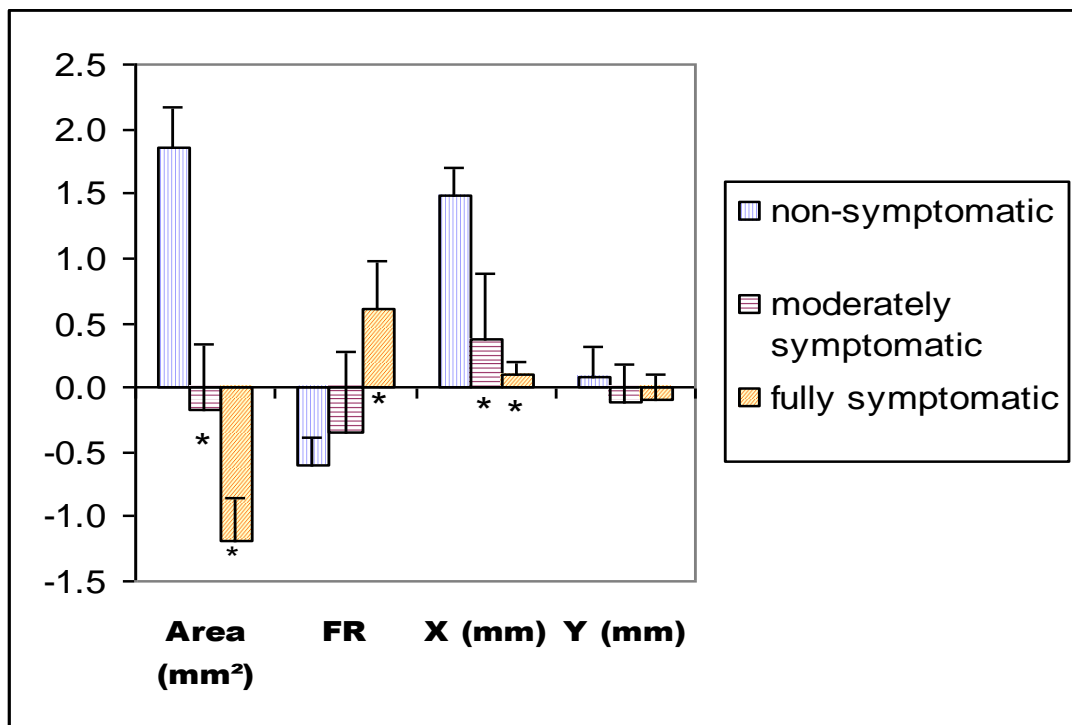
Movement 1: Finger Grip

Table 5.10 shows the data obtained from all groups during the finger grip with Figure 5-4 representing the data in the form of a graph.

Table 5.10: Comparison between participant groups - Parameters of the median nerve during the finger grip movement

Group	Number of participants	Cross-sectional area mm ² mean (SE)			Flattening ratio (FR) mean (SE)			X co-ordinate mm mean (SE)	Y co-ordinate mm mean (SE)
		start	end	change	start	end	change	change	change
Non-symptomatic	7	3.7 (1.34)	5.6 (1.36)	1.9 (0.79)	2.7 (0.80)	2.1 (0.57)	-0.6 (0.53)	1.5 (0.56)	0.1 (0.64)
Moderate symptomatic	4	3.6 (0.72)	3.4 (0.7)0	-0.2* (1.01)	3.0 (1.57)	2.6 (1.05)	-0.4 (1.25)	0.4* (1.03)	-0.1 (0.59)
Fully symptomatic	8	5.1 (1.71)	3.9 (1.01)	-1.2* (0.94)	2.0 (0.75)	2.6 (1.46)	0.6* (1.03)	0.1* (0.24)	-0.1 (0.55)

* statistically significant difference from the non-symptomatic group at $p \leq 0.05$



* statistically significant difference from the non-symptomatic group at $p \leq 0.05$

Figure 5-4: Comparison between participant groups - change in the median nerve during the finger grip movement

The cross-sectional area of the median nerve in the moderate and fully- symptomatic groups decreased during the movement which was significantly different to the non-symptomatic group whose area increased.

The nerve in the non-symptomatic group changed shape becoming rounder, which was significantly different to the fully-symptomatic group which showed very little change, in fact becoming slightly flatter.

Nerve movement along a mediolateral plane was toward the radial side of the wrist in all the groups however the values obtained from the moderate and fully-symptomatic groups were significantly different to those obtained from the non-symptomatic group which showed a greater amount of movement.

No significant differences were seen between the non symptomatic group and the other groups in the change of Y co-ordinate between the groups during the finger grip movement.

Movement 2: Power Grip

Table 5.11 gives the raw data obtained during the power grip for cross-sectional area, flattening ratio, X and Y co-ordinate. Figure 5-5 shows the change in the size, shape and location median nerve during the power grip.

The non-symptomatic group showed an increase in cross-sectional area and became rounder during the power grip, which was significantly different to the nerve in the fully-symptomatic group whose area decreased and became flatter.

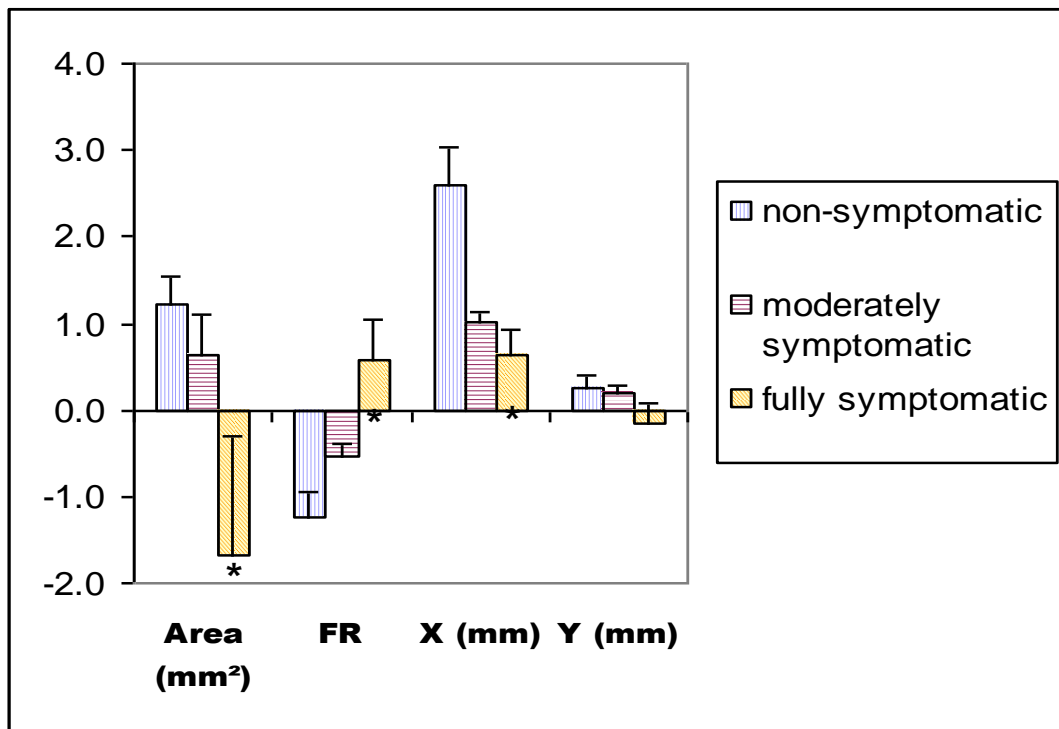
The results show movement of the nerve along the mediolateral plane towards the radial side of the wrist in all groups however the fully-symptomatic group showed significantly less nerve movement, when compared to the non-symptomatic group.

No differences were found between the non-symptomatic group and the other groups for the data collected from the change in Y co-ordinate along the anteroposterior plane during the power grip.

Table 5.11: Comparison between participant groups - Parameters of the median nerve during the power grip movement

Group	Number of participants	Cross-sectional area mm ² mean (SD)			Flattening ratio (FR) mean (SD)			X co-ordinate mm mean (SD)	Y co-ordinate mm mean (SD)
		start	end	change	start	end	change	change	change
Non-symptomatic	6	3.1 (0.51)	4.3 (0.42)	1.2 (0.85)	3.8 (0.67)	2.6 (0.85)	-1.2 (0.78)	2.6 (1.22)	0.2 (0.40)
Moderate symptomatic	3	3.3 (0.20)	4.0 (1.18)	0.7 (1.13)	2.9 (0.67)	2.4 (0.36)	-0.5 (0.31)	1.0 (1.10)	0.2 (0.11)
Fully symptomatic	5	5.2 (1.78)	3.6 (1.02)	-1.6* (1.35)	2.7 (0.48)	3.3 (0.87)	0.6* (0.46)	0.6* (0.27)	-0.2 (0.23)

* statistically significant difference to the non-symptomatic group at $p \leq 0.05$



* statistically significant difference to the non-symptomatic group at $p \leq 0.05$

Figure 5-5: Comparison between participant groups - Parameters of the median nerve during the power grip movement

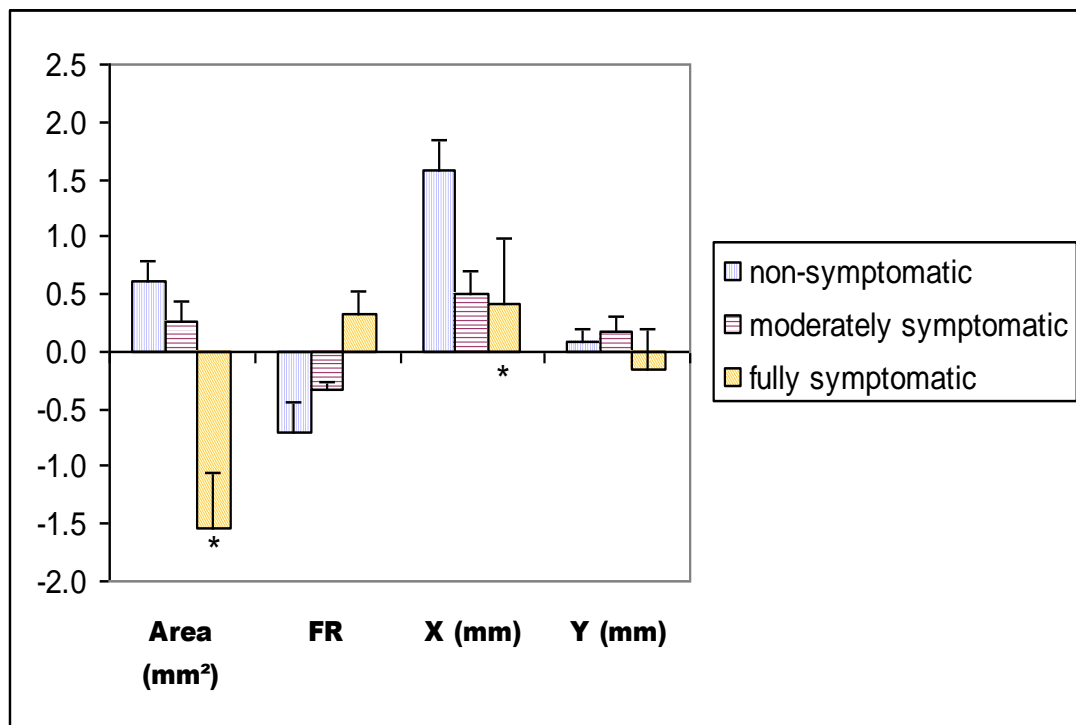
Movement 3: Pinch Grip

Table 5.12 gives the data obtained at the start and end positions of the pinch grip movement for cross-sectional area and flattening ratio, their respective changes during hand activity along with the change in the X and Y co-ordinates giving the mediolateral and anteroposterior movement. Figure 5-6 show the change in the data.

Table 5.12: Comparison between participant groups - Parameters of the median nerve during the pinch grip movement

Group	Number of participants	Cross-sectional area mm ² mean (SD)			Flattening ratio mean (SD)			X co-ordinate mm mean (SD)	Y co-ordinate mm mean (SD)
		start	end	change	start	end	change	change	change
Non-symptomatic	6	4.4 (1.16)	5.0 (1.04)	0.6 (0.44)	2.9 (0.73)	2.5 (0.57)	-0.4 (0.72)	1.6 (0.71)	0.1 (0.27)
Moderate symptomatic	3	3.0 (0.61)	3.2 (0.39)	0.2 (0.97)	2.7 (0.64)	2.3 (0.44)	-0.4 (1.04)	0.5 (0.84)	0.2 (0.30)
Fully symptomatic	5	4.9 (1.08)	3.3 (0.67)	-1.6* (0.49)	2.7 (0.18)	3.0 (0.38)	0.3 (0.21)	0.4* (0.58)	-0.2 (0.36)

* statistically significant difference to the non-symptomatic group at $p \leq 0.05$



* statistically significant difference to the non-symptomatic group at $p \leq 0.05$

Figure 5-6: Comparison between participant groups - Parameters of the median nerve during the pinch grip movement

Analysis of the data showing the change in the median nerve during the pinch grip, showed significant differences in the cross-sectional area between the non-symptomatic and fully-symptomatic groups with the area of the nerve in the non-symptomatic group, increasing while the fully-symptomatic group showed a significant decrease.

There were also significant differences in the X co-ordinate values between the non-symptomatic and the fully-symptomatic groups. These results show that movement along the mediolateral plane was in a radial direction for all the groups however this

movement was significantly less in the fully-symptomatic group when compared to the non-symptomatic group.

No significant differences were seen in the values given for flattening ratio and Y co-ordinate.

Movement 4: Thumb Opposition

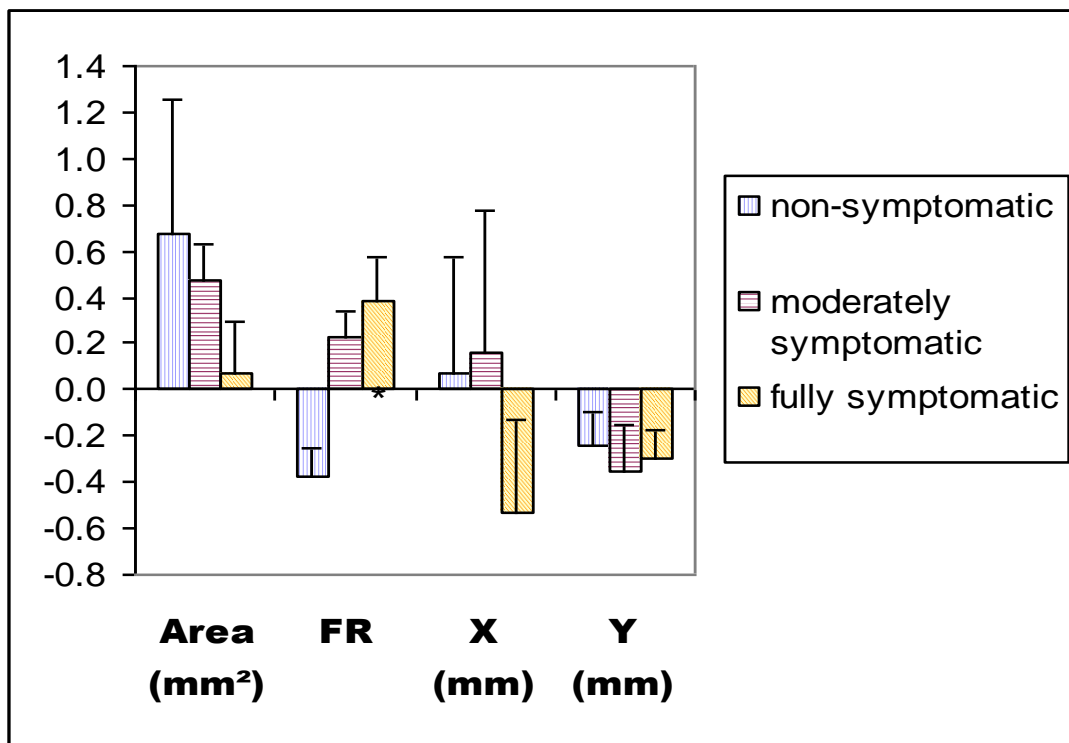
Table 5.14 gives the data obtained from the thumb opposition movement with Figure 5-7 showing the change values in the nerve for all movements.

The data obtained for flattening ratio showed that while the median nerve in the non-symptomatic group became rounder, the nerve in the fully-symptomatic group was significant different and became more flattened. However, no other significant differences were seen for the change in cross-sectional area, X or Y co-ordinate measurements.

Table 5.13: Comparison between participant groups - Parameters of the median nerve during the thumb opposition movement

Group	Number of participants	Cross-sectional area mm ² Mean (SD)			Flattening ratio Mean (SD)			X co-ordinate mm Mean (SD)	Y co-ordinate mm Mean (SD)
		start	end	change	start	end	change	change	change
Non-symptomatic	6	3.9 (1.26)	4.5 (1.48)	0.6 (1.56)	2.9 (0.61)	2.5 (0.65)	-0.4 (0.32)	1.1 (1.34)	-0.3 (0.38)
Moderate symptomatic	3	3.5 (0.33)	3.9 (0.17)	0.4 (0.32)	2.0 (0.33)	2.2 (0.26)	0.2 (0.22)	0.2 (1.25)	-0.4 (0.41)
Fully symptomatic	5	3.6 (1.04)	3.7 (1.10)	0.1 (0.63)	2.7 (0.62)	3.1 (0.70)	0.4* (0.53)	-0.5 (1.12)	-0.3 (0.34)

* statistically significant difference to the non-symptomatic group at $p \leq 0.05$



* statistically significant difference to the non-symptomatic group at $p \leq 0.05$

Figure 5-7: Comparison between participant groups - Parameters of the median nerve during the thumb opposition movement

5.4.3 Discussion

The data obtained for the non-symptomatic group in Study 1 showed that the median nerve increased in area, developed a rounder shape and moved towards the radial side of the wrist during all four movements.

Table 5.15 gives an overall view of the statistically significant differences in the moderate and fully symptomatic groups when compared with the non-symptomatic group.

Table 5.14: Overview of statistically significant differences in the moderate and fully symptomatic groups when compared with the non-symptomatic group

Movements	Moderate symptomatic				Fully symptomatic			
	Cross-sectional area (mm ²)	Flattening ratio	X co-ordinate (mm)	Y co-ordinate (mm)	Cross-sectional area (mm ²)	Flattening ratio	X co-ordinate (mm)	Y co-ordinate (mm)
Finger grip	*Decrease in size	X	*Reduction in radial movement	X	*Decrease in size	*Flatter shape	*Reduction in radial movement	X
Power grip	X	X	X	X	*Decrease in size	*Flatter shape	*Reduction in radial movement	X
Pinch grip	X	X	X	X	*Decrease in size	X	*Reduction in radial movement	X
Thumb opposition	X	X	X	X	X	Flatter shape	X	X

* statistically significant difference to the non-symptomatic group at $p \leq 0.05$ X = not statistically significant

In Study 2 significant differences were seen during the finger grip and power grip movements with the data showing that the nerve in the fully-symptomatic group decreased in area, changed shape by becoming flatter and displayed less movement along the mediolateral X co-ordinate when compared to the non-symptomatic group.

Significant differences were also seen during the pinch grip movement between the non-symptomatic and the fully-symptomatic groups, which showed a decrease in cross sectional area and less movement along the mediolateral plane when compared to the non-symptomatic group.

For the thumb opposition movement, statistically significant differences were only seen in the flattening ratio measurements between the non-symptomatic nerve and fully-symptomatic nerve. The results show the nerve in the fully-symptomatic group becoming more flattened when compared to the non-symptomatic group. Bringing the thumb across the palm involves rotation of the radial and ulna bones in the forearm which results in the wrist deviating from its neutral position. In addition the movement also visibly reduces the size of the wrist, which could result in a decrease in the available space within the carpal tunnel and limit the capacity for change in the nerve. This could explain why significant differences were not as common when compared to the other movements.

The results of Study 1 obtained from the finger, power and precision grip movements suggested that as the digits move from extension at the beginning of the movement to flexion at the end, the median nerve to moves in a radial direction, the cross-sectional area increases and the nerve becomes rounder in shape for non-symptomatic participants. However, the nerve in both the symptomatic groups showed a limited amount of movement along the

mediolateral plane when compared to the non-symptomatic group. It is plausible that the inability of the symptomatic nerve to move to a more radial position within the wrist could explain the decrease in cross sectional area and the increase in flattening.

Greening *et al* (2001) and Erel *et al* (2003) reported on mediolateral movement of the median nerve within the wrist (detailed in *Chapter 2* in sub-section 2.5) but did not investigate the association of this movement with changes in the cross-sectional area or the flattening ratio. In addition, both of these studies obtained measurements from participants while in a supine (lying down) position and studied non-functional hand and wrist movements. This was appropriate for their studies which compared normal median nerve activity with that found in symptomatic participants for the purpose of diagnosing upper limb disorders. However, to investigate median nerve activity during functional hand activity, a seated position using more purposeful movements is likely to produce more realistic results that can be related to work-related behavior.

Therefore due to the unique nature of the aims, methodology and data analysis it is difficult to compare the results obtained in this study with those from previous research. However, despite the differences in methodology, data collection and analysis the findings obtained from Greening *et al* (2001) and Erel *et al* (2003) are consistent with the present study in showing the radial movement of the nerve during hand motion.

5.4.4 Study 2: Conclusions

This study demonstrated the ability of the novel quantification method and ultrasonographic technique to measure the changing parameters of the median nerve using ultrasonography and

to distinguish between the fully-symptomatic and the non-symptomatic nerve. The results suggested that the fully-symptomatic nerve decreased in size, became flatter and displayed a limited movement along the mediolateral plane when compared to the non-symptomatic group during a number of movements.

5.5 Quantifying the Changes in the Dynamics of the Median Nerve throughout the Hand Movements

The aim of this study was to quantify the changing size, shape and location of the median nerve at five intervals throughout hand activity using high resolution ultrasonography.

The five-second ultrasound scans that were recorded from each participant in the previous studies were analyzed further to obtain values at six time points during the movement, representing the start position and 1-second intervals after that time. This data was then processed by subtracting the value obtained at one point from that obtained at the previous point, to show the change in size, shape and location of the nerve at five intervals over the course of each movement.

The methodology used is given in section 5.2 of this chapter and the characteristics from the pool of participants are given in section 5.2. Table 5.16 shows the related number of participants that took part in each movement.

Table 5.15: The number of participants that took part in each movement

Movements	Number of Non-symptomatic Participants	Number of moderate symptomatic participants	Number of fully symptomatic participants
Finger Grip	7	4	8
Power grip	6	3	5
Pinch Grip	6	3	5
Thumb Opposition	6	3	5

5.5.1 Study 3: Results

A one-way between-group analysis of variance (ANOVA) using a Tukey HSD Post hoc statistical test was used to investigate if there was a significant difference between the non-symptomatic group and the other groups at each interval during each of the four movements. Significant differences were accepted when the significant value was equal to or less than 0.05 and are indicated in the tables and figures as an asterisk.

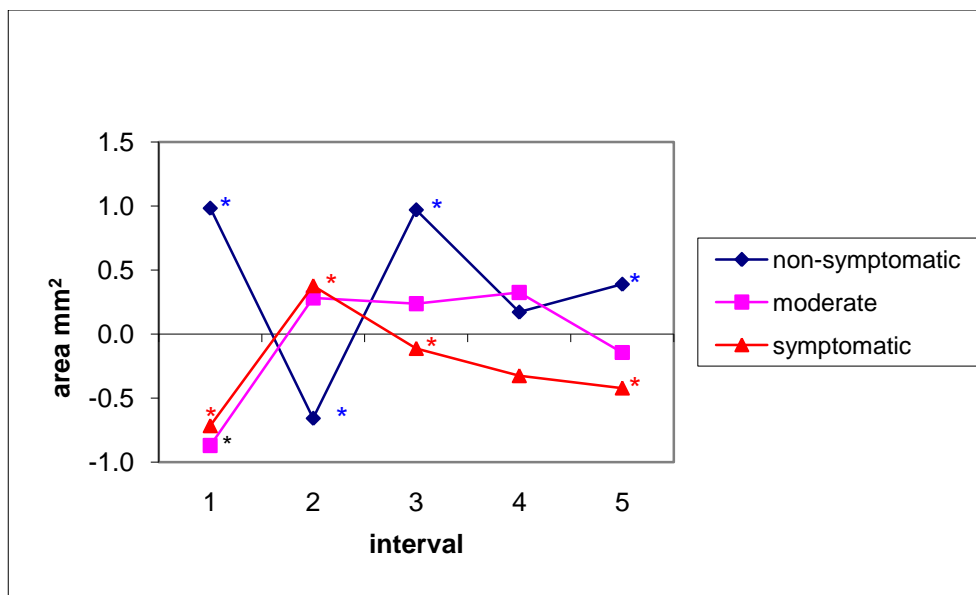
The mean values for each group showing the change in the median nerve over the 5 intervals representing each second of the movement is shown in Tables 5.16 to 5.31 and Figures 5-8 to 5-23. The full values obtained for the processed data is given in *Appendixes G-J*.

Movement 1: finger grip

Table 5.17 gives the mean values for the change in the cross-sectional area of the median nerve at 1-second intervals for each of the groups during the finger grip movement with Figure 5-8 illustrating these changes. The asterisk indicates significant differences between the groups.

Table 5.16: The change in cross-sectional area during the finger grip

	Intervals				
	1	2	3	4	5
Non-Symptomatic Participants					
Mean (mm²)	0.98*	-0.66*	0.97*	0.17	0.39*
SE	1.28	0.58	0.73	0.32	0.29
Moderate symptomatic Participants					
Mean (mm²)	-0.87*	0.28	0.24	0.33	-0.14
SE	0.72	0.33	0.39	0.07	0.61
Fully symptomatic Participants					
Mean (mm²)	-0.72*	0.38*	-0.11*	-0.32	-0.42*
SE	1.00	1.00	0.57	0.56	0.73



* = significant difference of $p \leq 0.05$

Figure 5-8: Change in the cross-sectional area throughout the finger grip movement

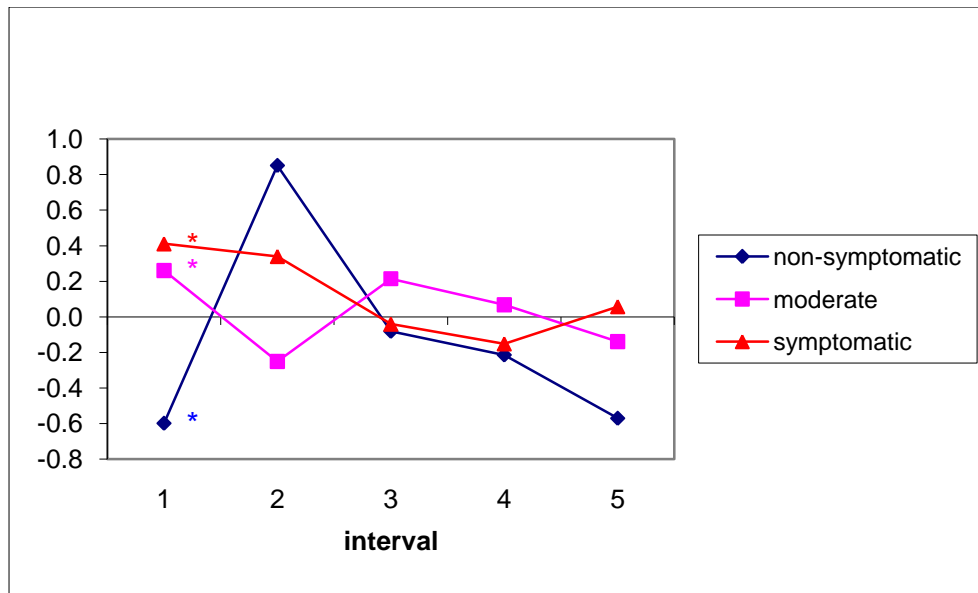
The data shows that the majority of change in cross-sectional area during the finger grip appears at the beginning of the movement in all groups, with relatively less change in nerve behaviour after the 3rd interval.

Statistically significant differences between the non-symptomatic group and the other groups were seen in the 1st interval, where the non-symptomatic group showed an initial increase in nerve area while the moderate and fully symptomatic groups showed a decrease. For the non-symptomatic group over the 2nd interval the nerve decreased in area whereas the fully symptomatic group was significantly different and showed an increase. Significant differences were also seen at the 3rd interval with nerve area in the non-symptomatic group increasing while it decreased in the fully-symptomatic group and the 5th interval where the nerve in the non-symptomatic group ended the movement significantly larger when compared to the fully-symptomatic nerve

Table 5.18 gives the values for the change in the flattening ratio of the median nerve at 1-second intervals for each of the groups during the finger grip movement with Figure 5-9 illustrating these changes.

Table 5.17: The change in flattening ratio during the finger grip

	Intervals				
	1	2	3	4	5
Non-Symptomatic Participants					
Mean	-0.53*	0.85	-0.08	-0.21	-0.57
SE	0.63	0.74	0.64	1.20	0.81
Moderate symptomatic Participants					
Mean	0.26*	-0.25	0.21	0.07	-0.14
SE	0.28	0.96	0.48	0.38	0.91
Fully symptomatic Participants					
Mean	0.41*	0.34	-0.04	-0.15	0.06
SE	0.25	0.34	0.45	0.71	1.09



* = significant difference of $p \leq 0.05$

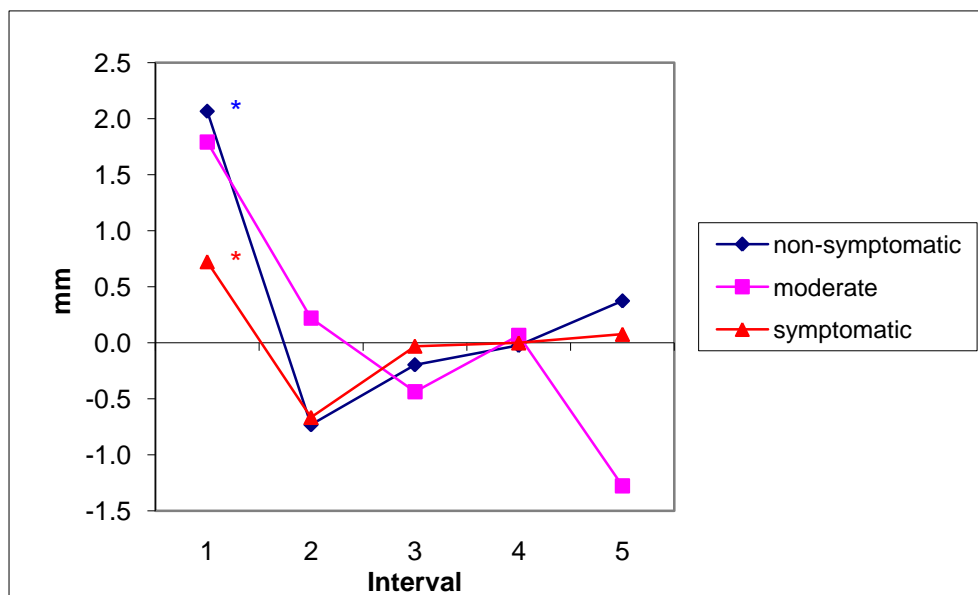
Figure 5-9: Change in the flattening ratio throughout the finger grip

The most apparent change in flattening ratio during the finger grip appears to happen at the beginning of the movement in all three groups. Statistically significant differences between the non-symptomatic group and the other groups were seen at the first interval only, with the non symptomatic nerve becoming more circular in shape whereas the moderate and fully-symptomatic groups showed the nerve becoming more flattened.

Table 5.19 and Figure 5-10 show the change in the X co-ordinate giving the mediolateral movement of the median nerve at one second intervals for each of the groups, during the finger grip movement.

Table 5.18: The change in X co-ordinate during the finger grip

	Intervals				
	1	2	3	4	5
Non-Symptomatic Participants					
Mean	2.07*	-0.82	-0.20	-0.02	0.37
SE	0.91	0.83	0.73	0.55	0.59
Moderate symptomatic Participants					
Mean	1.79	0.22	-0.44	0.07	-1.28
SE	0.56	0.69	0.51	0.25	2.10
Fully symptomatic Participants					
Mean	0.72*	-0.67	-0.03	0.00	0.08
SE	0.23	0.56	0.52	0.48	0.55



* = significant difference of $p \leq 0.05$

Figure 5-10: Change in the X co-ordinate throughout the finger grip

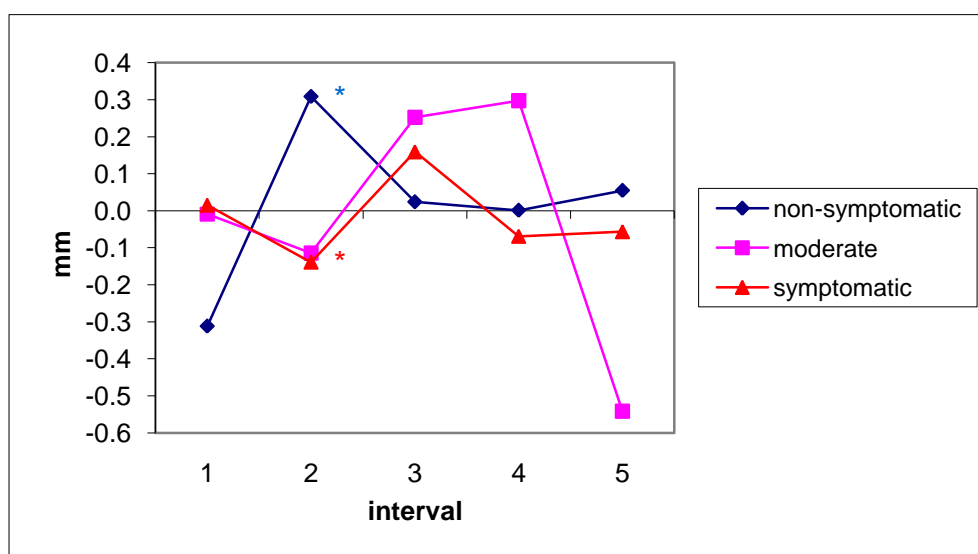
The data shows that the majority of nerve movement occurs in the 1st and 2nd interval with radial movement seen in the 1st interval, ulnar movement in the 2nd interval and a reduction in activity after the 3rd interval. However statistically significant differences were seen between the non-symptomatic group and the fully symptomatic group in the 1st interval only, with the

non-symptomatic group showing a greater amount of movement in a radial direction compared to the fully symptomatic group.

Table 5.20 and Figure 5-11 shows the change in the Y co-ordinate giving the anteroposterior movement of the median nerve at one second intervals for each of the groups, during the finger grip movement.

Table 5.19: The change in Y co-ordinate during the finger grip

	Intervals				
	1	2	3	4	5
Non-Symptomatic Participants					
Mean	-0.31	0.31*	0.02	0.00	0.05
SE	0.20	0.27	0.15	0.28	0.35
Moderate symptomatic Participants					
Mean	-0.01	-0.11	0.25	0.30	-0.54
SE	0.60	0.29	0.44	0.19	0.72
Fully symptomatic Participants					
Mean	0.02	-0.14*	0.16	-0.07	-0.06
SE	0.33	0.36	0.30	0.15	0.53



* = significant difference of $p \leq 0.05$

Figure 5-11: Change in the Y co-ordinate throughout the finger grip

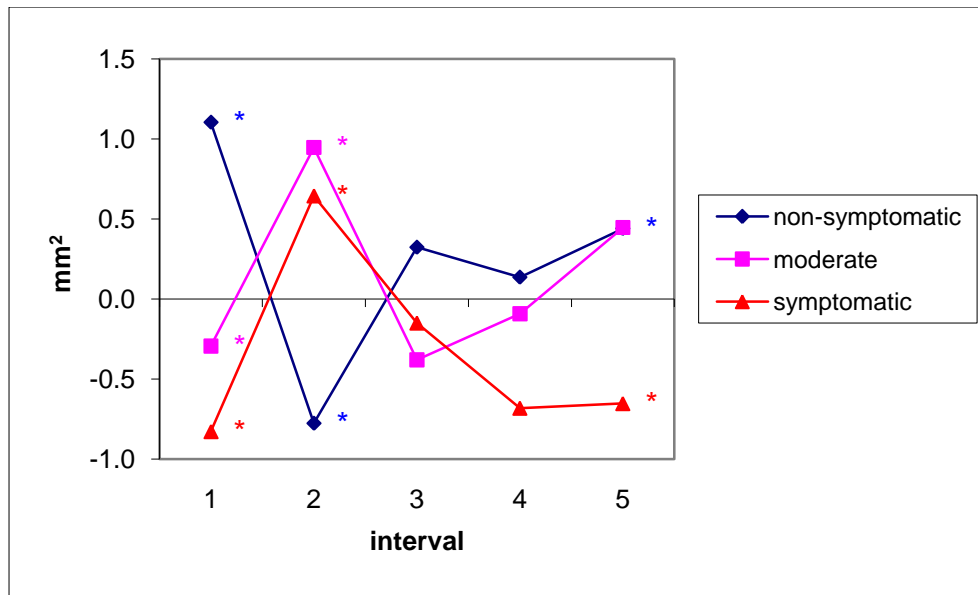
Statistically significant differences were seen at the 2nd interval only, where the non-symptomatic group showed movement towards the anterior surface of the wrist whereas the fully symptomatic group showed movement towards the posterior of the wrist.

Movement 2: power grip

Table 5.21 and Figure 5-12 shows the change in the cross sectional area of the median nerve at one second intervals for each of the groups during the power grip movement.

Table 5.20: The change in cross-sectional area during the power grip

	Intervals				
	1	2	3	4	5
Non-Symptomatic Participants					
Mean	1.10*	-0.78*	0.32	0.14	0.44*
SE	0.33	1.04	0.54	0.25	0.37
Moderate symptomatic Participants					
Mean	-0.29*	0.95*	-0.38	-0.09	0.45
SE	0.38	0.28	1.23	0.68	0.88
Fully symptomatic Participants					
Mean	-0.69*	0.54*	-0.12	-0.57	-0.54*
SE	0.74	0.48	0.93	0.85	0.71



* = significant difference of $p \leq 0.05$

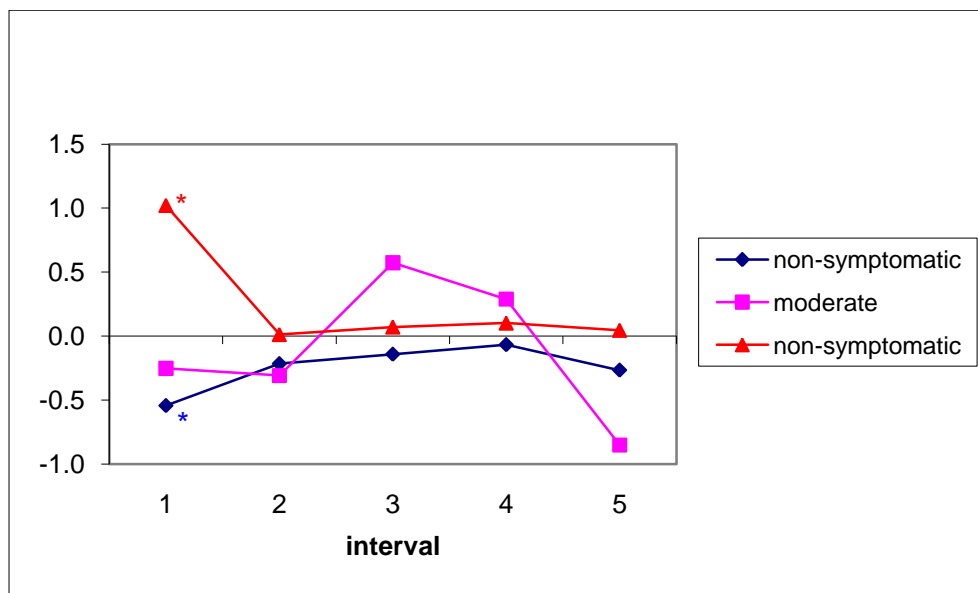
Figure 5-12: Change in the cross-sectional area throughout the power grip

The data shows that the majority of change in nerve area appears at the beginning of the movement with relatively less activity after 3rd interval. The non-symptomatic group showed an initial increase in area which was significantly different to the moderate and fully symptomatic groups, both showing an initial decrease. At the 2nd interval the non-symptomatic group decreased in area which was significantly different to the moderate and the fully- symptomatic groups which showed an increase. At the last interval the non-symptomatic nerve showed a significant increase in area when compared to the fully-symptomatic nerve.

Table 5.22 and Figure 5-13 shows the change in flattening ratio of the median nerve at one second intervals for each of the groups during the power grip movement.

Table 5.21: The change in flattening ratio area during the power grip

	Intervals				
	1	2	3	4	5
Non-Symptomatic Participants					
Mean	-0.54*	-0.22	-0.14	-0.07	-0.27
SE	0.38	0.52	0.42	0.28	0.31
Moderate symptomatic Participants					
Mean	-0.25	-0.31	0.57	0.29	-0.85
SE	0.69	0.33	0.37	0.28	0.32
Fully symptomatic Participants					
Mean	1.02*	0.01	0.07	0.10	0.05
SE	1.50	0.37	0.37	0.48	0.76



* = significant difference of $p \leq 0.05$

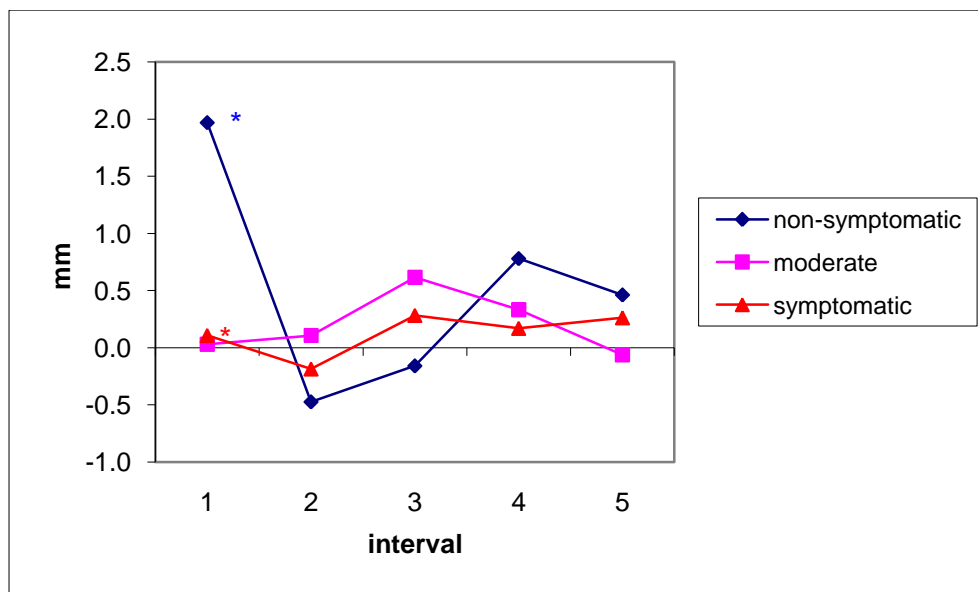
Figure 5-13: Change in the flattening ratio throughout the power grip

Statistically significant differences between the non-symptomatic and the fully-symptomatic groups were seen at the first interval only, with the non symptomatic group showing the nerve became more circular in shape whereas the fully-symptomatic group showed the nerve became more flattened nerve.

Table 5.22 and Figure 5-14 shows the change in the medial-lateral X co-ordinate of the median nerve at one second intervals for each of the groups during the power grip movement.

Table 5.22: The change in X co-ordinate during the power grip

	Intervals				
	1	2	3	4	5
Non-Symptomatic Participants					
Mean	1.80*	-0.47	-0.16	0.78	0.46
SE	0.86	1.34	0.61	1.46	1.06
Moderate symptomatic Participants					
Mean	0.03	0.11	0.62	0.33	-0.06
SE	0.87	0.91	0.86	0.99	0.12
Fully symptomatic Participants					
Mean	0.11*	-0.18	0.28	0.17	0.26
SE	0.80	0.89	0.55	0.51	0.91



* = significant difference of $p \leq 0.05$

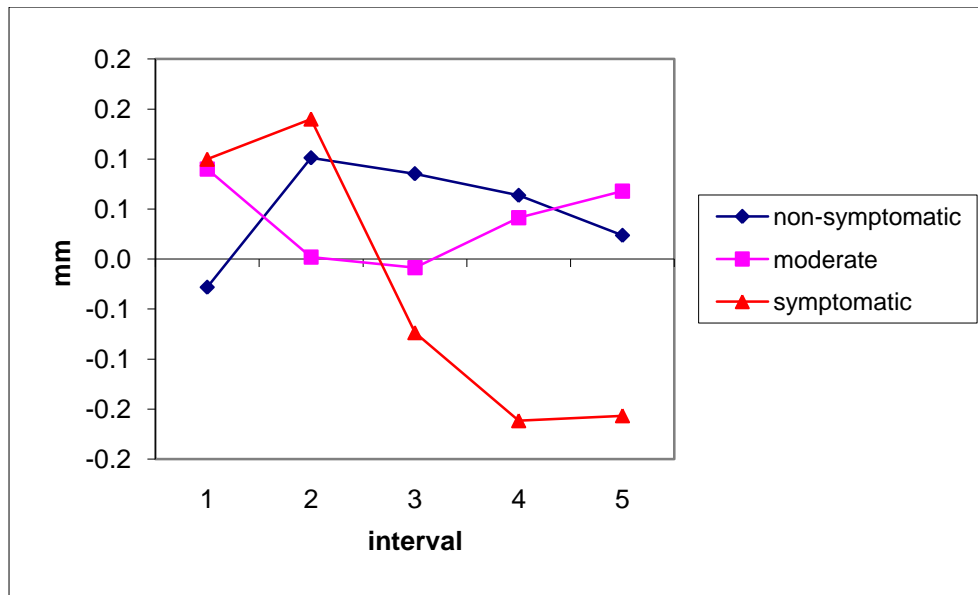
Figure 5-14: Change in the X co-ordinate throughout the power grip

Statistically significant differences were only seen at the 1st interval between the non-symptomatic group which showed movement in a radial direction and the fully symptomatic group which showed a relatively limited amount of movement.

Table 5.22 and Figure 5-15 show the change in the anteroposterior Y co-ordinate of the median nerve at one second intervals for each of the groups during the power grip movement.

Table 5.23: The change in Y co-ordinate during the power grip

	Intervals				
	1	2	3	4	5
Non-Symptomatic Participants					
Mean	-0.03	0.10	0.09	0.06	0.02
SE	0.26	0.26	0.33	0.18	0.17
Moderate symptomatic Participants					
Mean	0.09	0.00	-0.01	0.04	0.07
SE	0.10	0.50	0.42	0.13	0.23
Fully symptomatic Participants					
Mean	0.10	0.14	-0.07	-0.16	-0.16
SE	0.48	0.40	0.13	0.14	0.36



* = significant difference of $p \leq 0.05$

Figure 5-15: Change in the Y co-ordinate throughout the power grip

Analysis of the processed data giving the change in Y co-ordinate values showed no similar pattern of change and no significant differences between the groups.

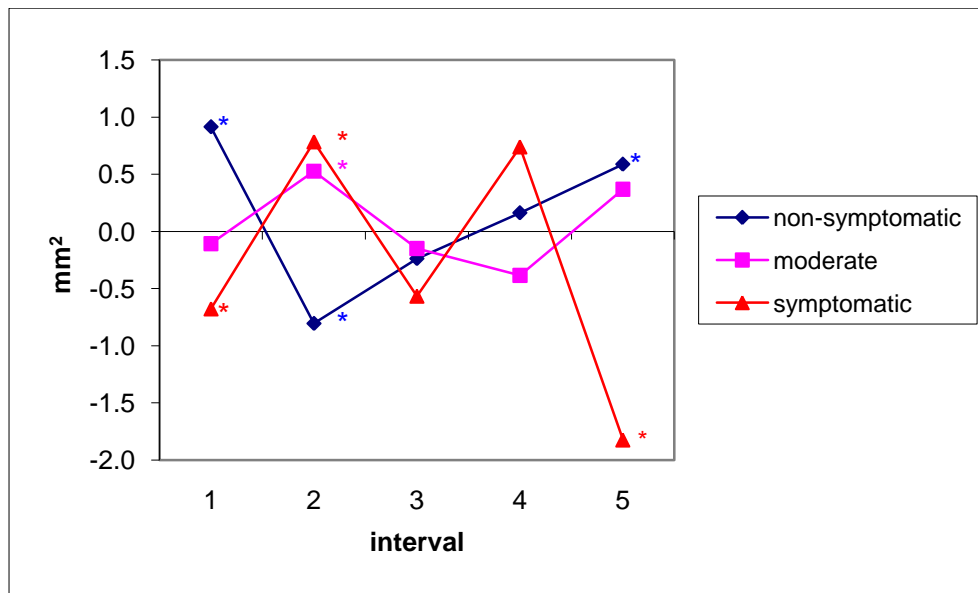
Movement 3: pinch grip

Table 5.24 and Figure 5-16 shows the change in the cross-sectional area of the median nerve at one second intervals for each of the groups during the pinch grip movement.

Table 5.24: The change in cross-sectional area during the pinch grip

	Intervals				
	1	2	3	4	5
Non-Symptomatic Participants					
Mean	0.92*	-0.80*	-0.24	0.16	0.59*
SE	0.78	0.43	0.21	0.27	1.21
Moderate symptomatic Participants					
Mean	-0.11	0.53*	-0.15	-0.38	0.37
SE	1.17	0.12	0.30	0.27	0.28
Fully symptomatic Participants					
Mean	-0.68*	0.78*	-0.57	0.74	-1.82*

SE	0.74	0.91	1.40	0.61	1.59
----	------	------	------	------	------



* = significant difference of $p \leq 0.05$

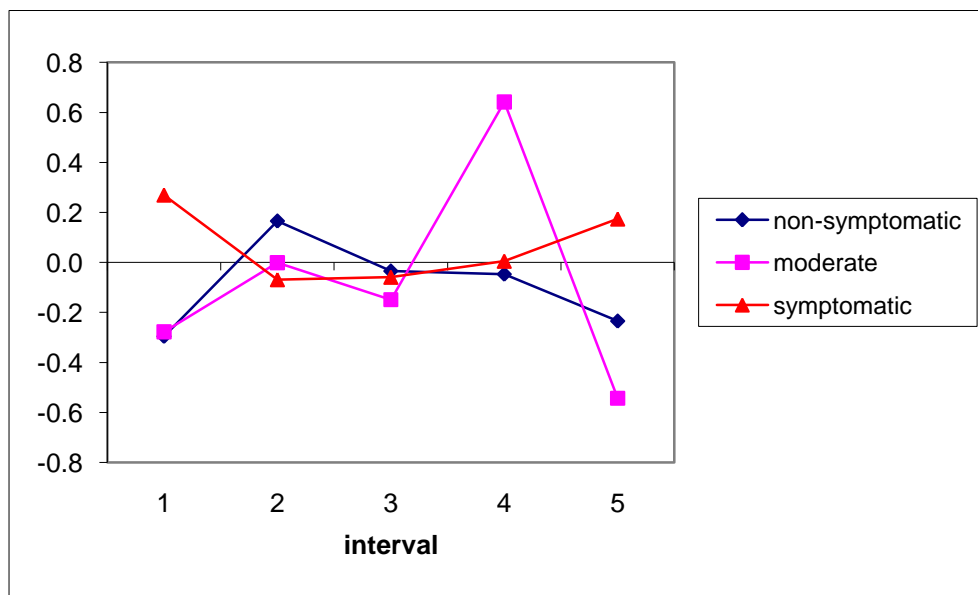
Figure 5-16: Change in cross-sectional area throughout the pinch grip

During the 1st interval the non symptomatic group showed an initial increase in area which was significantly different to the fully-symptomatic group whose nerve area decreased. The non-symptomatic group at the 2nd interval decreased in area whereas the moderate and the fully-symptomatic group were significantly different and showed an increase. The last interval shows that the non-symptomatic group was significantly larger in area than the fully symptomatic group.

Table 5.25 and Figure 5-17 shows the change in flattening ratio of the median nerve at one second intervals for each of the groups during the pinch grip movement.

Table 5.25: The change in flattening ratio during the pinch grip

	Intervals				
	1	2	3	4	5
Non-Symptomatic Participants					
Mean	-0.30	0.17	-0.03	-0.05	-0.23
SE	0.46	0.28	0.38	0.33	0.49
Moderate symptomatic Participants					
Mean	-0.28	0.00	-0.15	0.64	-0.54
SE	0.89	0.28	0.30	0.48	0.54
Fully symptomatic Participants					
Mean	0.27	-0.07	-0.06	0.01	0.17
SE	0.34	0.39	0.55	0.32	0.45



* = significant difference of $p \leq 0.05$

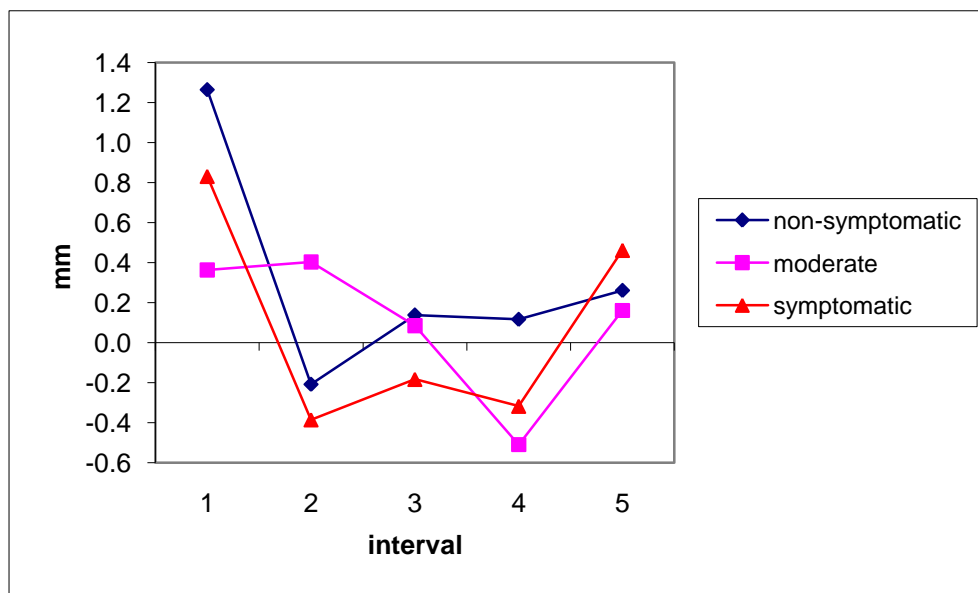
Figure 5-17: Change in the flattening ratio during the pinch grip

Analysis of the processed data giving the change in flattening ratio during the pinch grip showed no significant differences between the non-symptomatic group and the other groups throughout the movement.

Table 5.26 and Figure 5-18 shows the change in the mediolateral X co-ordinate of the median nerve at one second intervals for each of the groups during the pinch grip movement.

Table 5.26: The change in X co-ordinate during the pinch grip

	Intervals				
	1	2	3	4	5
Non-Symptomatic Participants					
Mean	1.26	-0.21	0.14	0.12	0.26
SE	0.83	0.25	0.44	0.30	0.44
Moderate symptomatic Participants					
Mean	0.36	0.40	0.08	-0.51	0.16
SE	0.64	0.44	0.55	0.66	0.70
Fully symptomatic Participants					
Mean	0.83	-0.39	-0.18	-0.32	0.46
SE	0.61	0.62	0.29	0.36	0.42



* = significant difference of $p \leq 0.05$

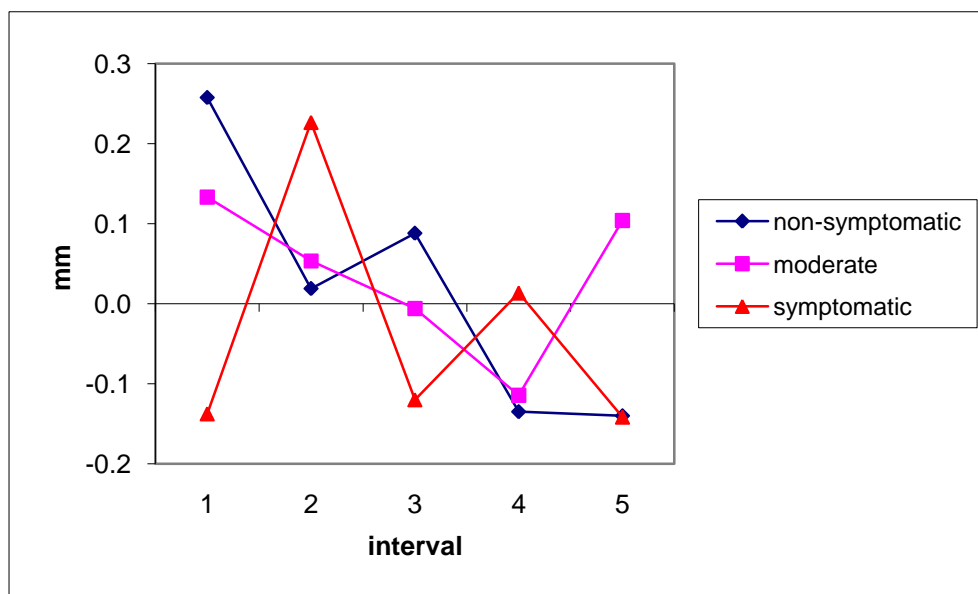
Figure 5-18: Change in the X co-ordinate throughout the pinch grip

Analysis of the data showed no significant differences between the groups for the X co-ordinate parameter.

Table 5.27 and Figure 5-19 show the change in the anteroposterior Y co-ordinate of the median nerve at one second intervals for each of the groups during the pinch grip movement.

Table 5.27: The change in Y co-ordinate during the pinch grip

	Intervals				
	1	2	3	4	5
Non-Symptomatic Participants					
Mean	0.26	0.02	0.09	-0.14	-0.14
SE	0.53	0.13	0.20	0.24	0.41
Moderate symptomatic Participants					
Mean	0.13	0.05	-0.01	-0.11	0.10
SE	0.37	0.25	0.28	0.31	0.12
Fully symptomatic Participants					
Mean	-0.14	0.23	-0.12	0.01	-0.14
SE	0.28	0.14	0.18	0.11	0.25



* = significant difference of $p \leq 0.05$

Figure 5-19: Change in the Y co-ordinate throughout the pinch grip

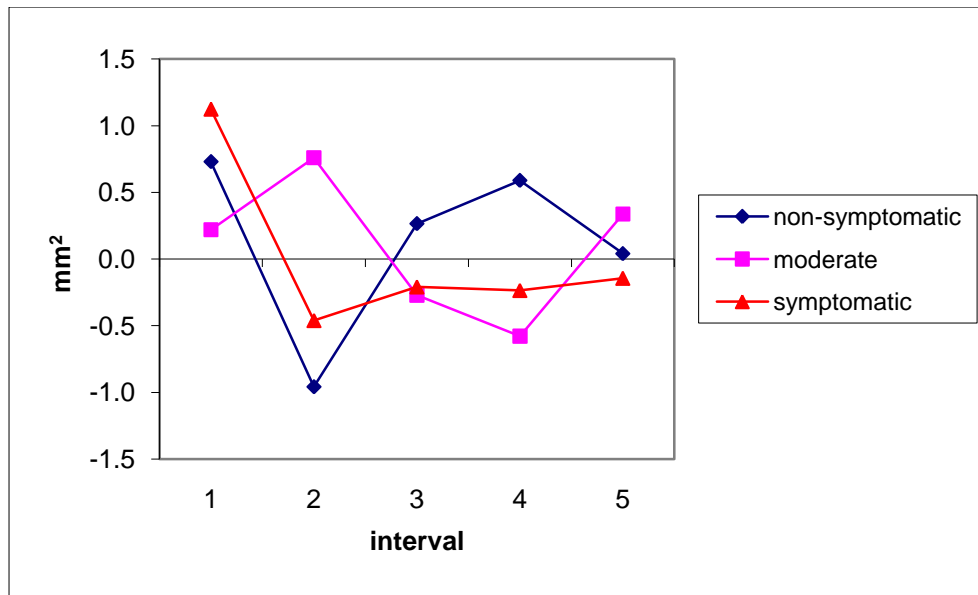
Analysis of the processed data giving the change in location of the median nerve along an anteroposterior Y co-ordinate during the pinch grip showed no significant differences between the groups.

Movement 4: Thumb Opposition

Table 5.28 and Figure 5-20 shows the change in the cross-sectional area of the median nerve at one second intervals for each of the groups during the thumb opposition movement.

Table 5.28: The change in cross-sectional area during the thumb opposition

	Intervals				
	1	2	3	4	5
Non-Symptomatic Participants					
Mean	0.73	-0.96	0.27	0.59	0.04
SE	0.84	1.10	0.59	0.30	0.34
Moderate symptomatic Participants					
Mean	0.22	0.76	-0.27	-0.58	0.34
SE	1.29	0.51	1.08	0.30	0.61
Fully symptomatic Participants					
Mean	1.12	-0.46	-0.21	-0.24	-0.14
SE	0.65	0.65	0.82	0.84	0.83



* = significant difference of $p \leq 0.05$

Figure 5-20: Change in the cross-sectional area throughout the thumb opposition

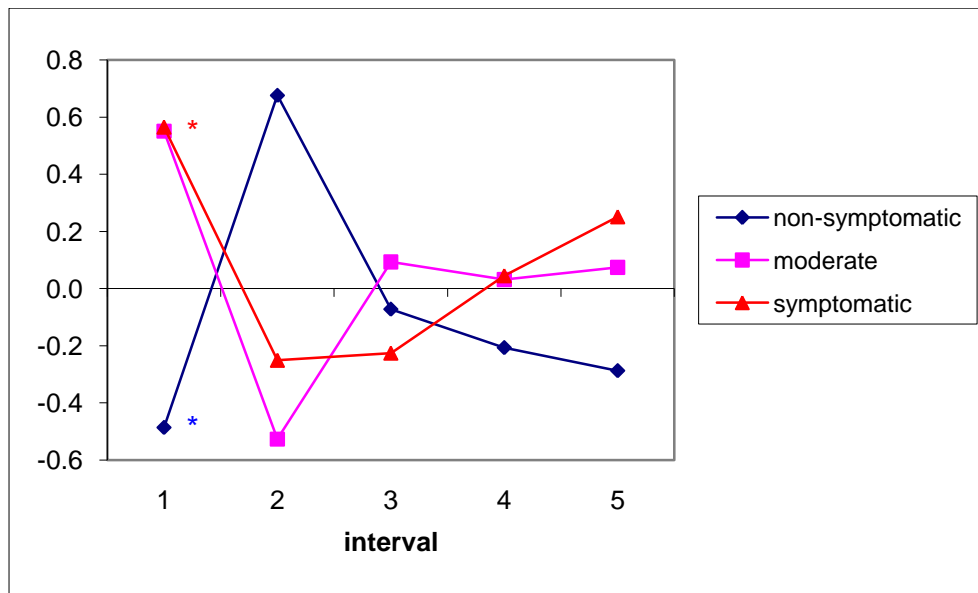
Analysis of the data showed no statistically significant differences between the groups in cross-sectional area.

Table 5.29 and Figure 5-21 shows the change in flattening ratio of the median nerve at one second intervals for each of the groups during the thumb opposition movement.

Table 5.29: The change in flattening ratio during the thumb opposition

	Intervals				
	1	2	3	4	5
Non-Symptomatic Participants					
Mean	-0.49*	0.68	-0.07	-0.21	-0.29
SE	0.49	0.61	0.36	0.51	0.49
Moderate symptomatic Participants					
Mean	0.55*	-0.53	0.09	0.03	0.07
SE	0.18	0.43	0.16	0.21	0.01
Fully symptomatic Participants					
Mean	0.57*	-0.25	-0.23	0.05	0.25

SE	0.13	0.48	0.58	0.46	0.40
----	------	------	------	------	------



* = significant difference of $p \leq 0.05$

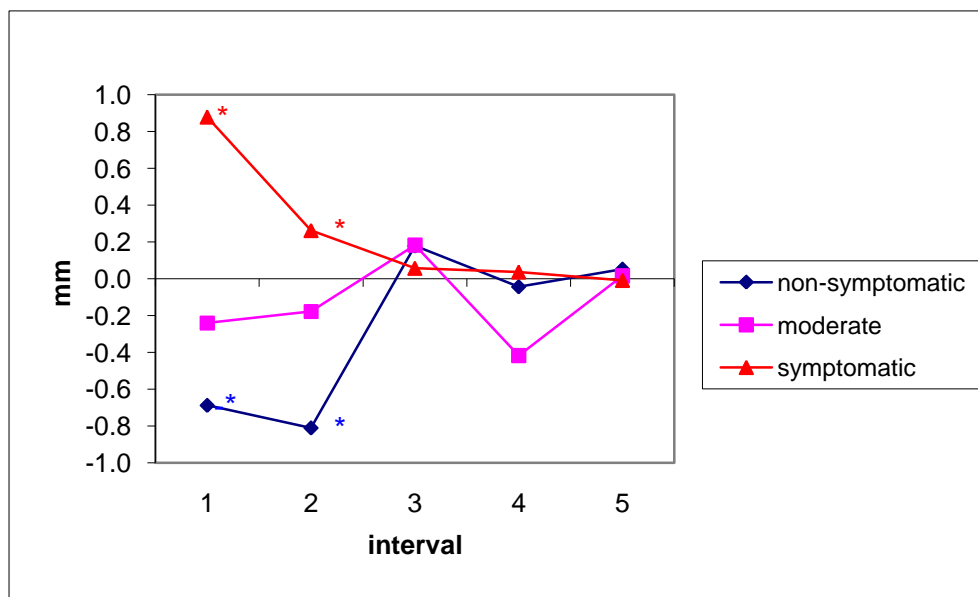
Figure 5-21: Change in flattening ration throughout the thumb opposition

Statistically significant differences were seen at the 1st interval only, with the non-symptomatic becoming rounder whereas the moderate and fully symptomatic nerve became more flattened.

Table 5.30 and Figure 5-22 shows the change in mediolateral movement along the X coordinate of the median nerve at one second intervals for each of the groups during the thumb opposition movement.

Table 5.30: The change in X co-ordinate during the thumb opposition

	Intervals				
	1	2	3	4	5
Non-Symptomatic Participants					
Mean	-0.69*	-0.81*	0.18	-0.04	0.05
SE	0.49	0.77	0.43	0.36	0.23
Moderate symptomatic Participants					
Mean	-0.24	-0.18	0.18	-0.42	0.02
SE	1.82	0.55	0.56	0.57	0.80
Fully symptomatic Participants					
Mean	0.88*	0.26*	0.06	0.04	-0.01
SE	0.73	0.34	0.53	0.41	0.78



* = significant difference of $p \leq 0.05$

Figure 5-22: Change in X co-ordinate during thumb opposition

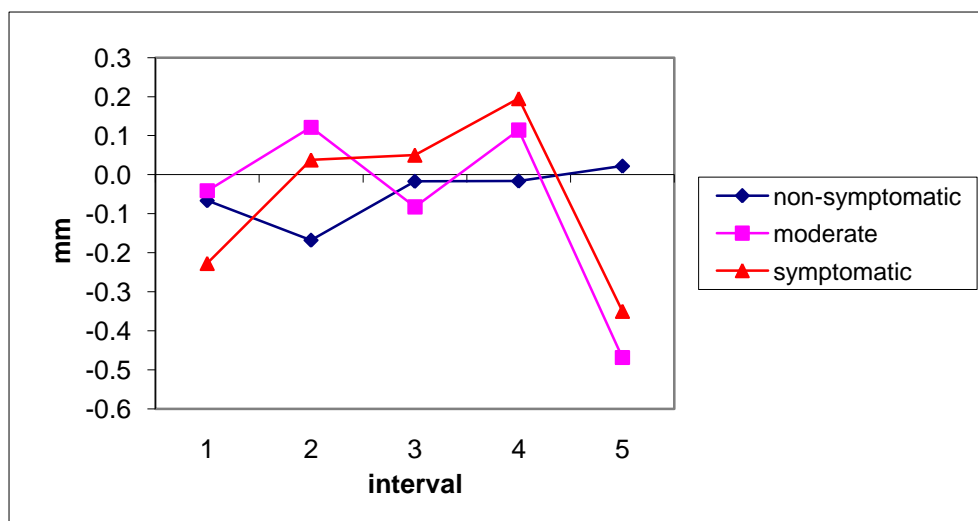
The majority of nerve activity occurs at the beginning of the movement, with statistically significant differences seen in the 1st interval between the non-symptomatic nerve which moved ulnar direction and the fully-symptomatic group which moved in a radial direction. At the 2nd interval both of these groups moved to a more ulnar position however the non-

symptomatic group's location was further towards the ulnar side of the hand when compared to the fully symptomatic group.

Table 5.31 and Figure 5-23 shows the change in anteroposterior movement along the Y co-ordinate of the median nerve at one second intervals for each of the groups during the thumb opposition movement.

Table 5.31: The change in Y co-ordinate during the thumb opposition

	Intervals				
	1	2	3	4	5
Non-Symptomatic Participants					
Mean	-0.07	-0.17	-0.02	-0.02	0.02
SE	0.35	0.34	0.21	0.18	0.15
Moderate symptomatic Participants					
Mean	-0.04	0.12	-0.08	0.11	-0.47
SE	0.07	0.16	0.34	0.12	0.72
Fully symptomatic Participants					
Mean	-0.23	0.04	0.05	0.20	-0.35
SE	0.31	0.19	0.25	0.26	0.46



* = significant difference of $p \leq 0.05$

Figure 5-23: Change in Y co-ordinate throughout the thumb opposition

Analysis of the data showed no significant differences between the groups in the values obtained for the Y co-ordinate.

5.5.2 Study 3: Discussion

Tables 5.32 to 5.35 give an overview of the significant differences between the groups for each parameter during each movement. 'X' indicates no statistically significant difference.

Table 5.32: An overview of the significant differences between the groups for the finger grip

Finger Grip		Cross-sectional area (mm ²)					Flattening ratio					X co-ordinate (mm)					Y co-ordinate (mm)				
Groups	Intervals	1	2	3	4	5	1	2	3	4	5	1	2	3	4	5	1	2	3	4	5
Non-symptomatic		Increase in area	Decrease in area	Increase in area	X	Increase in area	Less flattened	X	X	X	X	More radial movement	X	X	X	X	X	X	X	X	X
Moderate symptomatic		Decrease in area	X	X	X	X	More flattened	X	X	X	X	X	X	X	X	X	X	X	X	X	X
Fully symptomatic		Decrease in area	Increase in area	Decrease in area	X	Decrease in area	More flattened	X	X	X	X	Less radial movement	X	X	X	X	X	X	X	X	X

Table 5.33: An overview of the significant differences between the groups for the power grip

Power Grip		Cross-sectional area (mm ²)					Flattening ratio					X co-ordinate (mm)					Y co-ordinate (mm)				
Groups	Intervals	1	2	3	4	5	1	2	3	4	5	1	2	3	4	5	1	2	3	4	5
Non-symptomatic		Increase in area	Decrease in area	X	X	Increase in area	Less flattened	X	X	X	X	More radial movement	X	X	X	X	X	X	X	X	X
Moderate symptomatic		Decrease in area	Increase in area	X	X	X	X	X	X	X	X	X	X	X	X	X	X	X	X	X	X
Fully symptomatic		Decrease in area	Increase in area	X	X	Decrease in area	More flattened	X	X	X	X	Less radial movement	X	X	X	X	X	X	X	X	X

Table 5.34: An overview of the significant differences between the groups for the pinch grip

Pinch Grip		Cross-sectional area (mm ²)					Flattening ratio					X co-ordinate (mm)					Y co-ordinate (mm)				
Groups	Intervals	1	2	3	4	5	1	2	3	4	5	1	2	3	4	5	1	2	3	4	5
Non-symptomatic		Increase in area	Decrease in area	X	X	Increase in area	X	X	X	X	X	X	X	X	X	X	X	X	X	X	X
Moderate symptomatic		X	X	X	X	X	X	X	X	X	X	X	X	X	X	X	X	X	X	X	X
Fully symptomatic		Decrease in area	Increase in area	X	X	Decrease in area	X	X	X	X	X	X	X	X	X	X	X	X	X	X	X

Table 5.35: An overview of the significant differences between the groups for the thumb opposition

Thumb Opposition		Cross-sectional area (mm ²)					Flattening ratio					X co-ordinate (mm)					Y co-ordinate (mm)				
Groups	Intervals	1	2	3	4	5	1	2	3	4	5	1	2	3	4	5	1	2	3	4	5
Non-symptomatic		X	X	X	X	X	Less flattened	X	X	X	X	X	X	X	X	X	X	X	X	X	X
Moderate symptomatic		X	X	X	X	X	X	X	X	X	X	X	X	X	X	X	X	X	X	X	X
Fully symptomatic		X	X	X	X	X	More flattened	X	X	X	X	X	X	X	X	X	X	X	X	X	X

Analysis of the data showed that most of the statistically significant differences between the non-symptomatic groups and the other groups appeared in the first few seconds of the movement, with less activity seen after interval 3.

Figure 5-24 shows a typical example of the change in the median nerve during physical movement of the hand from a non-symptomatic participant (a) and from a fully-symptomatic participant (b).

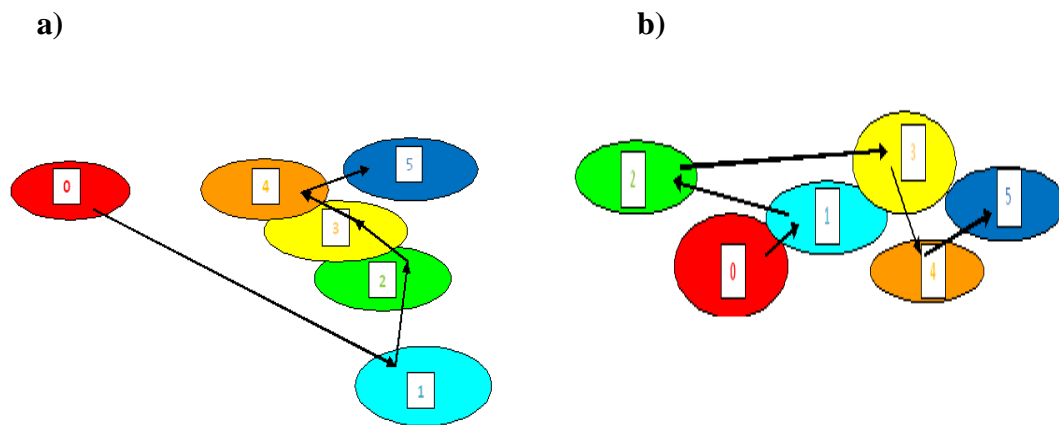


Figure 5-24: The typical movement of the median nerve during hand movement
a) non-symptomatic participant b) fully-symptomatic participant

In the 1st second of the finger grip the non-symptomatic nerve moved towards the radial side of the wrist, increased in area and became rounder. This showed a statistically significant difference to the symptomatic nerve which moved to a less radial position, decreased in area and became flatter. In the 2nd second the opposite happened in both groups and these changes reversed again at the 3rd second but significant differences were only seen in the values obtained for cross-sectional area at both these intervals.

During the 1st interval of the power grip the non-symptomatic nerve moved towards the radial side of the wrist, increased in area with the shape becoming more circular. This was significantly different to the symptomatic group which showed less movement along the X co-ordinate when compared to the non-symptomatic group, a decrease in area and a more flattened shape. Significant differences were also seen in cross sectional area at the 2nd interval with the non-symptomatic group showing an increase in cross-sectional area, whereas the symptomatic group showed a decrease.

For the pinch grip significant differences were seen in the change in cross-sectional area in the 1st and 2nd interval. During the 1st interval the non-symptomatic nerve increased in area, while the symptomatic group showed a decrease and at the 2nd interval the non-symptomatic group decreased, while it increased in the symptomatic group.

The thumb opposition movement showed significant differences at the 1st and 2nd interval in X co-ordinate and flattening ratio values between the non-symptomatic and symptomatic groups. In the 1st second the non-symptomatic nerve moved towards an ulnar position and became rounder whereas the fully-symptomatic nerve moved to a more radial position and became flatter. At the 2nd interval the non-symptomatic group moved to an even more ulna location and became flatter while the symptomatic group moved to a radial position and became rounder.

The pattern of change seen in the thumb opposition movement is not consistent with the other movements and could be the consequence of the movement itself. In the finger grip, power grip and pinch grip movements the wrist was static and not affected

by the activity of the digits. However, in the thumb opposition movement, as the thumb crosses the palm and lower arm rotation of the radial and ulna bones occurs, wrist size is visibly reduced. The reduction in wrist size due to lower arm rotation could restrict the space available to the internal structures of the carpal tunnel. This would explain the limited amount of the activity seen in the median nerve when compared to the other movements and the shape of the nerve becoming flatter.

5.5.3 Study 3: Conclusion

This study showed that the quantification method and ultrasonographic technique can be used to study the changing size, shape and location of the median nerve within the wrist as it progresses through a number of functional hand movements. In addition, it can distinguish between normal nerve function and that found in participants symptomatic of a median nerve disorder using a number of parameters.

5.6 Conclusions of Experimental Chapter

The experimental studies showed that the quantification method and ultrasonographic technology could measure the change in the parameters of median nerve activity during functional hand movements. They also found that the methodology could distinguish between the non-symptomatic group and the other groups using the values obtained from the changing parameters. However the study found that the thumb opposition movement was significantly different to the other movements which could be due to lower arm rotation and the involvement of the wrist in the movement.

6. Discussion

In recent years, ultrasonographic technology has advanced and it now allows for the dynamic imaging of the anatomical activity of the median nerve within the carpal tunnel during physical movement of the hand. Nevertheless, dynamic ultrasonographic imaging is still a relatively new application and an unexplored tool not only for the study of normal median nerve function but also the differences found in nerves symptomatic of median nerve dysfunction and the associated WRULD.

This chapter addresses the research aims proposed in this PhD study. The overall aim was to use ultrasonography to investigate the behaviour of the median nerve during functional hand movement. The objectives used to achieve the aims were;

- To establish ultrasonographic techniques for the dynamic imaging of the median nerve during physical hand movement
- To create an analytical method to quantify the changing parameters of the normal functioning median nerve during physical movement
- To use the novel quantification method to quantify the changing parameters of the symptomatic median nerve
- To investigate if the quantification method and the ultrasonographic technique can distinguish between a normal functioning median nerve and that of a symptomatic nerve.

To address these aims a calibration of procedures for the use of the DIASUS ultrasound equipment was established to identify ideal scanning and measurement outputs, followed by a series of experiments that were conducted to assess activity of the median nerve under different conditions.

This chapter discusses the reasoning behind the use of ultrasonography for this research along with the experimental studies and the key findings and draws conclusions about the use of ultrasonography for the study of median nerve dynamics within the carpal tunnel.

6.1 Imaging technologies and the median nerve

For the study of median nerve dynamics, the principle imaging tool had to be capable of revealing the anatomical activity of the median nerve and other soft tissue structures at the wrist during physical movement of the hand. Imaging of anatomical structures within the body can be achieved using computed tomography (CT), magnetic resonance imaging (MRI) and high resolution ultrasonography. For this research the strengths and weaknesses of each of these imaging technologies had to be considered and are explained and compared in *Chapter 2* sections 2.3 and 2.4.

While CT uses ionising radiation (Chemali, 2005) and has a limited value in the evaluation of soft tissue structures (Scheri, Templeton, 2003), both MRI and ultrasonography are non-invasive can obtain high contrast resolution images of the different soft tissues of the body and the pathological changes resulting from disorders (Haacke, *et al* 1999). However, MRI is an expensive procedure, with high associated costs involved in the purchase, installation, maintenance and operation of the technology which has prevented its extensive use in the assessment of the median nerve at the wrist (Freedman, Hart, 2003). In addition, physical movement of the body during scanning can distort the image produced from MRI and it is therefore not suitable for studies into median nerve dynamics during physical movement.

Although the contrast resolution in MRI is superior to other imaging technologies good quality images of soft tissues structures can still be obtained using ultrasonography. It is relatively quick, less expensive and more widely available than MRI and it allows the examiner to interact with the participant during the scanning process, to adjust the position of the body or the area being scanned (Freedman, Hart, 2003).

The main strength of ultrasonography over other imaging technologies is its ability to achieve real-time dynamic imaging of soft tissue structures during physical movement (Chemali, 2005). This allows for the investigation of the anatomical activity of the median nerve during physical movement of the hand in virtually any plane or with the patient in any position. In addition the high frequency transducer probe increases the resolution of the image which makes the technology particularly suitable for the study of the small superficial structures within the body (Walker, *et al* 2004) including the median nerve within the carpal tunnel.

There have been many studies (detailed in *Chapter 2* section 2.4) that have validated the use of ultrasound as a useful tool for imaging the peripheral nerves in the body (Fornage, 1988; Nakamichi, Tachibana, 1998; Heinemeyer, Reimers, 1999; Grechenig, *et al* 2000; Bodner, *et al* 2001; Ellis, *et al* 2002; Yoon, *et al* 2004; Schwemmer, *et al* 2005; Thoirs, *et al* 2007) along with a number of studies (detailed in *Chapter 2* section 2.5) that have validated the use of ultrasonography for acquiring reliable measurements of the median nerve for the diagnosis of CTS (Buchberger, *et al* 1991;1992; Nakamichi, Tachibana, 2002; Leonard, *et al* 2003; Altinok, *et al* 2004; Kotevoglu, *et al* 2004; Yesildag, *et al* 2004).

The previous studies investigated the median nerve from static scans and did not involve physical movement or dynamic imaging. However, a small number of studies have validated the dynamic imaging capabilities of ultrasound as a reliable tool by investigating transverse movement of the median during simple non-functional wrist and hand movement and established values for the location of the median nerve within the carpal tunnel (Greening, *et al* 2001; Erel, *et al* 2003). Both studies found less radial movement of the nerve in the patient group when compared to the control group.

The main disadvantage of ultrasonography is the considerable experience necessary to operate the equipment, acquire good-quality images and analyze results (Walker, *et al* 2004). Poor results generally indicate poor technique, rather than an invalid test, and it is the unavailability of good training that limits the use of ultrasound (Hoochman, Zilberfarb, 2004).

This disadvantage was overcome by gaining practical experience in the use and maintenance of the ultrasonographic equipment (detailed in *Chapter 4* section 4.2) which started with lab-based training sessions performed by experienced users in musculoskeletal ultrasound. The training sessions were followed by a large number of practice sessions which refined the knowledge already acquired, provided experience in obtaining measurements and allowed for the familiarization of the sonographic appearance of the anatomy and physiology within the carpal tunnel during dynamic imaging. Additional information was also gained on the workings of ultrasound technology from the handbook provided by the manufacturers and specialised books on ultrasonographic technology.

A great amount of time was invested in the practice sessions and it was a steep and prolonged learning curve, but it was no more intense and time consuming than that required for efficient scanning procedures using CT or MRI (Hoochman, Zilberfarb, 2004).

For the study of median nerve dynamics at the wrist, the ultrasound equipment needed to be able to obtain dynamic high resolution images that can reveal the detail of soft tissue anatomy. The equipment also needed to be compatible with the 8-16MHz high frequency transducer to allow for the maximal contrast resolution (640 X 480 Pixels) of small, superficial structures within the wrist.

For this research the DIASUS (Dynamic Imaging Application Specific Ultrasound) ultrasound equipment was used as the principle tool (described in *Chapter 4* section 4.1. DIASUS is one of the most commercially available and widely used ultrasonographic systems. Its purpose and function is to applications requiring the highest resolution imaging of the anatomy of the musculoskeletal system and it can reveal the detail of soft tissue anatomy including the muscles, ligaments, tendons and nerves within the carpal tunnel. The ultrasonographic equipment continuously records the previous five-seconds of ultrasound frames to produce a time-motion cine-loop recording of the dynamic anatomical activity which can be exported as Bitmaps to other computer devices and analytical software programs.

6.2 Recommended Procedures

Although ultrasonographic imaging has been employed since the 1980's to image the peripheral nervous system (Fornage, 1988) dynamic ultrasonographic evaluation of

peripheral nerves during physical movement is still a relatively new procedure and to date, there has been no research that has investigated the dynamic imaging of the median nerve during functional hand movements during work-related activities. Therefore this section details the recommended procedures used in this research for the acquisition of dynamic ultrasound scans and the quantification of the median nerve during physical movement of the hand.

6.2.1 Recommended scanning technique and quantification method

The main scanning procedure were acquired during the pilot experiment (detailed in *Chapter 4* section 4.4 and 4.6) and based on the procedures proposed by Buchberger *et al* (1992) described in *Chapter 2* section 2.5. During the pilot experiment the median nerve was measured at three levels on the wrist (proximal, middle and distal to the carpal tunnel) and it was found that acquiring scans from the distal wrist crease in the middle of the carpal tunnel produced clear dynamic images including well defined outer boundaries of the median nerve. This allows for better identification of the nerve and more accurate measurements to be taken within its boundaries.

Therefore, to produce good clear transverse images of the median nerve at the wrist, the recommended procedure for this research starts by applying a liberal amount of transmission gel to the head of the transducer and placing it on the participant's distal wrist crease, perpendicular to the median nerve, avoiding any compression that could cause deformation to the structures within the carpal tunnel. It has been recommended in previous studies that five trials for each movement be performed and averaged to

establish accurate measurements (Nakamichi, Tachibana, 2002) which was adhered to for this research.

6.2.2 Recommended measurements

The ultrasound equipment records a time-motion cine-loop that images the dynamic anatomical activity of the structures of the carpal tunnel. These images can be analyzed on-line using the DIASUS software or be exported as Bitmaps and analyzed off-line using software programs such as Scion Image Processing Package software. The pilot experiment (described in *Chapter 4* section 4.4 and 4.6) involved assessing the on-line and off-line software for reliability and convenience. The study found that although both techniques produced reliable data, the use of on-line measurements resulted in a long experimental procedure involving scanning and obtaining measurements while the participant remained in the static experimental position. Analyzing the data off-line using Scion so that the measurements were obtained once the scanning procedure has finished, considerably reduced the time of the experiment and therefore the time the participants remained in the static experimental position.

Measurements were taken using Scion by using a direct trace around the perimeter of the median nerve. From this trace, the Scion software automatically calculated the cross-sectional area, major and minor axis and the X and Y co-ordinates of the nerve. The measurements taken for cross-sectional area gives a value for the size of the nerve, while the measurements taken for the major and minor axis were used to calculate the flattening ratio (by dividing the major axis by the minor axis) and gave an indication of the shape of the nerve. The values obtained for the X and Y co-ordinates gave the location of the median nerve within the wrist (the position of the centre of the nerve along a mediolateral and anteroposterior plane, respectively).

Previous studies have validated cross-sectional area and flattening ratio as being reliable parameters for measurement when studying the median nerve using ultrasonography (Buchberger *et al* 1991;1992; Nakamichi, Tachibana, 2002; Leonard *et al* 2003; Altinok *et al* 2004; Kotevoglou *et al* 2004; Yesildag *et al* 2004). There has also been a small number of studies that have introduced location of the nerve within the wrist as a valid parameter (Greening *et al* 2001; Erel *et al* 2003) although this study proposes a novel method for the calculation of the location and movement of the median nerve within the wrist that is different from that proposed in earlier studies.

The quantification method involved processing the obtained data, to give a value that shows the change in the size, shape and location of the median nerve for each movement. This was achieved by subtracting the value taken at one interval during the movement by the values taken in the previous interval and showed the change in the parameters represented by a positive value, a negative value or a value of zero. A positive value for cross-sectional area shows an increase in the size of the nerve, whereas a negative value represents a decrease. Positive value for flattening ratio show an increase in the ratio and indicates the shape of the nerve is flatter, with a negative value indicating the shape has become rounder. Positive values for the X co-ordinate shows that the location of the nerve is towards the radial (towards the thumb) side of the wrist while a negative value shows that the location has moved in a more ulnar (towards the small finger) direction, while a positive value for the Y co-ordinate shows the nerve moving towards the anterior (surface) of the wrist and a negative value indicating movement towards the posterior (back) of the wrist. A value of zero indicates that there is no change in the parameter being analyzed.

6.2.3 The participants and selection process

In this research, the participants were selected for their experimental groups by a upper limb assessment performed by a physiotherapist (see *Chapter 5* section 5.2) which divided them into three groups; non-symptomatic, moderate-symptomatic and fully-symptomatic groups.

The non-symptomatic group produced negative results during the assessment, verifying normal neural function while the participants from the fully-symptomatic group produced positive results indicating median nerve dysfunction and a limited ROM. The participants selected for the moderate-symptomatic group either showed no abnormal signs in median nerve function but declared themselves as in pain, or stated themselves as pain free but showed signs of dysfunction and a limited ROM. This group consisted of participants that may have early onset of a median nerve disorder at the wrist or may have a disorder of the nerve in other parts of the upper limb that could detect at the wrist by the physiotherapist.

6.2.4 Recommended position and movement

For the ultrasonographic study of the median nerve within the wrist, initial considerations include the positioning of the participant and the hand movements to be employed. The posture of the participant during a study needs to be easy to reproduce and allow for the experimenter to obtain easy access to the wrist being scanned. Replicating the posture precisely is necessary to reduce the variability of measurements caused by different positions that affect the behaviour of the median

nerve within the carpal tunnel and allow for comparisons to be made between individual participants.

For this research the scanning process was conducted with the participant in a supported sitting position, the back straight, the shoulder's relaxed on both sides and the upper arms placed at the side of the body, flexed by 90° at the elbow, with the palm facing upwards, the wrist in a neutral position (no deviation in a radial or ulnar direction) and the digits in extension. This was an easy posture to attain and hold throughout the experiment and eased the discomfort of a long experimental procedure and therefore reducing variability between the measurements.

A seated position was chosen for this research because it was a novel posture to use in ultrasonographic assessment of the median nerve, with most of the previous studies in this area choosing to scan the participants while they were lying in a supine position (Buchberger *et al* 1991;1992; Nakamichi, Tachibana, 2002; Leonard *et al* 2003; Altinok *et al* 2004; Kotevoglu *et al* 2004; Yesildag *et al* 2004). Although the supine position was adequate for these studies, the seated posture was chosen for this research because it was a more representative of a work-related position with a number of jobs cited as being high risk of musculoskeletal injury employing a seated posture at work (Pheasant, Haslegrave, 2006). In addition, it was an easy and comfortable position for the participants to hold throughout the length of the scanning process and allowed the upper body posture to remain static.

The hand movements also need to be easy to perform and replicate between a number of individuals and allow access of the transducer head to the wrist while the

movement is being performed. For the precise replication of hand movements the participant needs to practice each movement before the data collection starts so that it can be co-ordinated accurately. Careful practice reduces the variation between movements, permits comparisons between individuals and defines discrete points throughout the movement that are to be used in analysis. Instructions for the performance of the movement need to be precise and specific including the whole of the movement itself (e.g. power grip, pinch grip etc), maintaining the posture of the wrist, establishing the starting point and the discrete target positions that needed to be reached at specific time intervals. This ensures precise co-ordination of hand movements during dynamic scanning procedures. This calibration of movement needs to be constantly checked throughout the study to verify that the posture of the participant and the timing of the movement remain precise.

For the studies the finger grip, the power grip, the pinch grip and thumb opposition hand movements were selected on the basis that they represented a good range of real common hand tasks and were easy to perform and replicate, so that comparisons in the data could be made. The position of the hand, with the palm facing upwards and the wrist in a neutral position, also allowed access of the transducer to the carpal tunnel, while the movement was being performed. Details of the posture of the participant and the movements involved in the studies are given in *Chapter 5* section 5.1.

6.3 Summary of Experimental Studies

The overall aim of the experimental studies was to investigate whether the novel quantification method and ultrasonography techniques could be used to measure the change in size, shape and location of the median nerve during functional hand movement and could distinguish between normal nerve behaviour and that seen in participants who are symptomatic of a median nerve disorder. Analysis of the data was undertaken through a series of statistical tests that investigated the differences between the hand movements, the differences between the start and end positions of each movement and the differences between the groups.

Table 6.1 gives an overview of the key findings of this analysis.

Table 6.1: Overview of experimental studies

Experimental study	Aim	Measures	Main results
Study 1; Exploring the Normal Activity of the Median Nerve (detailed in <i>Chapter 5</i> section 5.3)	Investigate whether the quantification method and ultrasonographic technique could measure the change in size, shape and location in normal median nerve behaviour during physical hand movement	Measure the cross-sectional area, flattening ratio and X and Y co-ordinates of the median nerve at the start and end positions of each movement to establish differences i) between each of the four movements and ii) between the start and end positions of each movement	The results showed that the methodology could identify differences in hand movements and quantify the changing parameters of the median nerve. The study obtained base-line data to be used for comparative purposes in successive studies
Study 2; Median Nerve Activity in Participants Symptomatic of an Median Nerve Disorder (detailed in <i>Chapter 5</i> section 5.4)	Investigate whether the quantification method and ultrasonographic technique could measure the change in size, shape and location of the moderate-symptomatic or fully-symptomatic median nerve during physical hand movement	Measure the cross-sectional area, flattening ratio and X and Y co-ordinates of the symptomatic nerve at the start and end positions of each movement to establish differences i) between each of the four movements and ii) between the start and end positions of each movement and to compare this data with that obtained from participants with normal nerve function.	The results showed fewer differences in hand movements could be identified but analysis of the changing parameters of the median nerve could distinguish between the start and end position. In addition the results showed that the methodology could distinguish between the normal median nerve behaviour and that of the symptomatic nerve in a number of parameters and hand movements
Study 3; The Changing Parameters of the Median Nerve throughout Hand Activity (detailed in <i>Chapter 5</i> section 5.5)	Investigate whether the quantification method and ultrasonographic technique could measure the change in size, shape and location of the median nerve at five intervals during physical hand movement using high resolution ultrasonography	Measure the cross-sectional area, flattening ratio and X and Y co-ordinates of the median nerve at 1-second intervals during each movement to establish the progress of the median nerve throughout movement and differences in behaviour between normal nerve function and that seen in the symptomatic nerve	This results found that the parameters of the median nerve could be quantified throughout movement and identified a number of statistically significant differences in nerve behaviour between the groups for most of the hand movements

6.4 Key findings

This section identifies the key findings obtained from the experimental studies and proposes evaluations and explanations of these findings.

6.4.1 Influence of hand movements on median nerve behaviour

When investigating the differences in hand movements, in *Study 1* and *2*, no significant differences were found in the values giving the change in median nerve behaviour between the finger grip, power grip and pinch grip movements, in all of the groups. However, the thumb opposition was found to produce significantly different median nerve behaviour when compared to the other movements, in a number of parameters.

The thumb opposition movement showed very little change in non-symptomatic median nerve behaviour, with only a small increase in area, a slight change in shape and a limited amount of movement in the radial direction when compared to the other movements. In the fully-symptomatic nerve the thumb opposition movement also produced very little change in nerve behaviour and was significantly different to the power grip movement which produced a significant decrease in area.

When bringing the thumb across the palm during the thumb opposition movement, lower arm rotation occurs and the radius bone rolls around the ulna bone, altering the position of the wrist (deviating away from neutral). This could account for the thumb opposition producing significantly different values in median nerve behaviour when compared to the other movements.

6.4.2 Influence of the change in movement on median nerve behaviour

When investigating if there were any significant differences between the start and end positions of each movement in *Study 1* and 2, differences were found in both the non-symptomatic and fully-symptomatic groups during the finger grip, the power grip and the pinch grip, for the cross-sectional area, flattening ratio and the X co-ordinate parameters. The results show that as the digits move from extension to flexion during the finger grip, power grip and pinch grip movements, the non-symptomatic nerve moved to a more radial position within the wrist, increased in cross sectional area and assumed a rounder shape. Fully-symptomatic nerve behaviour between the start and end positions showed a significantly limited movement in the radial direction, a decrease in cross-sectional area and assumed a flatter shape during the finger, power and pinch grip the movements.

However during the thumb opposition movement, there was very little change in the nerve parameters with significant differences only found in the non-symptomatic group for flattening ratio values between the start and end positions. It is anatomically plausible that when lower arm rotation occurs in the thumb opposition movement, wrist size is reduced and so too is the space within the carpal tunnel. This could explain why the nerve became flatter in shape and showed an insignificant amount of change in its size and location.

6.4.3 Influence of a disorder on median nerve behaviour

When comparing the differences between the groups in *Study 1* and 2, statistically significant differences were seen in the finger grip and power grip movements between the start and the end positions. The moderate and fully-symptomatic nerve

decreased in area, became flatter and showed only slight movement in the radial direction when compared to the non-symptomatic group whose area increased, became rounder and showed a significant amount of movement in the radial direction. Significant differences were also seen during the pinch grip, with the fully-symptomatic nerve showing a decrease in cross-sectional area and less movement in the radial direction when compared to the non-symptomatic group. Differences in the thumb opposition movement were only seen in the flattening ratio measurements with the fully-symptomatic nerve becoming flatter when compared to the non-symptomatic nerve.

Statistical analysis of the data from *Study 3* showing the change in the median nerve at the 5 intervals throughout each movement found that most of the significant differences between the non-symptomatic group and the other groups appeared in the 1st and 2nd interval. The data showed that significant radial nerve movement corresponded to an increase in cross-sectional area and a more circular in shape, while limited radial movement corresponded to a decrease in area and a more flattened shape. However when significant differences between the groups were seen the moderate and fully-symptomatic nerve appeared to show less movement in the radial direction, a decrease in area and a flatter shape, when compared to the non-symptomatic nerve.

The information on median nerve activity during physical movement obtained between the start and end position were consistent with the information gained from the values obtained at the 5 intervals.

Therefore, for studies that aim to distinguish between the normal functioning median nerve and the symptomatic nerve obtaining and analyzing data at two points is sufficient and reduces the time of the experimental procedure and data collection, considerably. For studies that aim to classify or investigate anatomical activity during specific movement (for example, work-related movements or sports-related movements) or the relationship between cause and symptoms of a disorder and functional movement of the hand that could contribute to the disorder, a more in-depth examination of the progression of anatomical activity of the median nerve at discrete points is possibly more appropriate.

Table 6.2 shown below gives a brief overview of the key findings.

Table 6.2: Overview of the key findings

<p>Influence of the hand movements on median nerve behaviour</p>	<p>Analysis was performed to establish if there were any differences between the physical hand movements in each of the groups. No significant differences were seen between the finger grip, power grip and pinch grip movements. However the thumb opposition was found to be significantly different in a number of parameters when compared to the other movements.</p>
<p>Influence of the change in the movement of the hand on median nerve behaviour</p>	<p>Analysis was performed to establish if there were any differences in the values obtained at the start and the end positions of each movement in each of the groups. Significant differences between the start and end positions in the finger grip, power grip and pinch grip movements were found in a number of parameters. For the thumb opposition, significant differences between the start and end positions were only found for fattening ratio in the non-symptomatic group.</p>
<p>Influence of a disorder on median nerve behaviour</p>	<p>Analysis was performed to establish if there were any differences between the non-symptomatic group and the moderate and fully-symptomatic groups in the changing parameters of the median nerve during each of the hand movements. The median nerve in the non-symptomatic group showed an increase in area, a rounder shape and movement to a radial location during hand movement which was significantly different to the fully-symptomatic group which showed a decrease in area, a more flatter shape and a limited amount of movement in the radial direction.</p>
<p>Influence of the position of the hand on median nerve behaviour.</p>	<p>Analysis was performed to establish if there were any differences in the changing parameters of the median nerve obtained at discrete 1-second intervals between the groups and found that most of the significant activity happened in the first few intervals with the significant radial movement corresponding to an increase in area and a rounder shape and limited radial movement corresponding to a decrease in area and a more flattened nerve.</p>

6.4.4 Proposed mechanism of median nerve behaviour

It appears from observations of the sonograms obtained from non-symptomatic participants, that as the tendon bulk moves towards the surface of the wrist, the median nerve moves to a more radial position, increases in area and becomes rounder in shape. It is conceivable that the radial movement is to a less compressed position within the wrist which allows for the increase in area and a less flattened shape. This mechanism could also explain why the behaviour of the fully-symptomatic nerve, which showed limited movement in the radial direction, produced a decrease in area and a more flattened shape and explain why the thumb opposition movement, which also showed a limited amount of radial movement, became significantly flatter in shape.

Presuming this explanation to be true, the mediolateral movement of the nerve becomes increasingly important in the investigation of both the normal and symptomatic nerve dynamics. However there appears to be very little research that has looked at this movement with researchers preferring to concentrate on measurements taken from static scans for cross-sectional area and flattening ratio.

The small amount of research that has looked at mediolateral nerve location within the carpal tunnel during physical movement of the hand and wrist movement, are detailed in *Chapter 2* in sub-section 2.5 (Greening *et al* 2001; Erel *et al* 2003). Greening *et al* (2001) found that the median nerve was in a significantly less radial location in the symptomatic group when compared to the control group, during movement of the fingers. Erel *et al* (2003) also found a decrease in radial nerve movement in CTS patients, when compared to a control group along with an increase in flattening ratio

(the nerve became flatter). The authors suggest that the flatter shape was due to the nerve failing to move away from the flexor tendons and remaining under pressure.

The findings from this study presented in this thesis are consistent with the previous studies performed by Greening *et al* (2001) and Erel *et al* (2003) and show that the mediolateral movement of the median nerve within the carpal tunnel has the potential of becoming an important parameter in the study of median nerve dynamics and its associated pathologies.

6.5 Limitations of Research

One of the main limitations of this research was the small number of participants, which diminished further as the study progressed due to some participants leaving the project. The sample size was established after discussions with two subject matter experts and revolved around previous studies on ultrasonographic imaging of the median nerve that had used small sample sizes (ranging between 14 and 40 participants) but produced valid results (Buchberger *et al* 1991; 1992; Leonard *et al* 2003; Altinok *et al* 2004; Kotevoglou *et al* 2004).

A *post hoc* power analysis using the Wilcoxon-Mann Whitney test predicted a minimum sample size of 21 participants (using 0.08 as a standard of accuracy). Even though the power of this research was low and could raise questions about the validity of the data, significant differences were seen within the results and are consistent with other studies that have produced valid results when measuring dynamic activity of the median nerve (Greening, *et al* 2001; Erel, *et al* 2003).

Another major limitation to this study was the sampling criteria. An opportunity sample (Cochran, 1977) was used based on availability, convenience, time and practicality drawn from the staff and students of the University of Nottingham. However, it could be argued that this method of sampling is not representative of the population but it was an extremely quick and economical form of sampling for an initial exploratory study into a novel method and technique.

An attempt was made to recruit a similar amount of males and females, along with a broad range of ages. Nevertheless, the fully symptomatic group contained more females than males and an older age range, suggesting that it is not representative of a general population of people. However, current literature on this subject suggests that disorders are more common in females than males and are more likely to affect people in an older age range than the young (Hagberg, Wegman, 1987; Buckle, 1997; Gusbers Van Wijk, Kolk, 1997; Buckle, Devereux, 2002; HSE 2004; Punnet, Wegman, 2004; Treastera, Burra, 2004).

Other limitations included controlling the posture and the hand movements, precisely. Although there was a considerable practice session in performing the movement, before the scanning process started, reproducing the exact posture and movement of the hand in all the participants that took part in the study, would have been impossible. However, variation caused by different postures and movements was reduced by careful monitoring of the participant by the examiner and also by obtaining measurements from five trials and averaging the values.

6.6 Recommendations for Future Research

Future research in this area needs to consider using a larger participant sample size. Using a larger sample size would have the potential of validating the findings of this research further, and might identify a greater number of statistical significance differences within the parameters of the non-symptomatic and fully-symptomatic median nerve. A retrospective power analysis of the data presented in this thesis indicated a minimum sample size of 21 participants. However, care must be taken when working with 'minimum' numbers, as a proportion of participants could leave the study before all of the data has been collected.

Limitations of the opportunity sampling could be rectified by using a stratified sampling criterion. This would divide the target population into groups, one of which could specifically target a population that has been clinically diagnosed with a median nerve disorder and match-pairing this sample to a healthy control group. However, choosing this type of sampling criteria is far more time consuming and expensive.

Future studies could also investigate the hand movements with the wrist in different positions (e.g. comparing the movement with the wrist in a neutral position and with the wrist in radial and/or ulnar deviation). In addition, due to the ability of the ultrasonographic equipment to obtain scans in any plane, the hand movements could be studied while the participant undertook a different body posture (such as standing or reaching) to investigate what effect different postures have on the median nerve.

Measuring other structure in the wrist was considered for this investigation but due to the inability in gaining clear images of the boundaries of these structures, they were

discarded for this study. Measuring the tendon bulk would either validate or terminate the suggestion that the tendons influence the movement of the median nerve in the mediaolateral plane (as described in earlier in this section) and obtaining measurements of the size of the carpal tunnel would confirm or deny the suggestion that compression of the symptomatic nerve is possibly due to limited space within the tunnel (as described earlier in this section).

Further advances in high resolution ultrasonographic technology including enhanced imaging transducers and improved image reconstruction will advance the capability of ultrasonography to detect the boundaries of these structures and will inevitably allow for the quantification of all the structures within the wrist to be obtained more easily.

Ultimately, this research has shown that further study of dynamic anatomical activity during physical movement can be achieved and can contribute to existing knowledge in ergonomic and biomechanical median nerve studies and to clinical studies into symptomatic nerve disorders.

7. Conclusions

This research has shown that the dynamic ultrasonographic technique and the novel quantification method can measure that changing parameters of the median nerve during physical hand movement and can be used to distinguish between participants with normal median nerve function and those who are symptomatic of a median nerve disorder.

Although ultrasonography has been employed for many years to study the median nerve, most of the literature in this area has taken measurements from static scans for the purpose of diagnosing disorders and the studies did not involve physical movement of the arm or anatomical activity within the carpal tunnel (Buchberger *et al* 1991; Buchberger *et al* 1992; Nakamichi, Tachibana, 2002; Leonard *et al* 2003; Altinok *et al* 2004; Wong *et al* 2004; Yesildag *et al* 2004). These studies relied on absolute data with fundamental units of length and mass for the parameters of the median nerve. These absolute values could possibly be influenced by individual variables such as age, sex, physical size etc. By establishing an analytical method that produced arbitrary data (not representing any specific value) showing the change in the parameters of the nerve (rather than their absolute value at a static position), the influence of individual variations on the data could be reduced.

To the knowledge of the author this is the first study that uses ultrasonography to quantify the dynamic change in the size, shape and location of the median nerve during functional hand activity. The simple and novel way of measuring dynamic activity of the median nerve at the carpal tunnel presented in this thesis, has the potential to provide a better understanding of the mechanisms involved in median nerve function and also could be used as an alternative means of measuring the

differences between participants with normal nerve function and that seen in participants symptomatic of a median nerve disorder.

Appendices

Appendix A: Anatomy of the Upper Limb

Appendix A includes sections that describe the basic anatomy of the wrist and hand and details the form and function of the bones and joints, the median nerve and the muscles, ligaments and tendons

A.1 The Bones and Joints of the Hand and Wrist

The complete framework of bones, joints and cartilage represents the skeletal system. The skeletal system performs several basic functions such as, protection of the internal organs from injury, blood cell production and storage of triglycerides (fat) and several minerals and support for soft tissue. It also works with skeletal muscle by providing attachment points for the tendons, so that when the muscles contract they pull on the bones to generate movement (Tortora, Grabowski, 2003).

Each upper limb consists of 30 bones in three locations: the humerus in the arm, the ulna and radius of the forearm and the 27 bones in the wrist and hand as illustrated in Figure A1.1. The five digits in each hand include one thumb and four fingers and include the 5 metacarpal bones and the 14 phalange bones of which the thumb has two and each finger has three. The proximal (nearest to the trunk of the body) ends of the phalange bones articulate with the distal (furthest from the trunk of the body) ends of the metacarpal bones to form the knuckles and the proximal ends of the metacarpal bones are attached to the carpal bones of the wrist. The metacarpal bones represent the framework of the hand which forms a curve so that in a neutral position the palm of the hand is concave.

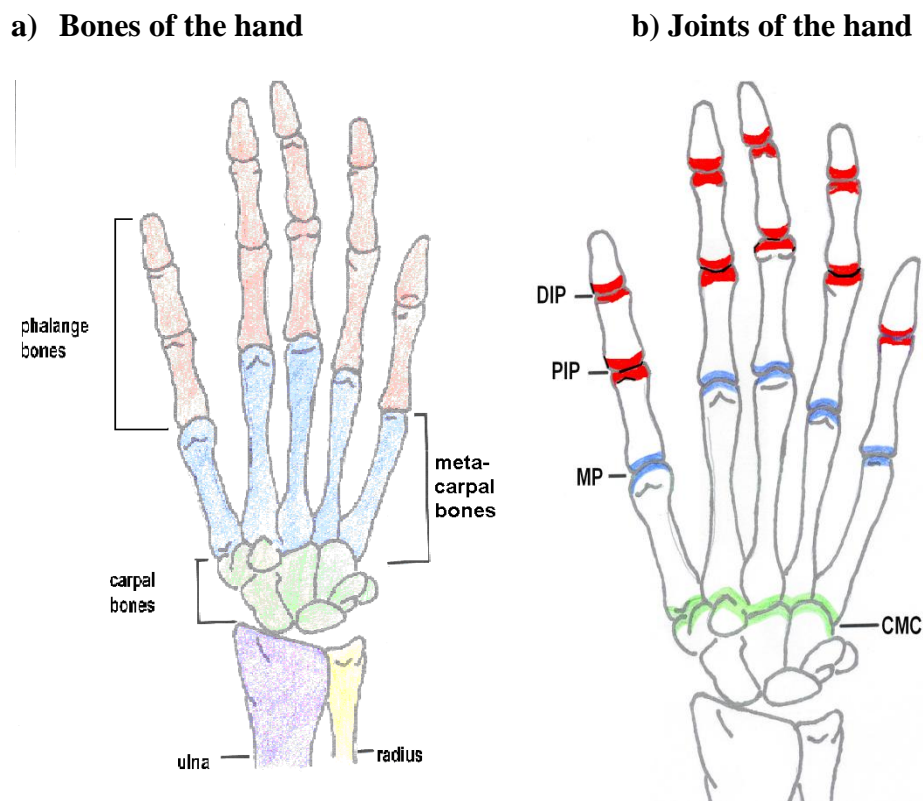


Figure A1.1: The bones and joints of the wrist and hand

(Adapted from Tortora, Grabowski, 2003).

Figure A1.1 also illustrates the distal (DIP) and proximal (PIP) interphalangeal joints of the digits and the metacarpophalangeal (MP) and the carpometacarpal (CMC) joints in the hand. The metacarpal bones articulate (Hamill, Knutzen, 1995) with a particular carpal bone at the carpometacarpal joint, with the metacarpophalangeal joint linking the metacarpal bones to the proximal phalanges. The joints between the phalanges in the fingers are the proximal and distal interphalangeal joints while the thumb has only one interphalangeal joint. The fingers are capable of flexion and extension movements (movements into the hand and away from the hand, respectively). The thumb has two degrees of freedom which allows for a large variety

of power and precision grips and enables opposition of the thumb to the base of all the fingers on the palmar side of the hand (Hamill, Knutzen, 1995).

Figure A1.2 details the bones and the joints within the wrist. It comprises 8 carpal bones and a joint complex consisting of the radiocarpal, midcarpal and intercarpal joints. The carpal bones are arranged in two rows at the terminus of the radius and ulna bones in the forearm (shown in Figure A1.1) and form a concave transverse arch that shapes the floors and walls of an anatomical structure called the carpal tunnel.

The row nearest the body contains three carpal bones participating in wrist-joint function; the scaphoid, lunate and triquetrum, and also the pisiform which sits on the ulnar side of the hand and functions as a site of muscular attachment (Hamill, Knutzen, 1995). The row furthest away from the body also consists of four carpal bones; the trapezium, trapezoid, capitate and hamate articulate with the metacarpal bones of the digits to form the carpometacarpal joints (Nordin, Frankel, 2001).

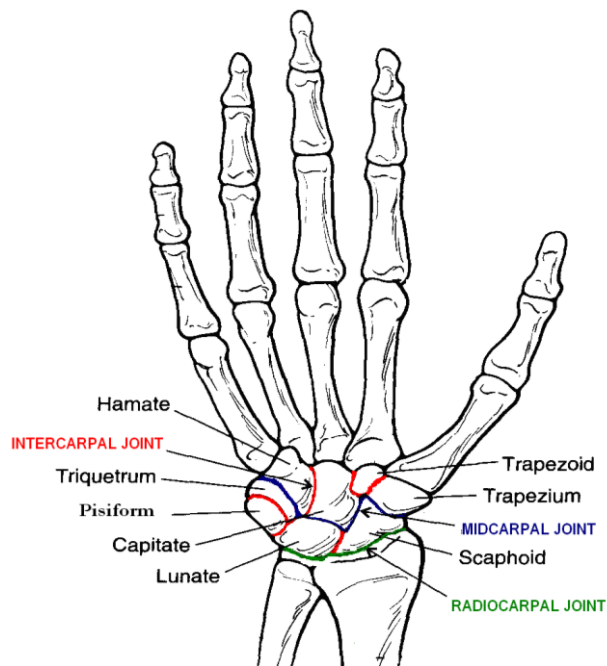


Figure A1.3: Detailed illustration of the joints and bones in the wrist

(Image of hand taken from Nordin, Frankel, 2001 with adaption to the text).

The surface anatomy of the wrist includes proximal and distal wrist creases of which the distal wrist crease is approximately at the same level as the radiocarpal joint. This joint involves the distal end of the radius in the forearm and the scaphoid and lunate bones, with slight contact with the triquetrum. The intercarpal joints are set between the carpal bones with the midcarpal bones separating the two rows.

Figure A1.3 shows the structures within and surrounding the carpal tunnel. Those within the carpal tunnel include the median nerve and nine extrinsic flexor tendons of the thumb and fingers. The carpal tunnel is an enclosed space through which soft tissue structures such as the tendons and the median nerve pass between the forearm and the hand. Its anterior border is formed by a ligament that stretches across the wrist from the trapezium to the hamate bones, called the flexor retinaculum also known as

transverse carpal ligament (Freivalds, 2004). This ligament is made up of fibrous tissue running transversely across the wrist.

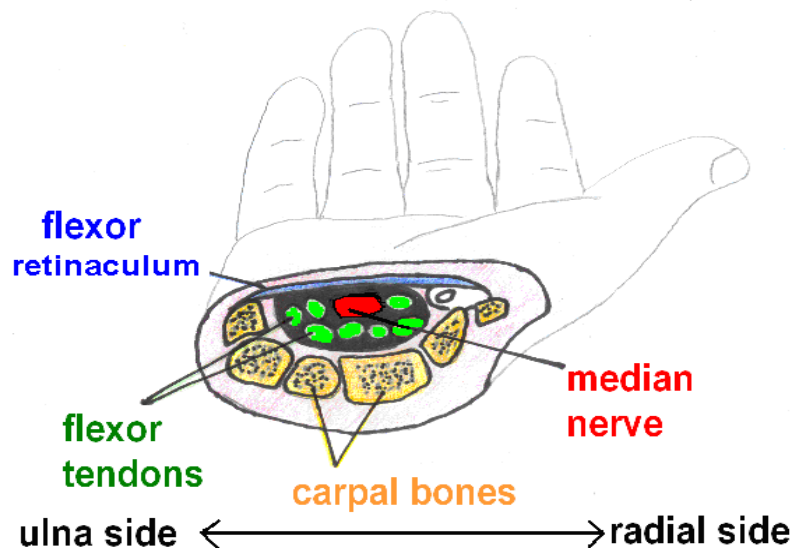


Figure A1.3: The carpal tunnel

(picture taken from Kroemer *et al*, 1997 with adaptation to the text)

A.2 Muscles, Tendons and Ligaments

The Muscles

There are about 400 muscles in the human body, each with a specific function. They work to stabilize the position of the body, regulate organ performance, generate heat, drive food and fluids through the body and to produce movement. Muscle can be classified into three types: smooth, cardiac and skeletal muscle. Cardiac muscle forms most of the wall of the heart, is involuntary in its contraction and therefore not consciously controlled. Smooth muscle tissue is located in the walls of hollow internal structures such as the airways to the lungs, blood vessels, stomach, intestines, gallbladder etc. and is usually under voluntary control. Skeletal muscle is usually attached to the bones of the skeleton and is voluntary because it can be consciously

made to contract and relax. Most skeletal muscles change chemical energy into mechanical energy to produce force and generate movement usually around a joint (Tortora, Grabowski, 2003).

Figure A2.1 illustrates a skeletal muscle which is made up of muscle fibers grouped together to form fascicles. Each fiber is a long, multinuclear cylindrical cell that contain basic sub-units called myofibrils. Myofibrils consist of two types of protein filaments that overlap each other; thick myofilaments that contain the protein myosin and thin myofilaments that contain the protein actin (Hagberg, *et al* 1995). Muscles have the capacity to contract when stimulated by an action potential, by the myosin and actin filaments sliding over each other. Muscle spindles run parallel with the muscle fiber and are used as a length monitoring system that supplies information about the location and velocity of a joint (Chaffin, *et al* 1999).

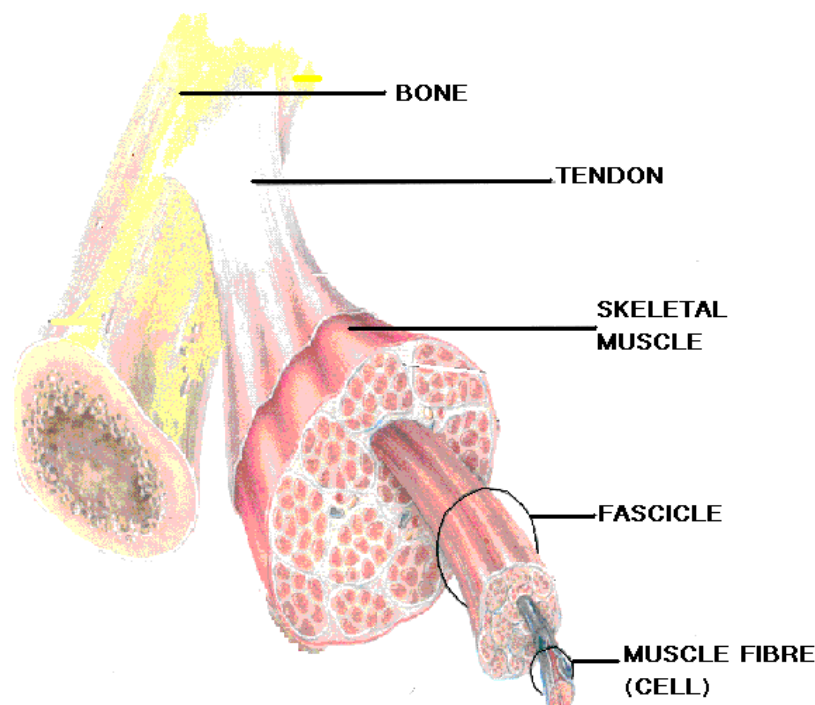


Figure A2.1: Skeletal muscle showing its attachment by the tendon to the bone

(taken from Tortora, Grabowski, 2003 with adaptation to the text)

Wrist extension and flexion forces are generated by muscles that originate in the region of the elbow joint and are known as extrinsic muscles. These muscles provide both fine adjustment, and a stable working platform for the hand and fingers (Hazelton, *et al* 1975). The majority of the forces exerted by the hand are derived from the extrinsic digital muscles originating in the forearm and crossing the wrist by way of sheathed tendons to power extension and the flexion movements of the fingers (Delleman, N.J. Haslegrave, C.M. Chaffin, D.B., 2004). In addition intrinsic muscles, which are muscles that originate within the hand, create movement at the MCP and IP joints. The thumb has eight muscles, four of which are intrinsic and form the fleshy region of the palm known as the thenar eminence, with a smaller hypo-thenar eminence formed by the three intrinsic muscles of the little finger on the ulnar side of the palm (Hamill, Knutzen, 1995).

Finger flexion is performed mainly by the flexor digitorum profundus (FDP) and the flexor digitorum superficialis (FDS) muscles. The FDS muscle is capable of flexing each digit independently however the FDP muscle cannot. Flexion of the middle, ring and little fingers by the FDP muscle occurs together because they all arise from a common tendon or muscle, but the index finger can be independently flexed due to the separation of the FDP muscle and tendon for this digit. Extension of the fingers is achieved mainly by the extensor digitorum muscle which enters the hand as four tendons that branch off at the metacarpophalangeal (MP) joint and run the total length of the fingers (Nordin, Frankel, 2001).

The muscles of the thumb control a large array of movements with the opposition movement being the most significant, allowing the hand to pinch, grasp or grip an object by bringing the thumb across to meet any of the fingers. Although all the thenar muscles contribute to the opposition movement the muscle mainly responsible for this movement is the opponens pollicis (Nordin, Frankel, 2001).

The tendons

Tendons are the connection between bone and muscle as seen in Figure A2.1.

Tendons are made up of dense connective tissues that form part of a muscle and consist of parallel collagen fibres often surrounded by a synovium, a lining that produces synovial fluid and assists in the gliding of the tendon, protecting it from mechanical friction when passing over bone (Hagberg, *et al* 1995). The tendons of the muscles in the arm either attach to the wrist bones or go into the hand, along with blood vessels and nerves and are held close to the bone by strong ligaments called fasciae.

The digital flexor tendons pass through the carpal tunnel below the flexor reticulum and each branch out towards its respective digit. The flexor superficialis tendon attaches into the middle phalange bone and the flexor profundus inserts into the distal phalange bone. These tendons initiate smooth and stable movement of the muscles, and contribute to the control and stability of the joints in the hand. They are surrounded by synovial sheaths and restrained to the skeletal bones at strategic positions by a fibrous sheath called the digital flexor tendon pulley system (Nordin, Frankel, 2001).

The well developed flexor tendon pulley system allows for a smooth curve so that no sharp or angular bends exist along the course of the tendon. It also enables the tendon to retain a relatively constant position within the hand rather than bowstringing across the joint, reducing local points of pressure and stress between the tendon and the sheath (Nordin, Frankel, 2001).

The Ligaments

Ligaments are made up of groups of strong fibrous tissue that connect bones and support muscles or organs. In the wrist they restrict joint motion and smooth joint surfaces while being capable of inducing bony displacements and transmitting loads between the arm and the hand, adding to the functional versatility of the hand (Nordin, Frankel, 2001).

The ligaments of the hand have an intricate system that encloses, compartmentalizes and restrains the joints, tendons, skin, nerves and blood vessels. The relatively numerous palmar ligaments are thick and strong compared to the dorsal ligaments found on the back of the hand, which are thinner and fewer in number. The ligamentous structural system of the fingers encircles each digit to balance the forces of opposing muscles and for the stability and control of the hand during activity (Nordin, Frankel, 2001). Figure A2.2 illustrates the proximal interphalangeal joint of the index finger and shows the ligamentous attachments to the bone.

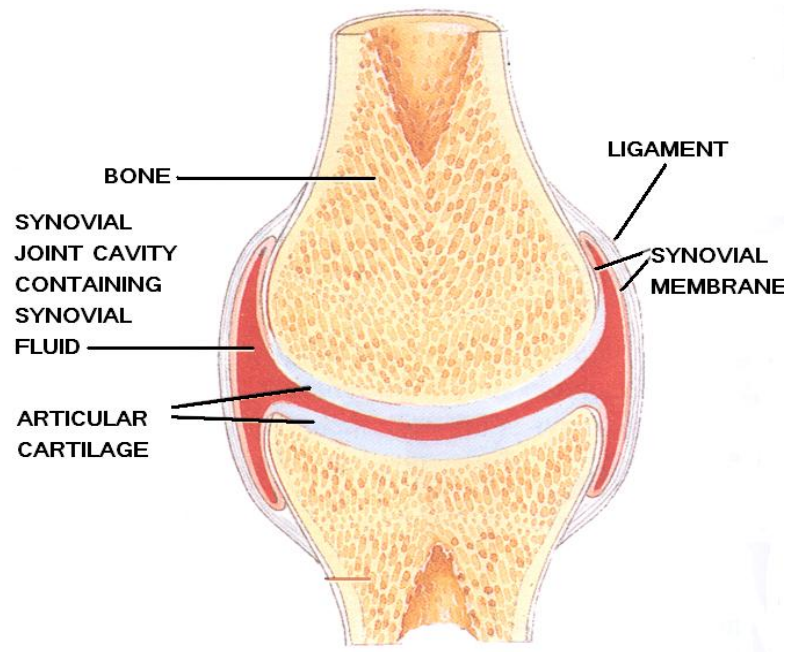


Figure 2.2: Finger joint showing the attachment of the ligaments to the bone

(Taken from Tortora, Grabowski, 2003 with adaptation to the text)

At the wrist, deep ligaments called fascia are thickened into fibrous bands called retinacula to form the flexor retinaculum which spans across the roof of the carpal tunnel. The long flexor tendons of the wrist and hands along with the median nerve, pass through the carpal tunnel and under the flexor retinaculum before entering the hand (Nordin, Frankel, 2001).

A3 Median Nerve

The nervous system is a complex and highly organized network of neurons that regulates body activities by responding rapidly using nerve impulses. It is responsible for our perceptions, behaviors, memories and is involved in somatic senses such as touch, pressure, temperature, and pain, and our sensory function such as internal stimuli that increases blood acidity and sensing external stimuli such as the presence

of raindrops on the arm. In addition, the nervous system initiates all voluntary movement.

It can be sub-divided into the central nervous system (CNS) consisting of the brain and spinal cord, and the peripheral nervous system (PNS) consisting of nerve fibers, connective tissue and blood vessels all surrounded by a myelin sheath (Nordin, *et al* 1999). The functional unit of the nerve fibers is called a neuron and is made up of a cell body called a soma and a number of extensions called axons and dendrites. The axons conduct nerve impulses called action potentials away from the cell body, and dendrites mediate impulses from other neurons.

Peripheral nerves contain both sensory nerve fibres that transfer action potentials from the sensory receptors at the periphery to the central nervous system, and motor nerve fibers that transfer action potentials from the central nervous system to the muscles (Chaffin, *et al* 1999). The nerve fibers are grouped together to form fascicles which are surrounded by connective tissue consisting of successive layers called the endoneurium, perineurium and epineurium (Tortora, Grabowski, 2003) and are shown in Figure A3.1.

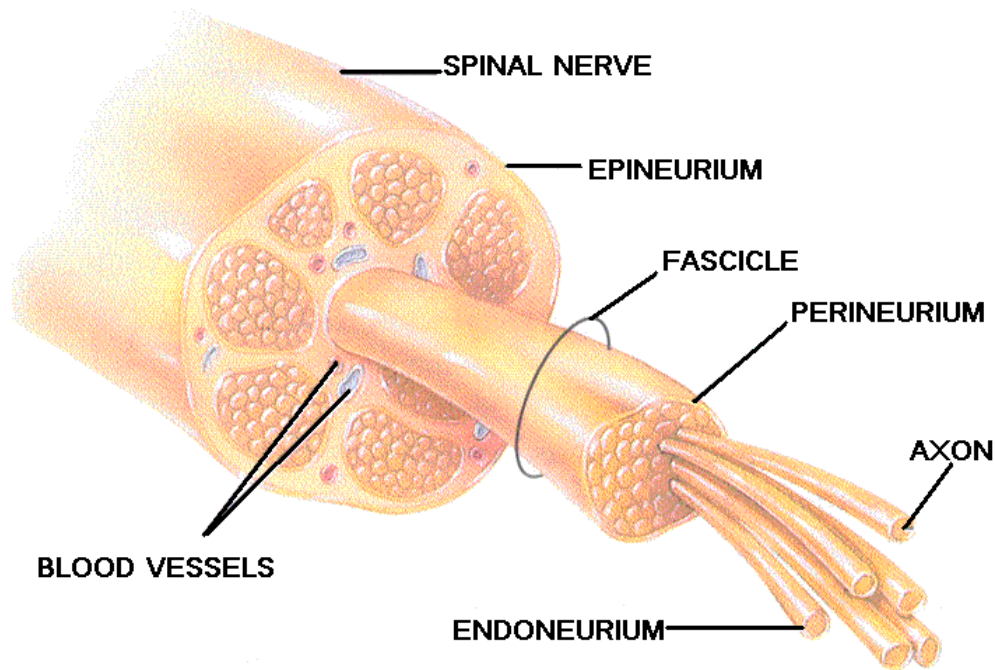


Figure A3.1: Cross section of the median nerve showing its elementary structures

(picture taken from Tortora, Grabowski, 2003 with adaption to the text)

The innermost layer is the endoneurium, a network of compact tissue that forms an elastic structure and maintains the space and fluid pressure around the axon enabling the fiber to remain constant throughout the course of the nerve. Around the fascicles are numerous sheathed layers known as perineurium that forms a rigid mechanical barrier and protect the fascicles from external forces and certain substances. The epineurium is the outer most layer and surrounds and protects the fascicles especially during limb movement when the nerve has to bend (Butler, 1991).

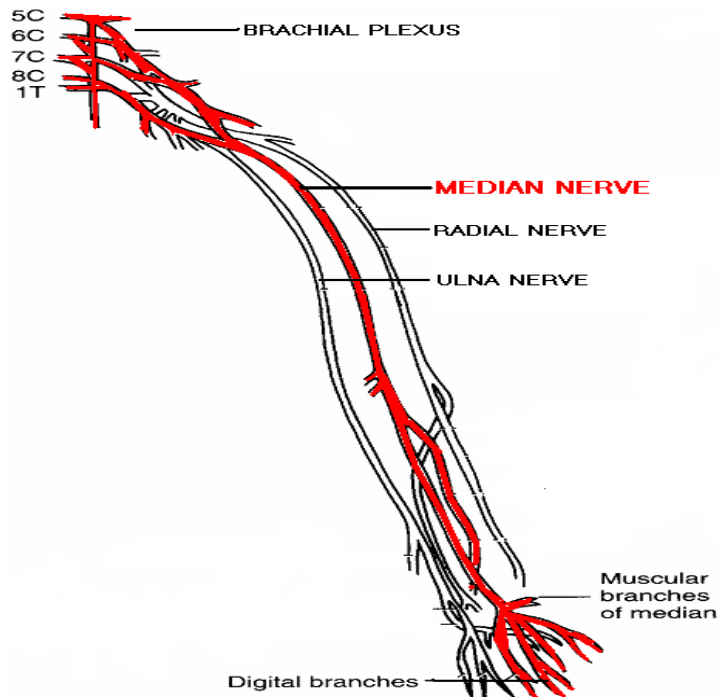


Figure A3.2: The peripheral nerves of the upper limb from the brachial plexus to the hand

(picture taken from Nordin, Frankel, 2001. with adaptation to the text)

The median nerve originates from the cervical roots C5-T1 of the medial and lateral cords in the brachial plexus from where it travels distally via the shoulder and down the arm. At the elbow the median nerve travels through the two heads of the muscle pronator teres and innervates all the flexor muscles in the forearm except flexor carpi ulnaris and the ulnar half of the flexor digitorum profundus muscles (Omer, *et al* 1998). The nerve then travels through the carpal tunnel beneath the flexor retinaculum where it lies immediately superficial to the flexor tendons of the fingers and the thumb (Omer, *et al* 1998). The median nerve carries both motor and sensory fibres. The motor fibres supply most the muscles on the front of the forearm except flexor carpi ulnaris and the ulnar half of flexor digitorum profundus along with four small muscles of the hand which include the lateral two lumbricals, the opponens pollicis,

the abductor pollicis brevis and the flexor pollicis brevis. The sensory function of the median nerve includes the palmar aspect of the thumb, the index and middle finger and one half of the ring finger (Omer, *et al* 1998).

The nerve normally divides into six branches at the distal end of the flexor retinaculum to supply sensation to the volar surface of the palm, the thumb, the index finger, the middle finger and half of the ring finger as illustrated in Figure A3.3. The recurrent branch of the median nerve innervates all the thenar muscles, with the exception of the adductor pollicis and the deep head of the flexor pollicis brevis. The digital cutaneous branches and the palmar digital branches innervate the index and middle finger lumbricals with the sensory branches innervating the thumb, index finger and the radial half of the middle finger (Hamill, Knutzen, 1995).

However, there are a number of classified and documented variations of median nerve anatomy relating to the branches of the median nerve (Hamill, Knutzen, 1995). These individual variations can be the result of DNA characteristics which determine the cellular composition (genotype) and the resulting characteristics (phenotype) or they could be due to environmental influences such as nutrition, temperature, altitude and sunlight (Kroemer, *et al* 1997).

Appendix B (i): Ethical Review Committee Form

The University of
Nottingham

ETHICAL REVIEW COMMITTEE
School of Mechanical, Materials & Manufacturing Engineering

Request for approval for an investigation involving human subjects

Full name ALYSON LANGLEYPosition Research Student Postgraduate Undergraduate Staff Other (specify below)Other (please specify) 2093248Student Identification Number 2093248

Course

Supervisor DR HASLEGRAVE / DR McNALLYTitle of investigation MEDIAN NERVE BIOMECHANICS AS A
CONSEQUENCE OF SIMPLE HAND MOVEMENTSStart Date JULY JUNE 2005 End Date AUGUST 2005 New Revision Renewal Continuation**Investigation Protocol**

Please attach a brief description of the method, equipment and procedures which will be used. State the number of subjects to be tested, the number of trials to be made by each subject, the duration of exposure to test conditions and any payment or inducement offered to the subjects. Attach a copy of any questionnaire and of the Informed Consent Form which will be used.

Please return the completed form and all accompanying documents to the **Student Office, Coates Building.**

Received
29 JUN 2005
Student Office

Checklist

The purpose of this Checklist is to facilitate the review process and to identify the ethical issues which will concern the Committee. It is meant to be an aid to both the researcher and the Committee. If you answer "YES" to any of the following questions, this will not necessarily lead to a refusal of approval, but these are areas which require some justification and attention on your part in specifying your protocol.

Title of investigation MEDIAN NERVE BIOMECHANICS AS A
CONSEQUENCE OF A SIMPLE HAND MOVEMENT

Please answer ALL of the following questions

- | | | YES | NO |
|----|--|-------------------------------------|-------------------------------------|
| 1 | Will the populations studied include any minors (under 18), pregnant women, people who are disabled or in poor health or non-English speakers? | <input type="checkbox"/> | <input checked="" type="checkbox"/> |
| 2 | Will it be possible to associate specific information in your records with specific participants on the basis of name, position or other identifying information contained in your records? | <input type="checkbox"/> | <input checked="" type="checkbox"/> |
| 3 | Will persons participating or queried in this investigation be subjected to <u>physical discomfort, pain</u> or aversive stimuli or the threat of any of these? (If YES underline all that apply) | <input checked="" type="checkbox"/> | <input type="checkbox"/> |
| 4 | Will participants engage in strenuous or unaccustomed physical activity? | <input type="checkbox"/> | <input checked="" type="checkbox"/> |
| 5 | Will participants be exposed to any physical or psychological risks not indicated above? (If YES explain) | <input checked="" type="checkbox"/> | <input type="checkbox"/> |
| 6 | Will the investigation use procedures designed to induce participants to act contrary to their wishes? | <input type="checkbox"/> | <input checked="" type="checkbox"/> |
| 7 | Will the investigation use procedures designed to induce embarrassment, humiliation, lowered self esteem, guilt, conflict, anger, discouragement or other emotional reactions? (If YES underline all that apply) | <input type="checkbox"/> | <input checked="" type="checkbox"/> |
| 8 | Will participants be induced to disclose information of an intimate or otherwise sensitive nature? | <input type="checkbox"/> | <input checked="" type="checkbox"/> |
| 9 | Will participants be deceived (actively misled) in any manner? | <input type="checkbox"/> | <input checked="" type="checkbox"/> |
| 10 | Will information be withheld from participants that they might reasonably expect to receive? | <input type="checkbox"/> | <input checked="" type="checkbox"/> |

Signature A Langley Date 28-06-05

Received

29 JUN 2005

Student

Decision on Approval

The Committee requests further information on the following before approval can be considered for this investigation:

.....

Date

Approval is given for the investigation following the objectives and procedures described in the attached protocol with the following restrictions:

As clarified by
~~the~~ attached ethics application

Any problems which arise during the course of the investigation must be reported to the Committee.

Signature	<i>Alan Stebbins</i>	Signature	<i>Sarah Sharples</i>
Name	<i>Alan Stebbins</i>	Name	<i>DR SARAH SHARPLES</i>
Date	<i>26/7/05</i>	Date	<i>26/7/05</i>

Please note:

1. The approval only covers the subjects and trials specified on the form and further approval must be requested for any repetition or extension to the investigation.
2. The approval covers the ethical requirements for the techniques and procedures described in the protocol but does not replace a safety assessment.
3. Approval is not intended to convey any judgement on the quality of the research, experimental design or techniques.

Received
 29 JUN 2005
 Student Office

Appendix B (ii): Investigation Protocol for the Ethical Review Committee.

Title; Median Nerve Biomechanics during Simple Hand Movement

The aim of this study is to use high resolution ultrasonography with 8-16MHz linear array transducer to explore the appearance of the median nerve in the area of the carpal tunnel. The purpose of this study is to try and establish a correlation between normal/abnormal function and biomechanical movement of the median nerve, on seventeen participants, whilst they perform a simple hand movement. However subjects that suffer from any of the afflictions stated on the consent form will be excluded from this study.

The study also involves upper limb function tests and a pain questionnaire to establish normal/abnormal function. A trained physiotherapist will test the subjects upper limb function by performing a number of simple objective measures tests including

- active and passive range of movements (ROM) for the neck, shoulder, elbow, wrist and fingers
- joint clearing in the neck, shoulder, elbow in the form of movements to the quadrants
- cervical spine myotomes and dermatomes
- a number of upper limb tension tests (ULTT).

These tests can occasionally affect persistent or previous conditions and cause a reoccurrence of pain and discomfort, however these can be minimized by performing the test slowly while constantly checking if the subject is comfortable or in pain, and questioning the participant to evaluate their SIN-factor rating (Severity, Irritability, Nature). It is very unlikely that these tests would cause new conditions.

If movements cause pain to the subject during the function test or the scanning process, the subject will be excluded from that specific set of results, but might still be included in the study using static ultrasound examination, provided they are not in pain or discomfort. If after the function test the subjects produce positive signs (pain, discomfort, a decreased ROM or cervical spine) then the test signs will be explained and a recommendation regarding seeking medical advice will be made accordingly.

The actual scanning will be conducted with the subject in a supported sitting position with the arm abducted at 90° at the elbow and the anterior surface of the wrist facing upwards. The wrist itself will be held in a neutral position with the fingers slightly extended. This position will be splinted to a specially designed arm rest with Velcro straps around the forearm and palm of the hand.

With the fingers slightly extended the subject will be asked to flex the fingers forward so that their tips touch the palm of their hand. This movement will be performed five times on each arm producing cross sectional scans of the palmer surface of the wrist and the median nerve will be measured at the starting and finishing positions using the ultra-sounds own software.

The processes of the function tests and the scanning should take no more than two hour, with the subjects being offered an inconvenience allowance payment of £8.00 per hour.

Appendix C: Participant Consent Form

Median Nerve Biomechanics during Simple Hand Movement

This study is being conducted as part of the initial stage of a PhD level qualification. All information collected will be anonymous and only used for the purpose of this experiment. Participation in this study is voluntary and can be withdrawn at any time

Aim. In the initial stage of the project you will be asked to fill in a questionnaire about previous and current upper limb function, and to take part in a upper limb function tests, performed by a trained physiotherapist. This involves a number of simple arm movements that specifically puts a slight tension on the median nerve and can occasionally affect persistent or previous conditions and cause a reoccurrence of pain and discomfort, however this can be minimized by performing the test slowly. If the movements cause severe pain during the function test or the scanning process, you will be excluded from that specific set of results, but might still be included in the study using static ultrasound examination. If after the function test, you produce a positive sign (pain, discomfort, a decreased ROM or cervical spine) then this will be explained along with a recommendation to seek medical advice, if this is necessary.

The main aim of the study involves exploring median nerve movement within the carpal tunnel using a DIASUS ultra sound scanner. You will be asked to undertake a simple dynamic movement using your fingers while sitting in a supported with the arm and wrist facing upwards and splinted to prevent significant movement. The scanning process will take place at the wrist in the area of the carpal tunnel and should take no longer than an hour. There are no recorded side effects from using ultra-

sound, and the equipment is deemed safe for diagnostic and exploratory use by the NHS. The processes of the function tests and the scanning should take no more than two hour, with the subjects being offered an inconvenience allowance payment of £8.00 per hour.

Please read the statement below and if in agreement sign and date.

I confirm that I have voluntary agreed to take part in the study. I have read and understand the above explanation and have been given the opportunity to ask questions about the study. I authorize the investigator to disclose the results of my participation while I remain anonymous. I understand that I can ask for further instructions or explanations and that I am free to withdraw from the study at any time.

I do not suffer from any of the following conditions;

- **Diabetes**
- **Heart disease**
- **Breathing problems**
- **Arthritis**
- **Asthma or respiratory problems**
- **Dizziness**
- **Drop attacks** (fainting, blackouts)
- **Double vision**

Signed **Date**

Appendix D:Participant Questionnaire

Median Nerve Biomechanics as a Consequence of a Simple Hand Movement.

Name:

Date:

Age:

Sex:

Dominant Hand:

Height:

Weight:

Presently are you suffering any pain/discomfort in the upper limb region?...Y/N

If the answer is yes could you please state if and when the problem was diagnosed and if treatment received at this time.

.....
.....

Have you ever had

- **Forearm, wrist or hand pain?..... Y/N**
- **Neck pain?..... Y/N**
- **Severe pins and needles or an altered sensation of the upper limb?.....Y/N**
- **Circulatory problems?..... Y/N**
- **Carpal tunnel syndrome?..... Y/N**
- **Tenosynovitis?..... Y/N**

- **Other problems that might affect upper limb movement?..... Y/N**

Please state.....

If the answer is yes to any of the above questions could you please state if and when the problem was diagnosed and the treatment received.

.....
.....

Have you ever broken a bone in your

- **Hand?..... Y/N**
- **Wrist?..... Y/N**
- **Forearm?..... Y/N**
- **Upper arm?..... Y/N**
- **Shoulder?..... Y/N**

To be filled in by the researcher.

Hand Measurements:

- **Palm length**
- **Length of 3rd digit**
- **Palm width**
 - **Hand ratio**

Appendix E (i): Individual values from non-symptomatic participants during the finger grip movement

Non – Symptomatic Participant number	Area mm ²			Flattening ratio			X co-ordinate mm	Y co-ordinate mm
	start	end	end-start	start	end	end-start	end-start	end-start
01	6.1	7.1	1.1	2.5	1.9	-0.6	1.0	-1.1
03	2.3	4.9	2.6	3.4	3.2	-0.2	1.7	-0.5
06	3.9	5.5	1.6	2.0	2.0	-0.1	0.6	0.2
07	3.8	5.0	1.1	2.0	1.7	-0.3	1.8	0.0
13	4.2	7.4	3.3	2.7	1.7	-1.0	1.5	0.5
14	2.0	3.5	1.5	4.0	2.5	-1.6	1.3	0.6
19	3.8	5.7	1.9	1.9	1.6	-0.3	2.4	0.7
Mean	3.7	5.6	1.9	2.7	2.1	-0.6	1.5	0.1
SE	1.34	1.36	0.79	0.80	0.57	0.53	0.56	0.64

Appendix E (ii): Individual values from non-symptomatic participants during the power grip movement

Non – Symptomatic Participant number	Area mm ²			Flattening ratio			X co-ordinate mm	Y co-ordinate mm
	start	end	end-start	start	end	end-start	end-start	end-start
01	2.5	4.5	2.0	3.7	2.0	-1.7	2.5	0.1
03	3.4	4.4	1.0	4.0	3.6	-0.4	3.0	0.1
07	3.2	4.3	1.1	3.3	2.1	-1.2	4.7	0.9
13	3.8	4.2	0.5	3.7	3.2	-0.5	1.4	0.0
14	3.3	3.7	0.3	3.2	2.1	-1.0	2.5	-0.1
19	2.5	5.0	2.5	5.0	2.5	-2.5	1.3	0.5
Mean	3.1	4.3	1.2	3.8	2.6	-1.2	2.6	0.2
SE	0.51	0.42	0.85	0.67	0.65	0.78	1.22	0.40

Appendix E (iii): Individual values from non-symptomatic participants during the pinch grip movement

Non – Symptomatic Participant number	Area mm ²			Flattening ratio			X co-ordinate mm	Y co-ordinate mm
	start	end	end-start	start	end	end-start	end-start	end-start
01	5.8	6.6	0.8	3.1	2.8	-0.4	2.2	0.1
03	4.5	4.6	0.1	4.2	3.1	-1.1	1.8	0.0
07	3.8	4.8	1.1	2.4	1.9	-0.4	2.0	0.4
13	5.0	5.1	0.1	2.4	1.9	-2.0	2.0	0.2
14	2.4	3.4	1.0	2.3	2.0	-0.2	0.7	-0.4
19	4.7	5.3	0.7	3.3	3.1	-0.2	0.7	0.2
AVE	4.4	5.0	0.6	2.9	2.5	0.4	1.6	0.1
SE	1.16	1.04	0.44	0.73	0.57	0.72	0.71	0.27

Appendix E (iv): Individual values from non-symptomatic participants during the thumb opposition movement

Non – Symptomatic Participant number	Area mm ²			Flattening ratio			X co-ordinate mm	Y co-ordinate mm
	start	end	end-start	start	end	end-start	end-start	end-start
01	5.9	6.1	0.2	2.7	2.3	-0.5	-0.3	-0.2
03	3.9	6.2	2.3	4.0	3.4	-0.6	-0.5	-0.8
07	3.3	5.0	1.7	2.4	1.6	-0.6	1.2	0.2
13	4.7	2.5	-2.2	3.0	3.1	0.3	-2.1	-0.5
14	2.4	3.4	1.0	2.3	2.0	-0.2	0.7	-0.4
19	3.0	4.0	1.0	2.9	2.7	-0.2	1.5	0.2
AVE	3.9	4.5	0.6	2.9	2.5	-0.4	0.1	-0.2
SE	1.26	1.48	1.56	0.61	0.65	0.05	1.34	0.38

Appendix F (i): Individual values from moderate and symptomatic participants during the finger grip movement

Non – Symptomatic Participant number	Area mm ²			Flattening ratio			X co- ordinate mm	Y co- ordinate mm
	start	end	end- start	start	end	end- start	end-start	end-start
Moderate Symptomatic								
02	3.6	3.8	0.2	2.3	1.2	-1.1	1.4	-0.8
09	4.6	3.0	-1.6	5.3	3.6	-1.7	-0.8	0.3
10	2.8	2.7	-0.1	1.8	2.5	0.8	-0.2	-0.4
16	3.4	4.2	0.8	2.5	3.1	0.6	1.1	0.4
Mean	3.6	3.4	-0.2	3.0	2.6	-0.3	0.4	-0.1
SD	0.72	0.70	1.01	1.57	1.05	1.25	1.03	0.59
Fully Symptomatic								
04	6.3	5.3	-1.0	2.4	5.2	2.8	0.6	-1.1
05	3.4	3.3	-0.1	1.3	1.1	-0.1	0.4	0.4
11	5.0	4.2	-0.8	1.5	2.6	1.1	0.2	0.0
12	7.8	4.8	-3.0	1.6	1.2	-0.3	0.6	-0.1
15	3.5	2.8	-0.6	1.7	2.3	0.6	0.2	-0.5
17	3.3	2.9	-0.5	3.0	3.6	0.6	0.3	0.2
18	4.8	3.1	-1.7	3.2	3.8	0.5	0.3	-0.3
20	6.8	4.9	-1.9	1.6	1.3	-0.3	0.2	0.7
Mean	5.1	3.9	-1.2	2.0	2.6	0.6	0.4	-0.1
SE	1.71	1.01	0.94	0.75	1.46	1.03	0.24	0.55

Appendix F (ii): Individual values from moderate and symptomatic participants during the power grip movement

Non – Symptomatic Participant number	Area mm ²			Flattening ratio			X co-ordinate mm	Y co-ordinate mm
	start	end	end-start	start	end	end-start	end-start	end-start
Moderate Symptomatic								
02	3.1	2.9	-0.2	3.7	2.8	-0.9	1.9	0.1
10	3.3	5.3	1.9	2.6	2.2	-0.4	1.4	0.1
16	3.6	3.8	0.2	2.5	2.1	-0.4	-0.2	0.3
Mean	3.3	4.0	0.6	2.9	2.4	-0.5	1.0	0.2
SD	0.20	1.18	1.13	0.67	0.36	0.31	1.10	0.11
Fully Symptomatic								
04	3.2	3.3	0.0	2.5	2.7	0.2	0.3	0.0
11	4.9	2.3	-2.6	2.6	3.6	1.1	0.9	-0.4
12	6.6	3.7	-2.9	3.0	3.8	0.8	0.4	-0.4
15	7.5	5.1	-2.4	2.1	2.1	0.0	0.7	-0.1
17	4.0	3.5	-0.4	3.4	4.2	0.9	0.9	0.1
Mean	5.2	3.6	-1.7	2.7	3.3	0.6	0.6	-0.2
SE	1.78	1.02	1.35	0.48	0.87	0.46	0.27	0.23

Appendix F (iii): Individual values from moderate and symptomatic participants during the pinch grip movement

Non – Symptomatic Participant number	Area mm ²			Flattening ratio			X co- ordinate mm	Y co- ordinate mm
	start	end	end- start	start	end	end- start	end-start	end-start
Moderate Symptomatic								
02	2.4	3.4	1.0	2.2	2.4	0.2	1.4	-0.1
10	3.6	2.8	-0.8	2.4	2.7	0.3	-0.3	0.2
16	2.8	3.5	0.6	3.4	1.9	-1.5	0.4	0.5
Mean	3.0	3.2	0.3	2.7	2.3	-0.3	0.5	0.2
SD	0.61	0.39	0.97	0.64	0.44	1.04	0.84	0.30
Fully Symptomatic								
04	3.7	2.7	-1.0	2.4	2.7	0.3	1.4	-0.5
11	3.8	2.6	-1.2	2.7	2.9	0.2	0.1	-0.1
12	5.8	4.1	-1.7	2.7	3.4	0.6	0.2	-0.6
15	6.0	3.8	-2.3	2.6	2.8	0.1	0.1	0.2
17	5.1	3.6	-1.5	2.9	3.2	0.3	0.2	0.2
Mean	4.9	3.3	-1.5	2.7	3.0	0.3	0.4	-0.2
SE	1.08	0.67	0.49	0.18	0.28	0.21	0.58	0.36

Appendix F (iv): Individual values from moderate and symptomatic participants during the thumb opposition movement

Non – Symptomatic Participant number	Area mm ²			Flattening ratio			X co- ordinate mm	Y co- ordinate mm
	start	end	end- start	start	end	end- start	end-start	end-start
Moderate Symptomatic								
02	3.2	4.0	0.8	2.2	2.2	0.0	1.2	-0.8
10	3.4	3.7	0.3	2.1	2.4	0.4	-0.4	0.1
16	3.8	4.1	0.2	1.6	1.9	0.3	-1.2	-0.4
Mean	3.5	3.9	0.5	2.0	2.2	0.2	-0.2	-0.4
SD	0.33	0.17	0.32	0.33	0.26	0.22	1.25	0.41
Fully Symptomatic								
04	4.2	4.2	0.0	2.6	2.8	0.3	0.0	0.0
11	3.0	2.2	-0.9	3.1	2.6	-0.5	-1.1	0.0
12	2.1	2.9	0.9	3.3	4.1	0.8	0.4	-0.5
15	4.0	4.0	0.0	1.7	2.5	0.7	-2.2	-0.8
17	4.7	5.0	0.3	2.9	3.5	0.6	0.3	-0.2
Mean	3.6	3.7	0.1	2.7	3.1	0.4	-0.5	-0.3
SE	1.04	1.10	0.63	0.62	0.70	0.53	1.12	0.34

Appendix G (i): The change in the individual values for cross sectional area during the finger grip movement at 5 points

Non-Symptomatic Participants	intervals				
	1	2	3	4	5
01	-1.49	0.07	2.10	-0.03	0.43
03	2.23	-0.67	0.47	0.46	0.06
06	0.60	0.10	0.40	0.30	0.19
07	0.71	-0.66	0.73	0.26	0.10
13	1.64	-0.81	1.63	0.09	0.70
14	2.22	-2.20	0.13	-0.39	0.78
19	0.99	-1.43	1.34	0.52	0.47
Mean	0.98	-0.80	0.97	0.17	0.39
SE	1.28	0.81	0.73	0.32	0.29

Moderate symptomatic Participants	Intervals				
	1	2	3	4	5
02	-1.20	0.48	0.37	0.35	0.20
09	-1.66	-0.14	-0.34	0.41	0.16
10	-0.01	0.19	0.52	0.24	-1.05
16	-0.61	0.60	0.40	0.30	0.12
Mean	-0.87	0.28	0.24	0.33	-0.14
SE	0.72	0.33	0.39	0.07	0.61

Fully symptomatic Participants	intervals				
	1	2	3	4	5
04	-0.80	-0.75	-0.58	0.73	0.43
05	-0.04	-0.40	0.16	0.07	0.08
11	-1.27	0.80	-0.20	-0.10	-0.01
12	-1.93	0.90	-0.90	-0.90	-0.17
15	-0.07	1.47	0.25	-0.99	-1.30
17	0.82	-1.19	0.97	-0.57	-0.49
18	-0.36	1.01	-0.19	-0.44	-1.71
20	-2.07	1.20	-0.40	-0.40	-0.20
Mean	-0.72	0.38	-0.11	-0.32	-0.42
SE	1.00	1.00	0.57	0.56	0.73

Appendix G (ii): The change in the individual values for flattening ratio during the finger grip movement at 5 points

Non-Symptomatic Participants	Intervals				
	1	2	3	4	5
01	-0.36	0.22	0.92	-0.13	-1.28
03	-1.29	2.61	0.09	-2.75	0.56
06	-0.12	1.58	-0.57	-0.62	-0.43
07	-0.63	-0.24	0.63	0.60	0.33
13	-0.73	1.41	-0.59	0.47	-1.57
14	-1.13	1.05	-0.48	0.48	-0.49
19	0.56	0.32	-0.56	0.45	-1.12
Mean	-0.53	0.85	-0.08	-0.21	-0.57
SE	0.63	0.74	0.64	1.20	0.81

Moderate symptomatic Participants	Intervals				
	1	2	3	4	5
02	-0.12	0.70	-0.42	-0.24	-1.05
09	0.43	-1.51	0.70	-0.26	0.97
10	0.24	0.26	0.44	0.52	-0.67
16	0.50	-0.45	0.14	0.25	0.20
Mean	0.26	-0.25	0.21	0.07	-0.14
SE	0.28	0.96	0.48	0.38	0.91

Fully symptomatic Participants	Intervals				
	1	2	3	4	5
04	0.18	-0.16	0.15	0.14	2.52
05	0.36	0.87	-0.92	0.63	-1.06
11	0.20	0.39	-0.30	0.37	0.43
12	0.70	0.50	-0.19	-0.74	-0.60
15	0.87	0.12	0.33	-0.79	0.06
17	0.38	-0.03	0.23	0.27	-0.20
18	0.39	0.44	-0.11	0.26	-0.43
20	0.20	0.59	0.50	-1.36	-0.25
Mean	0.41	0.34	-0.04	-0.15	0.06
SE	0.25	0.34	0.45	0.71	1.09

Appendix G (iii): The change in the individual values for X coordinate during the finger grip movement at 5 points

Non-Symptomatic Participants	Intervals				
	1	2	3	4	5
01	1.78	-1.52	0.77	0.69	0.31
03	2.88	0.36	-1.35	-0.86	-0.30
06	3.68	-1.09	-0.17	-0.45	-0.32
07	1.97	-2.00	0.56	0.59	0.64
13	1.31	-0.72	-0.28	-0.21	1.41
14	1.06	0.05	-0.15	-0.08	0.47
19	1.78	-0.80	-0.75	0.16	0.40
Mean	2.07	-0.82	-0.20	-0.02	0.37
SE	0.91	0.83	0.73	0.55	0.59

Moderate symptomatic Participants	Intervals				
	1	2	3	4	5
02	2.03	0.35	-0.84	-0.24	0.09
09	1.50	-0.45	-0.69	-0.03	-1.10
10	2.45	1.12	0.29	0.22	-4.31
16	1.20	-0.14	-0.51	0.31	0.21
Mean	1.79	0.22	-0.44	0.07	-1.28
SE	0.56	0.69	0.51	0.25	2.10

Fully symptomatic Participants	Intervals				
	1	2	3	4	5
04	0.72	-1.22	-0.95	0.89	0.27
05	0.77	-1.50	0.42	-0.10	0.77
11	0.89	-0.59	-0.22	0.22	-0.18
12	0.42	-0.21	0.11	-0.44	-0.13
15	1.14	-1.11	0.14	-0.52	0.53
17	0.63	0.10	0.28	0.29	-1.03
18	0.48	-0.53	0.57	-0.44	0.18
20	0.75	-0.27	-0.59	0.09	0.20
Mean	0.72	-0.67	-0.03	0.00	0.08
SE	0.23	0.56	0.52	0.48	0.55

Appendix G (iv): The change in the individual values for Y co-ordinate during the finger grip movement at 5 points

Non-Symptomatic Participants	Intervals				
	1	2	3	4	5
01	-0.08	-0.14	0.04	-0.40	-0.47
03	-0.54	0.32	0.28	-0.15	-0.37
06	-0.27	0.31	0.02	0.12	0.05
07	-0.63	0.14	0.06	0.27	0.14
13	-0.20	0.43	-0.03	0.08	0.23
14	-0.17	0.73	0.03	-0.25	0.31
19	-0.30	0.37	-0.23	0.34	0.49
Mean	-0.31	0.31	0.02	0.00	0.05
SE	0.20	0.27	0.15	0.28	0.35

Moderate symptomatic Participants	Intervals				
	1	2	3	4	5
02	-0.29	-0.39	0.16	0.10	-0.38
09	0.78	-0.20	0.80	0.56	-1.60
10	-0.62	0.30	-0.27	0.23	-0.06
16	0.10	-0.17	0.32	0.30	-0.13
Mean	-0.01	-0.11	0.25	0.30	-0.54
SE	0.60	0.29	0.44	0.19	0.72

Fully symptomatic Participants	Intervals				
	1	2	3	4	5
04	0.18	-0.78	0.21	0.26	-0.99
05	-0.68	0.49	0.76	-0.19	-0.02
11	0.03	-0.19	0.24	0.01	-0.10
12	0.11	0.09	-0.06	-0.09	-0.10
15	-0.22	-0.17	0.26	-0.05	-0.28
17	0.41	-0.12	0.04	-0.11	-0.01
18	0.05	-0.35	0.08	-0.18	0.09
20	0.24	-0.08	-0.25	-0.21	0.96
Mean	0.02	-0.14	0.16	-0.07	-0.06
SE	0.33	0.36	0.30	0.15	0.53

Appendix H (i): The change in the individual values for cross sectional area during the power grip movement at 5 points

Non-Symptomatic Participants	Intervals				
	1	2	3	4	5
01	1.69	-1.80	1.21	-0.07	0.92
03	0.79	0.26	0.15	0.00	-0.21
07	1.04	0.08	-0.42	-0.13	0.57
13	0.93	-1.75	0.32	0.40	0.57
14	0.93	-1.62	0.53	0.15	0.36
19	1.25	0.18	0.16	0.48	0.45
Mean	1.10	-0.78	0.32	0.14	0.44
SE	0.33	1.04	0.54	0.25	0.37

Moderate symptomatic Participants	Intervals				
	1	2	3	4	5
02	-0.71	0.93	0.63	-0.82	-0.26
10	-0.20	0.68	-0.02	0.03	1.43
16	0.03	1.23	-1.75	0.52	0.17
Mean	-0.29	0.95	-0.38	-0.09	0.45
SE	0.38	0.28	1.23	0.68	0.88

Fully symptomatic Participants	Intervals				
	1	2	3	4	5
04	-0.32	0.78	-0.09	-0.53	0.18
05	0.00	0.00	0.00	0.00	0.00
11	-2.06	1.24	1.13	-2.25	-0.71
12	-0.39	0.02	-0.46	-0.21	-1.84
15	-0.40	0.43	-1.68	-0.38	-0.37
17	-0.97	0.76	0.35	-0.05	-0.52
Mean	-0.69	0.54	-0.12	-0.57	-0.54
SE	0.74	0.48	0.93	0.85	0.71

Appendix H (ii): The change in the individual values for flattening ratio during the power grip movement at 5 points

Non-Symptomatic Participants	Intervals				
	1	2	3	4	5
01	-1.01	0.36	-0.81	0.27	-0.51
03	0.12	-0.36	-0.24	-0.26	0.30
07	-0.42	0.03	-0.30	-0.24	-0.31
13	-0.65	0.12	0.36	-0.06	-0.26
14	-0.66	-0.33	0.26	0.26	-0.56
19	-0.64	-1.12	-0.11	-0.37	-0.25
Mean	-0.54	-0.22	-0.14	-0.07	-0.27
SE	0.38	0.52	0.42	0.28	0.31

Moderate symptomatic Participants	Intervals				
	1	2	3	4	5
02	-0.95	-0.08	0.80	0.48	-1.16
10	-0.24	-0.16	0.15	0.41	-0.52
16	0.43	-0.69	0.77	-0.03	-0.87
Mean	-0.25	-0.31	0.57	0.29	-0.85
SE	0.69	0.33	0.37	0.28	0.32

Fully symptomatic Participants	Intervals				
	1	2	3	4	5
04	0.59	-0.12	0.36	0.30	-0.97
11	3.01	-0.48	0.32	0.58	0.20
12	0.45	0.39	-0.13	0.46	0.02
15	-0.88	0.37	0.28	-0.45	-0.17
17	1.94	-0.09	-0.48	-0.38	1.15
Mean	1.02	0.01	0.07	0.10	0.05
SE	1.50	0.37	0.37	0.48	0.76

Appendix H (iii): The change in the individual values for X coordinate during the power grip movement at 5 points

Non-Symptomatic Participants	Intervals				
	1	2	3	4	5
01	3.26	-2.94	-0.94	3.62	-1.45
03	2.20	-0.60	-0.57	0.20	1.80
07	1.94	0.44	0.75	0.66	0.86
13	0.97	-0.06	-0.42	0.39	0.56
14	1.37	0.87	0.31	-0.67	0.64
19	1.09	-0.55	-0.08	0.48	0.37
Mean	1.80	-0.47	-0.16	0.78	0.46
SE	0.86	1.34	0.61	1.46	1.06

Moderate symptomatic Participants	Intervals				
	1	2	3	4	5
02	-0.84	0.22	1.24	1.35	-0.10
10	0.03	0.96	0.97	-0.63	0.07
16	0.90	-0.86	-0.37	0.27	-0.16
Mean	0.03	0.11	0.62	0.33	-0.06
SE	0.87	0.91	0.86	0.99	0.12

Fully symptomatic Participants	Intervals				
	1	2	3	4	5
04	-0.93	1.39	0.07	1.06	-1.29
11	0.01	-0.52	0.93	-0.26	0.76
12	-0.18	-0.71	0.18	0.12	1.00
15	1.27	-0.68	-0.46	-0.01	0.61
17	0.37	-0.39	0.70	-0.04	0.24
Mean	0.11	-0.18	0.28	0.17	0.26
SE	0.80	0.89	0.55	0.51	0.91

Appendix H (iv): The change in the individual values for Y co-ordinate during the power grip movement at 5 points

Non-Symptomatic Participants	Intervals				
	1	2	3	4	5
01	-0.11	-0.36	0.29	-0.02	0.32
03	0.03	0.06	-0.05	0.00	0.02
07	-0.23	0.38	0.47	0.36	-0.04
13	0.47	0.21	-0.48	-0.04	-0.20
14	-0.21	0.02	0.24	-0.12	-0.04
19	-0.12	0.29	0.04	0.20	0.08
Mean	-0.03	0.10	0.09	0.06	0.02
SE	0.26	0.26	0.33	0.18	0.17

Moderate symptomatic Participants	Intervals				
	1	2	3	4	5
02	0.00	-0.10	0.22	0.19	-0.19
10	0.20	-0.44	0.25	-0.03	0.17
16	0.07	0.55	-0.50	-0.03	0.23
Mean	0.09	0.00	-0.01	0.04	0.07
SE	0.10	0.50	0.42	0.13	0.23

Fully symptomatic Participants	Intervals				
	1	2	3	4	5
04	0.14	0.28	-0.28	-0.05	-0.06
11	-0.54	0.73	-0.08	-0.29	-0.18
12	-0.09	-0.09	-0.03	-0.10	-0.12
15	0.21	-0.33	0.07	-0.32	0.29
17	0.77	0.11	-0.05	-0.04	-0.71
Mean	0.10	0.14	-0.07	-0.16	-0.16
SE	0.48	0.40	0.13	0.14	0.36

Appendix I (i): The change in the individual values for cross sectional area during the pinch grip movement at 5 points

Non-Symptomatic Participants	Intervals				
	1	2	3	4	5
01	0.30	-0.74	-0.29	0.20	1.37
03	1.56	-0.27	-0.14	0.54	-1.62
07	1.37	-0.57	-0.29	0.12	0.43
13	-0.37	-0.83	-0.32	-0.27	1.91
14	1.49	-1.56	0.12	0.08	0.89
19	1.14	-0.86	-0.49	0.31	0.55
Mean	0.92	-0.80	-0.24	0.16	0.59
SE	0.78	0.43	0.21	0.27	1.21

Moderate symptomatic Participants	Intervals				
	1	2	3	4	5
02	0.31	0.66	-0.04	-0.57	0.63
10	-1.43	0.50	0.09	-0.07	0.07
16	0.80	0.43	-0.49	-0.51	0.42
Mean	-0.11	0.53	-0.15	-0.38	0.37
SE	1.17	0.12	0.30	0.27	0.28

Fully symptomatic Participants	Intervals				
	1	2	3	4	5
04	-0.91	0.99	-0.75	0.16	-0.53
11	-1.11	0.23	-0.42	0.30	-0.23
12	-1.08	2.03	-0.13	1.59	-4.09
15	-0.92	-0.37	1.17	0.50	-2.66
17	0.64	1.03	-2.70	1.14	-1.60
Mean	-0.68	0.78	-0.57	0.74	-1.82
SE	0.74	0.91	1.40	0.61	1.59

Appendix I (ii): The change in the individual values for flattening ratio during the pinch grip movement at 5 points

Non-Symptomatic Participants	Intervals				
	1	2	3	4	5
01	-0.34	0.12	0.07	-0.31	0.09
03	-1.00	0.58	-0.28	-0.45	0.09
07	0.06	-0.17	0.30	-0.25	-0.37
13	-0.05	0.41	0.18	0.19	-1.15
14	0.20	0.08	-0.69	0.31	-0.15
19	-0.64	-0.03	0.22	0.22	0.08
Mean	-0.30	0.17	-0.03	-0.05	-0.23
SE	0.46	0.28	0.38	0.33	0.49

Moderate symptomatic Participants	Intervals				
	1	2	3	4	5
02	0.01	0.26	-0.14	1.19	-1.08
10	0.44	0.03	-0.45	0.28	0.00
16	-1.28	-0.29	0.14	0.46	-0.55
Mean	-0.28	0.00	-0.15	0.64	-0.54
SE	0.89	0.28	0.30	0.48	0.54

Fully symptomatic Participants	Intervals				
	1	2	3	4	5
04	0.08	0.52	-0.72	0.34	0.12
11	0.54	-0.37	-0.34	0.12	0.23
12	0.58	-0.39	-0.10	-0.34	0.90
15	-0.23	0.11	0.10	0.23	-0.10
17	0.38	-0.21	0.77	-0.33	-0.28
Mean	0.27	-0.07	-0.06	0.01	0.17
SE	0.34	0.39	0.55	0.32	0.45

Appendix I (iii): The change in the individual values for X co-ordinate during the pinch grip movement at 5 points

Non-Symptomatic Participants	Intervals				
	1	2	3	4	5
01	1.352	0.198	0.502	0.456	-0.27
03	0.354	-0.313	0.437	0.328	1.00
07	1.178	-0.110	0.564	0.168	0.20
13	2.804	-0.116	-0.456	-0.130	-0.08
14	0.952	-0.436	-0.316	0.218	0.25
19	0.948	-0.474	0.098	-0.342	0.46
Mean	1.26	-0.21	0.14	0.12	0.26
SE	0.83	0.25	0.44	0.30	0.44

Moderate symptomatic Participants	Intervals				
	1	2	3	4	5
02	0.730	0.252	0.716	-1.264	0.94
10	-0.378	0.898	-0.214	-0.198	-0.41
16	0.738	0.060	-0.247	-0.067	-0.05
Mean	0.36	0.40	0.08	-0.51	0.16
SE	0.64	0.44	0.55	0.66	0.70

Fully symptomatic Participants	Intervals				
	1	2	3	4	5
04	1.563	-0.034	-0.190	0.272	-0.17
11	0.580	-0.338	-0.274	-0.628	0.77
12	1.178	-1.454	0.218	-0.576	0.86
15	0.876	-0.192	-0.590	-0.302	0.28
17	-0.038	0.092	-0.079	-0.353	0.57
Mean	0.83	-0.39	-0.18	-0.32	0.46
SE	0.61	0.62	0.29	0.36	0.42

Appendix I (iv): The change in the individual values for Y co-ordinate during the pinch grip movement at 5 points

Non-Symptomatic Participants	Intervals				
	1	2	3	4	5
01	-0.27	0.16	0.35	-0.28	0.17
03	0.46	0.18	-0.12	0.07	-0.60
07	0.22	-0.15	-0.01	0.19	0.19
13	1.20	-0.10	-0.06	-0.16	-0.69
14	-0.11	0.02	0.32	-0.49	-0.12
19	0.05	0.01	0.05	-0.14	0.21
Mean	0.26	0.02	0.09	-0.14	-0.14
SE	0.53	0.13	0.20	0.24	0.41

Moderate symptomatic Participants	Intervals				
	1	2	3	4	5
02	0.00	-0.02	0.27	-0.47	0.08
10	-0.15	0.33	-0.30	0.09	0.23
16	0.55	-0.15	0.01	0.04	0.00
Mean	0.13	0.05	-0.01	-0.11	0.10
SE	0.37	0.25	0.28	0.31	0.12

Fully symptomatic Participants	Intervals				
	1	2	3	4	5
04	-0.51	0.41	-0.33	-0.03	0.00
11	0.04	0.13	-0.07	-0.04	-0.21
12	-0.36	0.30	0.15	-0.12	-0.55
15	0.01	0.24	-0.19	0.12	0.04
17	0.14	0.06	-0.17	0.14	0.01
Mean	-0.14	0.23	-0.12	0.01	-0.14
SE	0.28	0.14	0.18	0.11	0.25

Appendix J (i): The change in the individual values for cross sectional area during the thumb opposition movement at 5 points

Non-Symptomatic Participants	Intervals				
	1	2	3	4	5
01	0.85	-2.11	0.36	0.59	0.53
03	0.78	0.45	0.31	0.43	0.30
07	1.18	-0.60	1.11	0.44	-0.41
13	-0.88	-1.75	-0.63	1.15	-0.07
14	1.57	-1.84	0.55	0.65	0.09
19	0.88	0.12	-0.10	0.29	-0.20
Mean	0.73	-0.96	0.27	0.59	0.04
SE	0.84	1.10	0.59	0.30	0.34

Moderate symptomatic Participants	Intervals				
	1	2	3	4	5
02	1.33	0.47	-1.45	-0.40	0.89
10	-1.20	1.35	0.65	-0.92	0.44
16	0.53	0.47	-0.01	-0.42	-0.32
Mean	0.22	0.76	-0.27	-0.58	0.34
SE	1.29	0.51	1.08	0.30	0.61

Fully symptomatic Participants	Intervals				
	1	2	3	4	5
04	0.44	-0.62	-0.16	0.87	-0.57
11	0.60	-0.97	0.10	-0.35	-0.23
12	1.96	-0.39	-0.06	-0.16	-0.48
15	1.01	0.62	0.63	-1.47	-0.74
17	1.62	-0.95	-1.56	-0.07	1.30
Mean	1.12	-0.46	-0.21	-0.24	-0.14
SE	0.65	0.65	0.82	0.84	0.83

Appendix J (ii): The change in the individual values for flattening ratio during the thumb opposition movement at 5 points

Non-Symptomatic Participants	Intervals				
	1	2	3	4	5
01	-0.69	0.30	-0.10	-0.12	0.12
03	-0.59	0.82	-0.60	0.11	-0.38
07	-1.08	1.15	-0.18	0.49	-1.16
13	-0.48	1.25	0.19	-1.03	0.19
14	-0.47	0.90	-0.20	-0.36	-0.11
19	0.40	-0.37	0.46	-0.33	-0.39
Mean	-0.49	0.68	-0.07	-0.21	-0.29
SE	0.49	0.61	0.36	0.51	0.49

Moderate symptomatic Participants	Intervals				
	1	2	3	4	5
02	0.75	-1.02	-0.03	0.18	0.09
10	0.51	-0.38	0.03	0.12	0.07
16	0.39	-0.19	0.28	-0.20	0.06
Mean	0.55	-0.53	0.09	0.03	0.07
SE	0.18	0.43	0.16	0.21	0.01

Fully symptomatic Participants	Intervals				
	1	2	3	4	5
04	0.35	0.01	-0.21	0.01	0.11
11	0.54	-1.03	0.06	0.30	-0.37
12	0.63	0.14	-1.23	0.65	0.60
15	0.62	0.01	0.07	-0.55	0.58
17	0.69	-0.39	0.17	-0.19	0.33
Mean	0.57	-0.25	-0.23	0.05	0.25
SE	0.13	0.48	0.58	0.46	0.40

Appendix J (iii): The change in the individual values for X co-ordinate during the thumb opposition movement at 5 points

Non-Symptomatic Participants	Intervals				
	1	2	3	4	5
01	-0.58	-0.39	-0.43	0.16	-0.26
03	-0.57	-0.20	-0.28	-0.45	-0.17
07	-0.89	-0.73	0.55	0.33	0.15
13	0.17	-1.88	0.23	-0.33	0.04
14	-1.20	-1.63	0.54	0.33	0.23
19	-1.05	-0.03	0.45	-0.30	0.34
Mean	-0.69	-0.81	0.18	-0.04	0.05
SE	0.49	0.77	0.43	0.36	0.23

Moderate symptomatic Participants	Intervals				
	1	2	3	4	5
02	-2.35	-0.75	-0.31	-1.02	0.94
10	0.80	-0.13	0.80	0.12	-0.44
16	0.83	0.35	0.06	-0.36	-0.45
Mean	-0.24	-0.18	0.18	-0.42	0.02
SE	1.82	0.55	0.56	0.57	0.80

Fully symptomatic Participants	Intervals				
	1	2	3	4	5
04	0.82	0.67	-0.02	-0.13	0.29
11	0.82	0.40	-0.68	-0.28	0.26
12	0.61	0.36	0.23	0.16	0.24
15	2.07	-0.24	0.79	0.70	-1.39
17	0.08	0.12	-0.02	-0.27	0.56
Mean	0.88	0.26	0.06	0.04	-0.01
SE	0.73	0.34	0.53	0.41	0.78

Appendix J (iv): The change in the individual values for Y co-ordinate during the thumb opposition movement at 5 points

Non-Symptomatic Participants	Intervals				
	1	2	3	4	5
01	-0.20	0.08	-0.12	0.03	-0.03
03	-0.21	0.19	-0.35	-0.31	-0.11
07	0.57	-0.80	-0.02	0.23	0.20
13	-0.35	-0.16	0.24	-0.01	-0.17
14	-0.29	-0.18	-0.04	0.07	0.05
19	0.08	-0.15	0.18	-0.10	0.19
Mean	-0.07	-0.17	-0.02	-0.02	0.02
SE	0.35	0.34	0.21	0.18	0.15

Moderate symptomatic Participants	Intervals				
	1	2	3	4	5
02	-0.11	0.31	0.24	0.07	-1.27
10	-0.05	0.01	-0.04	0.01	0.12
16	0.04	0.04	-0.44	0.25	-0.25
Mean	-0.04	0.12	-0.08	0.11	-0.47
SE	0.07	0.16	0.34	0.12	0.72

Fully symptomatic Participants	Intervals				
	1	2	3	4	5
04	-0.08	0.21	-0.27	-0.02	0.15
11	0.05	-0.16	0.29	-0.10	-0.09
12	-0.71	0.23	0.09	0.44	-0.55
15	-0.36	-0.15	0.28	0.48	-1.04
17	-0.05	0.05	-0.13	0.18	-0.22
Mean	-0.23	0.04	0.05	0.20	-0.35
SE	0.31	0.19	0.25	0.26	0.46

References

- Adams, J.H. Duchen, L.W. 5th ed. (1992). *Greenfield's Neuropathology*. Oxford University Press. New York. 1160-6.
- Altinok, T. B. Karakas, H.M. Sigirci, A. Alkan, A. Kayhan, A. Yologlu, S. (2004). Ultrasonographic assessment of mild and moderate idiopathic carpal tunnel syndrome. *Clinical Radiology*, (59), 916-925.
- Armstrong, T.J. Buckle, P. Fine, L.J. Hagberg, M. Jonsson, B. Kilbourn, A. Kuorinka, I. Silverstein, B.A. Sjogaad, G. Viikari-Juntura, E. (1993). A conceptual model for work-related neck and upper limb musculoskeletal disorders. *Scandinavian Journal of work and Enviromental Health*, (19), 73-84.
- Ayoub, M. MacKenzie, H. Deivanayagam, S. (1976). *Training manuel in occupational ergonomics*. Lubbock, Texas: Texas Technical University.
- Baatenburg De Jong, R. J. Rongen, R. J. De Jong, P. C. Lamerisy, J. S. Knegt, P. (1988). Screening for lymph nodes in the neck with ultrasound. *Clinical Otolaryngology & Allied Sciences*. 13 (1): 5–9.
- Barr, A.E. Barbe, M.F. (2002). Pathophysiological Tissue Changes Associated With Repetitive Movement: A Review of the Evidence. *Physical Therapy*, 82 (2), 173-187.
- Baumann, F. Karlikaya, G. Yuksel, G. Citci, B. Kose, G. Tireli, H. (2007). The subclinical incidence of CTS in pregnancy: assessment of median nerve impairment in

asymptomatic pregnant women. *Neurology, Neurophysiology and Neuroscience*. 3: 1-9.

Berkow R, (1997). *The Merck Manual of Medical Information*. Merck & Co.; Whitehouse Station, New Jersey. 330

Benacerraf, A. Benson, C.B. Abuhamad, A.Z. Copel, J.A. Abramowicz, J.S. Devore, G.R. Doubilet, P.M. Lee, W. (2005). Three- and 4-dimensional ultrasound in obstetrics and gynecology: Proceedings of the American Institute of Ultrasound in Medicine Consensus Conference. *Journal of Ultrasound in Medicine*. 24 (12): 1587–1597.

Bey, M.J. Kline, S. K. Tashman, S. Zael, R. (2008). Accuracy of biplane x-ray imaging combined with model-based tracking for measuring in-vivo patellofemoral joint motion. *Journal of Orthopaedic Surgery and Research*. 3:38.

Blair, D.J. (1983). Gallbladder Ultrasonography. *Canadian Family Physician*. 29: 2264.

Bodner, G. Buchberger, W. Schocke, M. (2001). Radial nerve palsy associated with humeral shaft fracture: evaluation with ultrasound – initial experience. *Radiology*, 219, 811-816.

Boocock, M.G. Collier, G. McNair, P.J. Simmonds, M. Larmer, P.J. Armstrong, B. (2009). A framework for the classification and diagnosis of work-related upper extremity conditions: systematic review. *Semin Arthritis Rheum*, 38, (5), 407-408.

Brinckmann, J. Notbohm, H. Müller, P.K. (2005). *Collagen, topics in current chemistry*. Berlin. Springer.

Brossmann, J. Muhle, C. Schroder, C. Melchert, U.H. Bull, C.C. Spielmann, R.P. Heller, M. (1993). Patellar tracking patterns during active and passive knee extension: evaluation with motion-triggered cine MR imaging. *Radiology*. 187:205–212.

Brown, D.F. Rosen, C.L. Wolfe, R.E. (1997). Renal ultrasonography. *Emergency Medicine Clinics of North America*. 15(4):877-93.

Buchberger, W. Strasser, K. Jungwirth, W. (1991). High-resolution ultrasonography of the carpal tunnel. *Journal of Ultrasound in Medicine*, 10, 531-537.

Buchberger, W. Judmaier, W. Birbamer, G. Lenar, M. Schmidauer, C. (1992). Carpal tunnel syndrome: diagnosis with high resolution sonography. *American Journal of Radiology*, 159, 793-798.

Buckle, P.W. (1997). Work factors and upper limb disorders. *British Medical Journal*, 315 (22), 1360-3.

Buckle, P.W. Devereux, J.J. (2002). The nature of work-related neck and upper limb musculoskeletal disorders. *Applied Ergonomics*, (33), 207-217.

- Butler, D. (1991). *Mobilisation of the nervous system*. Philadelphia. Churchill Livingstone.
- Cameron, J.R. Skofronick, J.G. (1978). *Medical Physics*. London. John Wiley & Sons Inc.
- Campbell, W. (1997). Diagnosis and management of common compression and entrapment neuropathies. *Clinical Neurology*, 15 (3), 549-567.
- Carls, S. (1961). The static muscle load in different work positions: an electromyographic study. *Ergonomics*, 4 (3), 193 – 211.
- Cass, K. Thompson, C.M. Tromans, C. Wood, I.C.J. (2002). Evaluation of the validity and reliability of A-scan ultrasound biometry with a single use disposable cover. *British Journal of Ophthalmology*. 86: 344-349.
- Chaffin, D.B. Andersson, G.B.J. Martin, B.J. (1999). *Occupational Biomechanics* (3rd ed.). New York: John Wiley & Sons.
- Chemali, K. R. T. (2005). Electrodiagnostic testing of nerves and muscles: when, why, and how to order. *Cleveland Clinical Journal of Medicine*, (72), 37-48.
- Comi, G. Lozza, L. Galardi, G. Ghilardi, M.F. Medaglini, S. Canal. N. (1985). Presence of carpal tunnel syndrome in diabetics: Effect of age, sex, diabetes duration and polyneuropathy. *Acta Diabetologica*, 22 (3), 259-262.

- Cochran, W. G. Third ed. (1977). *Sampling Techniques*. Harvard University USA. Wiley.
- Cribb, A. M. Scott, J. E. 1995. In: *Tendon response to tensile-stress - an ultrastructural investigation of collagen - proteoglycan interactions in stressed tendon*. Cambridge. Cambridge University Press: 423-428.
- Debonnie, J. C. Pauls, C. Fievez, M. Wibin, E. (1981). Prospective evaluation of the diagnostic accuracy of liver ultrasonography. *International Journal of Gastroenterology and Hepatology*. 22(2): 130–135.
- Delleman, N.J. Haslegrave, C.M. Chaffin, D.B. (2004). *Working postures and movements: tools fo evaluation and engineering*. London and New York: CRC Press.
- Dilley, A. Lynn, B. Greening, J. DeLeon, N. (2003). Quantitative in vivo studies of median nerve sliding in response to wrist, elbow, shoulder and neck movements. *Clinical Biomechanics*.18: 899– 907.
- Dogra, V.S. (2008). Role of ultrasonography in testicular and scrotal trauma. *Radiographics*. 28:1617-1629.
- Douglas P.S. (2007). Appropriateness criteria for transthoracic and transesophageal echocardiography. *Journal of the American College of Cardiology*. 50:187-204.

Draper, C. E. Besier, T. F. Santos, J. M. Jennings, F. Fredericson, M. Gold, G. E. Beaupre, G. S. Delp, S. L. (2009). Using real-time MRI to quantify altered joint kinematics in subjects with patellofemoral pain and to evaluate the effects of a patellar brace or sleeve on joint motion. *Journal of Orthopaedic Research*. 366: 2001.

Driscoll, P. Glasby, M. Lawson, G. (2002). An in vivo study of peripheral nerves in continuity: biomechanical and physiological responses to elongation. *Journal of Orthopaedic Research*. 20: 370– 375.

DuBose, T. J. Baker, A. L. (2009). Confusion and Direction in Diagnostic Doppler Sonography. *Journal of Diagnostic Medical Sonography*. 25: 3 173-177.

Dupuy, D.E. Hangen, D.H. Zachazewski, J.E. Boland, A.L. Palmer, W. (1997). Kinematic CT of the patellofemoral joint. *American Journal of Roentgenology*. 169: 211-215.

Dyck, P. Lais, A. Giannini, C. Engelstad, J. (1990). Structural alterations of nerve during cuff compression. *Proceedings for the National Academy of Science, USA*. 87:9828– 9832.

Eliceiri, K. Rueden, C. (2005). Tools for visualizing multidimensional images from living specimens. *Photochem Photobio.*, 81 (5), 1116–22.

Ellis, J.R.C. McNally, E.G. Scott, P.M. (2002). Ultrasound of peripheral nerves. *Imagin*, 14, 217-222.

Erel, E. Dilley, A. Greening, J. Morris, V. Cohen, B. Lynn, B. (2003). Longitudinal sliding of the median nerve in patients with carpal tunnel syndrome. *Journal of Hand Surgery*, 28, 439-443.

Erselcan, T. Topalkara, K. Nacitarhan, V. Akyuz, A. Dogan, D. (2001). Carpal tunnel syndrome leads to significant bone loss in metacarpal bones. *Journal of Bone and Mineral Metabolism*, 19 (5), 317-320.

Evans, D. (2006). Physical and technical Principals. *Frontiers of Neurology and Neuroscience*, 21, 1-18.

Feleppa, E.J. Kaisar Alam, S. Deng, C. X. (2002). Emerging ultrasound technologies for early markers of disease. *Journal Disease Markers*. 18 (5): 249-268.

Fornage, B. (1988). Peripheral nerves of the extremities; imaging with ultrasonography. *Radiology*, 167: 179-182.

Fredberg, U. Stengaard-Pedersen, K. (2008). Chronic tendinopathy tissue pathology, pain mechanisms, and etiology with a special focus on inflammation. *Scandinavian Journal of Medicine & Science in Sports*.18 (1): 3–15.

Freedman, K.B. Hart, R.A. (2003). Clinical Evaluation. In: Bernstein, J. *Muskuloskeletal Medicine*. Rosemont IL.: American Academy of Orthopaedic Surgeons Editorial Board, 287-416.

- Freivalds, A. (2004). *Biomechanics of the upper limb: mechanics, modeling and musculoskeletal injuries*. London & New York. CRC Press.
- Girish, V. Vijayalakshmi, A. (2004). Affordable image analysis using NIH Image/ImageJ. *Indian J Cancer*, 41 (1), 47.
- Grant, G.A. Goodkin, R. Kliot, M. (1999). Evaluation and surgical management of peripheral nerve problems. *Neurosurgery*. 44 (4):825-39). Schwartz, S.I. Principles of Surgery. 7th ed. (1999). McGraw-Hill. New York. 2048-53.
- Grechenig, W. Clement, H. Peicha, G. Klein, A. Weiglein, A. (2000). Ultrasonographic imaging of the sciatic nerve in the thigh. *Biomedizinische Technik*, 45(11), 298-303.
- Greening, J. L. Leary, R. Warren, L. O'Higgins, P. Hall-Craggs, M. (2001). The use of ultrasound imaging to demonstrate reduced movement of the median nerve during wrist flexion in patients with non-specific arm pain. *Journal of Hand Surgery*, 26B (5), 401-406.
- Gritzmann, N. (1989). Sonography of the salivary glands. *American Journal of Roentgenology*. 153 (1): 161-166.
- Gusbers Van Wijk , C.M.T. Kolk, A.M. (1997). Sex differences in physical symptoms: the contribution of symptom perception theory. *Soc Sci Med*, 45 (2), 231-46.

Haacke, E. M. Brown, R.W. Thompson, M.L. Venkatesan, R. (1999). *Magnetic resonance imaging: Physical principles and sequence design*. New York. John Wiley.

Hagberg, M. Wegman, D.H. (1987). Prevalence rates and odds ratios of shoulder-neck diseases in different occupational groups. *Br J Ind Med*, 44, 602-10.

Hagberg, M. Silverstein, B. Wells, R. Smith, M.J. Hendrick, H.W. Carayon, P. Perusse, M. (1995). *Work-related musculoskeletal disorders (WMSDs): a reference book for prevention*. London. Taylor & Francis.

Hakim, A.J. Cherkas, L. El Zayat, S. Macgregor, A.J. Spector, T.D. (2002). The Genetic Contribution to Carpal Tunnel Syndrome in Women: a Twin Study. *Arthritis & Rheumatis*,. 47 (3), 275–279.

Hamill, J. Knutzen, K. M. (1995). *Biomechanical basis of human movement*. Philadelphia & Baltimore: Williams & Wilkins.

Hazelton, H. Smidt, G. Flatt, A. Stephens, R. (1975). The influence of wrist position on the force produced by the finger flexors. *Journal of Biomechanics*, 8, 301-306.

Health and Safety Commission. (2003). *Health and safety statistics 2002/2003*. Sudbury UK: HSE Books.

- Heinemeyer, O. Reimers, C.D. (1999). Ultrasound of radial, ulnar, median, and sciatic nerves in healthy subjects and patients with hereditary motor and sensory neuropathies. *Ultrasound Med. Biol.* 25, 481-485.
- Hertling, D. Kessler, R.M. (2006). *Management of common musculoskeletal disorders*. (4th Ed). London. Lippincott Williams and Wilkins.
- Hill, N.A. Howard, F.M. Huffer, B.R. (1985). The incomplete anterior interosseous nerve syndrome. *J Hand Surg Am*, 10 (1), 4-16.
- Hoochman, M. Zilberfarb, L. (2004). Nerves in a pinch: imaging of nerve compression syndromes. *Radiologic Clinics of North America*, 221-245.
- Hulmes, D. J. S., (2002). Building collagen molecules, fibrils, and suprafibrillar structures. *Journal of Structural Biology*. 137 (1-2): 2-10.
- Ilyas, A. Ast, M. Schaffer, A.A. Thoder, J. (2007). De Quervain tenosynovitis of the wrist. *J Am Acad Ortho Sur*, 15 (12), 757-64.
- Ingram-Rice, B. (1997). CTS: more than a wrist problem. *Journal of Bodywork and Movement Therapies*, 1 (3), 155-162.
- Jones, J. R. Huxtable, C. S. Hodgson, J. T. (2005). Self-reported work-related illness in 2003/2004: Results from the *Labour Force Survey*. Sudbury, Suffolk. Crown Publications.

- Jones, L. Lott, M. Calder, C. Kutt, E. (2004). Imprint cytology from ultrasound-guided core biopsies: accurate and immediate diagnosis in a one-stop breast clinic. *Clinical Radiology*. 59 (10): 903-908.
- Jonsson, B. (1988). The static load component in muscle work. *European Journal of Applied Physiology and Occupational Physiology*, 57 (3).
- Kamakura, N. Matsuo, M. Ishii, H. Mitsuboshi, F. Miura, Y. (1980). Patterns of static prehension in normal hands. *American Journal of Occupational Therapy*, (34), 437-448.
- Kaminsky, S.B. Baker, C.L. (2003). Lateral epicondylitis of the elbow. *Techniques in Hand & Upper Extremity Surgery*, 7 (4), 179–89.
- Kannus, P. (1997). Etiology and pathophysiology of chronic tendon disorders in sports. *Scandinavian Journal of Medicine and Science in Sports*. 7: 78–85.
- Khan, K.M. Cook, J.L. Bonar, F. Harcourt, P.A.M. (1999). Histopathology of common tendinopathies. Update and implications for clinical management. *Sports Medicine*. 27: 393–408.
- Kotevoglou, N. Gulbahce-Saglam, S. (2004). Ultrasound imaging in the diagnosis of carpal tunnel syndrome and its relevance to clinical evaluation. *Joint Bone Spin*, 72(2), 142-145.

Kroemer, K. (1986). Coupling the hand with the handle. *Human Factors*, 28, 337-339.

Kroemer, K. Kroemer, H. Kroemer, K. (1997). *Engineering physiology: basis of human factors and ergonomics* (3rd Ed.). New York. Van Nostrand Reinhold.

Kumar, S. (1999). *Biomechanics in ergonomics*. London & Philadelphia: Taylor & Francis Ltd.

Landsmeer, J. (1962). Power grip and precision handling. *Annals of Rheumatic Diseases*, 21, 164-170.

Latinovic, R. Gulliford, M. Hughes, R. (2006). Incidence of common compressive neuropathies in primary care. *Journal of Neurology, Neurosurgery, Psychiatry*, 77 (2), 263-265.

Leonard, L. Rangan, A. Doyle, G. Taylor, G. (2003). Carpal tunnel syndrome- is high frequency ultrasound a useful diagnostic tool? *Journal of Hand Surgery*, 1, 77-79.

Long, C. Conrad, P. Hall, E. Furler, S. (1970). Intrinsic-extrinsic muscle control of the hand in power grip and precision handling. *Journal of Bone and Joint Surgery*, 52a (5), 853-867.

Lundborg, G. Myers, R. Powell, H. (1983). Nerve compression injury and increased endoneurial fluid pressure: a miniature compartment syndrome. *Journal Neurological Neurosurgery and Psychiatry*. 46:1119– 1124.

- Malchaire, J.B. Cock, N.A. Piette, A. Dutra Leao, R. Lara, M. Amaral, F. (1997). Relationship between work constraints and the development of musculoskeletal disorders of the wrist: a prospective study. *International Journal of Industrial Ergonomics* (19), 471-482.
- Marieb, E. (1995). *Human anatomy and Physiology* (3rd ed.). Redwood City, USA: Benjamin/Cummings.
- Michailidis, G.D. Papageorgiou, P. Economides, D.L. (2002). Assessment of fetal anatomy in the first trimester using two- and three-dimensional ultrasound. *The British Journal of Radiology*. 75 (891): 215–219.
- Millesi, H. Zoch, G. Reihnsner, R. (1995). Mechanical properties of peripheral nerves. *Clinical Orthopaedics and Related Research*. 314 :76– 83.
- Morris, H.H. Peters, B.H. (1976). Pronator syndrome: clinical and electrophysiological features in seven cases. *J Neurol Neurosurg Psychiatry*, 39, 461-464.
- Nakamichi, K. Tachibana, S. (1998). Distance between the median nerve and ulnar neurovascular bundle: clinical significance with ultrasonographical assisted carpal tunnel release. *J Hand Surg*, 23, 870-874.

Nakamichi, K. Tachibana, S. (2002). Ultrasonographic measurement of median nerve cross-sectional area in idiopathic carpal tunnel syndrome: diagnostic accuracy. *J Hand Surg*, 26, 788-803.

Napier, J. (1956). The prehensile movements of the hand. *Journal of Bone and Joint Surgery*, 38B, 902-913.

Nikias, C.L. Raghuvver, M.R. (1987). Bispectrum estimation: A digital signal processing framework. *IEEE Proceedings on Communications and Radar*. 75, (7) 869–891).

NIOSH. (1997). *Musculoskeletal disorders and workplace factors: a critical review of epidemiologic evidence for work-related musculoskeletal disorders of the neck, upper extremity and back*. Cincinnati: NIOSH Publication.

Nirschl, R.P. Pettrone, F.A. (1979). Tennis elbow. The surgical treatment of lateral epicondylitis. *Journal of Bone and Joint Surgery*. 61 (6A):832-9.

Nordin, M. Frankel, V.F. (2001). *Basic biomechanics of the musculoskeletal system* (Vol. 3rd edition). Philadelphia & Baltimore: Lippincott Williams &Wilkins.

Omer, G.E. Spinner, M. Van Beek, A.L. (1998). *Management of peripheral nerve problems*. Philadelphia: W. B. Saunders Company.

- Pal, B. (1997). Carpal tunnel syndrome as a herald of autoimmune rheumatic disorders. *Journal of the Royal Society of Medicine*, 90, 216-217.
- Peric, R.O. Schuurbiers, C. J. Veselić, M. Rabe, K. F. van der Heijden, H. F. M. Annema, J. T. (2010). Transesophageal endoscopic ultrasound-guided fine-needle aspiration for the mediastinal Staging of extrathoracic Tumors: A New Perspective. *Annals of Oncology*. 21(7):1468-1471.
- Pheasant, S. Haslegrave, C.M. (2006). *Bodyspace: anthropometry, ergonomics and the design of work* (3rd ed.). London & New York. CRC Press.
- Polito, A. Ricci, Z. Di Chiara, L. Giorni, C. Iacoella, C. Sanders, S. P. Picardo. S. (2006). Cerebral blood flow during cardiopulmonary bypass in pediatric cardiac surgery: the role of transcranial Doppler – a systematic review of the literature. *Cardiovascular Ultrasound*. 4:47.
- Powell, H. Myers, R. (1986). Pathology of experimental nerve compression. *Laboratory Investigation*. 55: 91– 100.
- Powers, C.M. Shellock, F.G. Pfaff, M. (1998). Quantification of patellar tracking using kinematic MRI. *Journal of Magnetic Resonance Imaging*. 8:724–732.
- Punnett, L. Wegman, D.H. (2004). Work-related musculoskeletal disorders: the epidemiologic evidence and the debate. *Journal of Electromyography and Kinesiology* (14), 13-23.

Puxkandl, R. Zizak, I. Paris, O. Keckes, J. Tesch, W. Bernstorff, S. Purslow, P. Fratzl, P. 2002. Viscoelastic properties of collagen: synchrotron radiation investigations and structural model. *Philosophical Transactions of the Royal Society of London Series B-Biological Sciences*. 357 (1418): 191–197.

Rago, T. Chiovato, L. Grasso, L. Pinchera, A. Vitti, P. (2001). Thyroid ultrasonography as a tool for detecting thyroid autoimmune diseases and predicting thyroid dysfunction in apparently healthy subjects. *Journal of Endocrinological Investigation*. 24 (10): 763-9.

Rebmann, A.J. Sheehan, F.T. (2003). Precise 3D skeletal kinematics using fast phase contrast magnetic resonance imaging. *Journal of Magnetic Resonance Imaging*. 17:206–213.

Rempel, D. Dahlin, L. Lundborg, G. (1999). *Biological response of peripheral nerves to loading pathophysiology of nerve compression syndromes and vibration induced neuropathy*. Cambridge: Cambridge University Press.

Rempel, D. Diao, E. (2004). Entrapment neuropathies: pathophysiology and pathogenesis. *Journal of Electromyography and Kinesiology*. 14: 71– 75.

Rojviroj, S. Sirichativapee, W. Kowsuwon, W. (1990). Pressure in the carpal tunnel: a comparison between patients with carpal tunnel syndrome and normal subjects. *Journal of Bone and Joint Surgery*. 72: 516– 518.

Rydevik, B. Kwan, M. Myers, R. (1990). An in vitro mechanical and histological study of acute stretching on rabbit tibial nerve. *Journal of Orthopaedic Research*. 8 :694– 701.

Rydevik, L. Lundborg, G. Bagge, U. (1981). Effects of graded compression on intraneural blood flow: an in vivo study on rabbit tibial nerve. *Journal of Hand Surgery*. 6: 3– 12.

Sanders, R.J. Hammond, S.L. Rao, N.M. (2007). Diagnosis of thoracic outlet syndrome. *J Vasc Surg*, 46 (3), 601-4.

Scheri, S.A. Templeton, K. (2003). Disorders. In: Bernstein, J. *Musculoskeletal Medicine*. Rosemont IL: American Academy of Orthopaedic Surgeons Editorial Board. 103-286.

Schwartz, S.I. *Principles of Surgery*. 7th ed. (1999). McGraw-Hill. New York. 2048-53.

Schwemmer, U. Markus, C.K. Greim, C.A. Brederlau, J. Kredel, M. Roewer, N. (2005). Sonographic imaging of the sciatic nerve division in the popliteal fossa. *Ultraschall Med*, 26 (6), 496-500.

Seddon, H. J. (1943). Three types of nerve injury. *Brain*. 66: 237-288.

Sharma, P. M. N. (2006). Biology of tendon injury: healing, modeling and remodeling. *Journal of Musculoskeletal and Neuronal Interactions*. 6 (2): 181–190.

- Sheehan, F.T. Zajac, F.E. Drace, J.E. (1998). Using cine phase contrast magnetic resonance imaging to non-invasively study in vivo knee dynamics. *Journal of Biomechanics*. 31:21–26.
- Sheehan, F.T. Zajac, F.E. Drace, J.E. (1999). In vivo tracking of the human patella using cine phase contrast magnetic resonance imaging. *Journal of Biomechanics*. 121:650–656.
- Shellock, F.G. Mink, J.H. Deutsch, A.L. Foo, T.K. Sullenberger, P. (1993). Patellofemoral joint: identification of abnormalities with active-movement, "unloaded" versus "loaded" kinematic MR imaging techniques. *Radiology*. 188:575–578.
- Silver, F. H. Freeman, J. W. Seehra, G. P. (2003). Collagen self-assembly and the development of tendon mechanical properties. *Journal of Biomechanics*. 36 (10): 1529–1553.
- Smith, R. (1985). Pinch and grasp strength: standardization of terminology and protocol. *The American Journal of Occupational Therapy*, 39 (8), 531-535.
- Stevens, J.C. Beard, C.M. O'Fallon, W.M. Kurland, L.T. (1992). Conditions associated with carpal tunnel syndrome. *Mayo Clinical Proceedings*, 67 (6), 541–548.
- Suetens, P. (2002). *Fundamentals of Medical Imaging*. Cambridge: Cambridge University Press.

Tanaka, S. McGlothlin, J. (1993). A conceptual quantitative model for prevention of work related carpal tunnel syndrome. *International Journal of Industrial Ergonomics*, 11, 181-193.

Tay, S.C. Primak, A.N. Fletcher, J.G. Schmidt, B. An, K.N. McCollough, C.H. (2008). Understanding the relationship between image quality and motion velocity in gated computed tomography: preliminary work for 4-dimensional musculoskeletal imaging. *Journal Computer Assisted Tomography*. 32 (4): 634-9.

Thoirs, K. Williams, M.A. Phillips, M. (2007). Ultrasonographic measurements of the ulnar nerve at the elbow. *J Ultrasound Med*, 27, 737-743.

Thomas, P. (1963). The connective tissue of peripheral nerve: an electron microscope study. *Journal of Anatomy*. 97: 35– 44.

Tortora, G.J. Grabowski, S.R. (2003). *Principles of anatomy and physiology* (10th ed.). New York. John Wiley & Sons.

Topp, K. S. Boyd B. S. (2006). Structure and Biomechanics of Peripheral Nerves: Nerve Responses to Physical Stresses and Implications for Physical Therapist Practice. *Physical Therapy*. 86 (1): 92-109.

Treastera, D.E. Burra, D. (2004). Gender differences in prevalence of upper extremity musculoskeletal disorders. *Ergonomics*, 47(5), 495 – 526.

Viikari-Juntura, E. Silverstein, B.A. (1999). Role of physical load factors in carpal tunnel syndrome. *Scandinavian Journal of Work and Environmental Health* (25), 163-185.

Walker, F. O. Weisler, E. Caress, J. (2004). Ultrasound of nerve and muscle. *Clinical Neurophysiology*, 115, 495-507.

Wells, R. (2004). Elbow, Forearm and Wrist. In: Delleman, N.J. Haslegrave, C.M. Chaffin, D.B. *Working postures and movements. Tools for evaluation and engineering*. London: CRC Press. 297-310.

Werner, R.A. Albers, J.W. Franzblau, A. Armstrong, T.J. (2004). The relationship between body mass index and the diagnosis of carpal tunnel syndrome. *Muscle and Nerve*, 17, (6), 632 – 63.

Wong, S.M. Hui, A. Lo, S.K. Fu, M. Wong, K.S. (2004). Carpal tunnel syndrome: Diagnostic usefulness of sonography. *Radiology*, 232, 93-99.

World Health Organization, (1985). Identification and Control of Work-Related Diseases. WHO, 174.

Yassi, A. (1997). Repetitive strain injuries. *Lancet*, 943-947.

Yesildag, A. Kutluhan, S. Sengul, N. Koyuncuoglu, H. Oyar, O. Guler, K. Gulsoy, U. (2004). The role of ultrasonographic measurements of the median nerve in the diagnosis of carpal tunnel syndrome. *Clinical Radiology* , 59, 910-915.

Yoon, J.S. Walker, F.O. Cartwright, M.S. (2004) Ultrasonographic swelling ratio in the diagnosis of ulnar neuropathy at the elbow. *Muscle Nerve*, 38, 1231-1235.

Zhang, H.M. Zhou, L.J. Hu, X.D. Hu, N.W. Zhang, T. Liu, X.G. (2004). Acute nerve injury induces long-term potentiation of C-fiber evoked field potentials in spinal dorsal horn of intact rat. *Sheng Li Xue Bao*. 25 (5):591-6.

Ziskin, M.C. (1991). Basic Physics of Ultrasound. In: Fleischer, A.C, Romero, R, Manning, F.A, *The Principles and Practice of Ultrasonography in Obstetrics and Gynaecology*. (4th Ed). Norwalk, CT: Appleton & Lange. 567–572.

Web Sites

www.aurorahealthcare.org/healthgate/images/si55550704.jpg. Last viewed 05/04/10.

www.claralieu.files.wordpress.com/2008/01/tenosynovitis.jpg. Last viewed 05/04/10.

www.ebme.co.uk/arts/nerve/nerve2.gif.

www.eegemg218.com/images/emg. Last viewed 04/05/10.

www.emedicine.medscape.com/article/388525-overview Last viewed 23/10/10)

www.eorthopod.com/content/quadrilateral-space. Last viewed 04/05/10.

www.health.com: last viewed 04/05/10.

www.maxcdn.fooyoh.com/files/attach/images.jpg. Last viewed 05/04/10.

www.mdconsult.com/das/journal/view/0/N/204559. Last viewed 04/05/10.

www.media.summitmedicalgroup.com/media/db/relayhealth-images/thoracic.jpg.

Last viewed 05/04/10.

www.nlm.nih.gov/medlineplus/ency/images/ency/fullsize/1081.jpg. Last viewed 04/05/10.

www.osha.europa.eu/en/publications. Last viewed 25/02/10.

www.otsmed.com/images/tennis_elbow.jpg. Last viewed 05/04/10.

www.rsna.org/Media/rsna/RSNA08_newsrelease_target.cfm. Last viewed 04/05/10.

www.2.siba.fi/harjoittelu/index. Last viewed 15/06/10.

www.vanat.cvm.umn.edu. Last imaged 01-10-10.

www.wellsphere.com/wellpage/carpal-tunnel-syndrome. Last viewed 04/05/10.

